

## Review Article

*Medical Progress*

## BRONCHIECTASIS

ALAN F. BARKER, M.D.

This affection of the bronchia is always produced by chronic catarrh, or by some other disease attended by long, violent, and often repeated fits of coughing.

R.T.H. Laënnec<sup>1</sup>

**B**RONCHIECTASIS is an uncommon disease with the potential to cause devastating illness, including repeated respiratory infections requiring antibiotics, disabling productive cough, shortness of breath, and occasional hemoptysis. Landmarks in the history of bronchiectasis include the vivid descriptions of patients with suppurative phlegm that appeared in the writings of René Théophile Hyacinthe Laënnec in the early 19th century; the 1922 introduction by Jean Athanase Sicard of contrast bronchography, which permitted the precise imaging of the destructive changes in the airway; the defining studies by Lynne Reid in the 1950s linking bronchography with pathological specimens; and the subsequent decline in prevalence that is probably attributable to effective antituberculous therapy and immunization against pertussis and measles. In this article, I discuss recent developments, including the compounding roles of infections, amplified inflammatory responses, and defects in host defense; the replacement of bronchography by high-resolution computed tomography (CT) as a definitive imaging tool; and the similarities and differences between bronchiectasis and cystic fibrosis in terms of clinical features and management strategies.

Thanks to the work of Reid, the definition of the disease has remained morphologic for 50 years: bronchiectasis is the permanent dilatation of bronchi.<sup>2</sup> It can be categorized according to the pathological or radiographic appearance of airways. Cylindrical or tubular bronchiectasis is characterized by

dilated airways alone and is sometimes seen as a residual effect of pneumonia; varicose bronchiectasis (so named because its appearance is similar to that of varicose veins) is characterized by focal constrictive areas along the dilated airways that result from defects in the bronchial wall; and saccular or cystic bronchiectasis is characterized by progressive dilatation of the airways, which end in large cysts, saccules, or grape-like clusters (this finding is always indicative of the most severe form of bronchiectasis).<sup>2</sup>

The prevalence of bronchiectasis in the United States and worldwide is unknown. There are reports of high prevalence in relatively isolated populations with poor access to health care and high rates of respiratory tract infections during childhood, such as Alaskan Natives in the Yukon–Kuskokwim Delta.<sup>3</sup>

## PATHOPHYSIOLOGY

Bronchiectasis is primarily a disease of the bronchi and bronchioles involving a vicious circle of transmural infection and inflammation with mediator release.<sup>4</sup> Illness is related to retained inflammatory secretions and microbes that cause obstruction and damage of the airway and recurrent infection. Although there are no studies of patients in the very early stages of bronchiectasis, findings in patients with proven bronchiectasis give credence to the importance of enhanced cellular and mediator responses: bronchial mucosal biopsies reveal infiltration by neutrophils and T lymphocytes<sup>5</sup>; expectorated sputum has increased concentrations of elastase<sup>6</sup> and the chemoattractants interleukin-8,<sup>7</sup> tumor necrosis factor  $\alpha$  (TNF- $\alpha$ ),<sup>8</sup> and prostanoids.<sup>9</sup>

## FOCAL AND DIFFUSE PRESENTATIONS

Bronchiectasis can present in either of two forms — a local or focal obstructive process of a lobe or segment of a lung or a diffuse process involving much of both lungs and often accompanied by other sinopulmonary diseases, such as sinusitis and asthma. Three types of focal airway obstruction may lead to bronchiectasis. One type is luminal blockage by a foreign body,<sup>10</sup> broncholith, or slowly growing tumor that is usually benign. A second type of obstruction is extrinsic narrowing due to enlarged lymph nodes. The best example is the middle lobe syndrome, which involves a small angulated orifice surrounded by a collar of lymph nodes that may enlarge and encroach on the main airway after infection with granulomatous diseases due to mycobacteria or fungi.<sup>11</sup> A third type of obstruction is twisting or displacement of

From the Pulmonary and Critical Care Division, Department of Medicine, Oregon Health and Science University, Portland. Address reprint requests to Dr. Barker at the Pulmonary and Critical Care Division, Department of Medicine, Oregon Health and Science University, Portland, OR 97201, or at barkera@ohsu.edu.

the airways after a lobar resection (for example, the occasional cephalad displacement of a lower lobe after surgery for the resection of the upper lobe). Recurrent or persistent lobar pneumonia is a key distinguishing feature of the first two types of focal bronchiectasis and is important to recognize, since interventional bronchoscopy<sup>12</sup> or surgery may offer palliation and sometimes cure.

Most reports of diffuse bronchiectasis and associated systemic conditions are case reports and have been previously reviewed.<sup>13</sup> Some of the potential defects or insults that allow bronchiectasis to develop are summarized in Table 1. Recognition of the causes discussed below may lead to a specific management strategy or a better understanding of the disease process and prognosis.

## CAUSES

### Infections

Effective childhood immunization strategies have led to a marked reduction in the incidence of bronchiectasis caused by pertussis or whooping cough. Other childhood respiratory tract infections may contribute to permanent airway damage.<sup>14</sup> The presence of *Staphylococcus aureus* is associated with cystic fibrosis or allergic bronchopulmonary aspergillosis.<sup>15,16</sup>

Primary *Mycobacterium avium* complex infection has been recognized particularly in white women over 60 years of age. Chronic, unrelenting cough and middle-lobe involvement are clues to this diagnosis.<sup>17,18</sup> With increasing recognition of this syndrome, a genetic basis has been investigated. In four children with disseminated atypical mycobacterial infection, a mutation in the gene for interferon- $\gamma$  receptor 1 has been identified that produces a defect in the up-regulation of TNF- $\alpha$  by macrophages.<sup>19</sup> This abnormality was not found in a population of elderly women with *M. avium* complex infection, but the possibility remains that such patients have a defect in the processing of intracellular pathogens such as *M. avium* complex.<sup>20</sup>

*Aspergillus fumigatus* is often a commensal organism. Allergic bronchopulmonary aspergillosis is a condition affecting patients with asthma and involving airway damage caused by multiple factors. Bronchiectasis in patients with allergic bronchopulmonary aspergillosis is due to an immune reaction to aspergillus, the actions of mycotoxins, elastase, and interleukin-4 and interleukin-5, and in later stages, the direct invasion of the airways by the fungus.<sup>21,22</sup> A recent report demonstrating improvement in pulmonary function and reduced use of corticosteroids after itraconazole therapy suggests that the aspergillus organism may also have an infectious role.<sup>23</sup>

It is not surprising that bronchiectasis has been described in patients with the acquired immunode-

**TABLE 1.** CONDITIONS ASSOCIATED WITH BRONCHIECTASIS.

|   |
|---|
| Postinfectious conditions   |
| Bacteria (pseudomonas, haemophilus)   |
| Mycobacterium tuberculosis  |
| Aspergillus species   |
| Virus (adenovirus, measles virus, influenza virus, human immunodeficiency virus)                          |
| Congenital conditions   |
| Primary ciliary dyskinesia  |
| Alpha <sub>1</sub> -antitrypsin deficiency  |
| Cystic fibrosis   |
| Tracheobronchomegaly (Mounier-Kuhn syndrome)  |
| Cartilage deficiency (Williams-Campbell syndrome)   |
| Pulmonary sequestration   |
| Marfan's syndrome   |
| Immunodeficiency  |
| Primary   |
| Hypogammaglobulinemia   |
| Secondary   |
| Caused by cancer (chronic lymphatic leukemia), chemotherapy, or immune modulation (after transplantation) |
| Sequelae of toxic inhalation or aspiration  |
| Chlorine  |
| Overdose (heroin)   |
| Foreign body  |
| Rheumatic conditions  |
| Rheumatoid arthritis  |
| Systemic lupus erythematosus  |
| Sjögren's syndrome  |
| Relapsing polychondritis  |
| Other   |
| Inflammatory bowel disease (chronic ulcerative colitis or Crohn's disease)                                |
| Young's syndrome (secondary ciliary dyskinesia)   |
| Yellow nail syndrome (yellow nails and lymphedema)  |

ciency syndrome, given their repeated respiratory tract infections and impaired host response. Most of these patients have low CD4 cell counts; previous pyogenic, pneumocystic, and mycobacterial infections; and (if they are children) lymphocytic interstitial pneumonia.<sup>24-26</sup>

### Primary Ciliary Dyskinesia

Primary ciliary dyskinesia is a prototypical example of a condition in which poorly functioning cilia contribute to the retaining of secretions and recurrent infections that, in turn, lead to bronchiectasis. Primary ciliary dyskinesia is inherited as an autosomal recessive syndrome with variable penetrance. The estimated frequency at birth is 1 in 15,000 to 1 in 40,000. The chief ciliary defect in patients with this syndrome is an absence or shortening of the dynein arms that are responsible for the coordinated bending of the axon. Approximately half of patients with primary ciliary dyskinesia have Kartagener's syndrome (bronchiectasis, sinusitis, and situs inversus or partial lateralizing abnormality).<sup>27,28</sup> Ciliary motility is direct-

ed by a peptide whose gene expression was recently identified.<sup>29</sup> With a candidate-gene approach (comparison with a unicellular alga with flagella that are similar to human cilia), mutations in the sequence of DNA encoding a dynein axon have been identified as unique to patients with primary ciliary dyskinesia.<sup>30</sup> Mapping of homozygosity in a consanguineous family with primary ciliary dyskinesia resulted in the identification of chromosome 5p15–p14 as a locus for a gene of interest in this region, DNA H5, that codes for the heavy chain in a dynein arm.<sup>31</sup>

#### Immunodeficiency

Persons with humoral immunodeficiency syndromes involving deficiencies of IgG, IgM, and IgA are at risk for recurrent suppurative sinopulmonary infections and bronchiectasis.<sup>32</sup> Immune globulin replacement reduces the frequency of infectious episodes and prevents further destruction of the airways.<sup>33,34</sup> In rare cases, recurrent respiratory infections and airway damage develop in patients with selective deficiencies of IgA or IgM. The role of IgG subclass deficiency in patients with near-normal levels of total IgG is controversial, because testing is not standardized, the normal ranges are variable, and levels are lower in toddlers and increase with age.<sup>35,36</sup> Before immune globulin replacement is considered for patients with IgG subclass deficiency, immunization with a provocative B-cell antigen such as the *Haemophilus influenzae* vaccine<sup>37</sup> or pneumococcal vaccine should reveal a reduced antibody response, suggesting that the subclass deficiency has a role.<sup>38,39</sup>

#### Cystic Fibrosis

The onset in adulthood of repeated respiratory tract infections in the absence of exocrine pancreatic insufficiency is recognized as a presentation of cystic fibrosis.<sup>40</sup> Upper-lobe infiltration apparent on imaging of the chest and the growth of *S. aureus* or mucoid *Pseudomonas aeruginosa* on sputum culture are clues that cystic fibrosis may be the underlying cause of illness. Elevated sodium and chloride concentrations on sweat chloride testing are diagnostic. Mutation of the cystic fibrosis transmembrane conductance regulator, as found in classic cystic fibrosis ( $\Delta F508$ ), is most common, but many other mutations have also been identified near this locus.<sup>41</sup>

#### Rheumatoid Arthritis

Bronchiectasis associated with rheumatoid arthritis has been described as preceding the arthritis as well as occurring during the course of the disease. At clinics specializing in rheumatoid arthritis, the clinical manifestations of bronchiectasis occur in 1 to 3 percent of patients.<sup>42,43</sup> The use of high-resolution CT may reveal a prevalence of bronchiectasis as high

as 30 percent.<sup>44,45</sup> During a five-year follow-up period, patients with bronchiectasis and rheumatoid arthritis were five times as likely to die as patients with rheumatoid arthritis alone. Most deaths were due to respiratory complications.<sup>46</sup>

#### Inflammatory Bowel Disease

Repeated respiratory tract infections and bronchiectasis have been noted in patients with inflammatory bowel disease, most often in those with chronic ulcerative colitis.<sup>47-49</sup> Postulated links include the infiltration of the airway by immune effector cells such as lymphocytes,<sup>50</sup> enhanced autoimmune activity as part of the underlying disease, and complications of immune-modulating therapies. Bowel resection does not palliate the respiratory symptoms and may even aggravate the bronchiectasis. Bronchodilators and inhaled corticosteroid medications may reduce symptoms.<sup>47</sup>

#### SYMPTOMS AND PHYSICAL FINDINGS

Virtually all patients with bronchiectasis have cough and chronic sputum production. The sputum is variously described as mucoid, mucopurulent, thick, tenacious, or viscous (viscid). Blood-streaked sputum or copious hemoptysis may also result from erosive airway damage caused by an acute infection. Dyspnea and wheezing occur in 75 percent of patients. Pleuritic chest pain occurs in 50 percent of patients and reflects the presence of distended peripheral airways or distal pneumonitis adjacent to a visceral pleural surface. Adventitious breath sounds on physical examination of the chest, including crackles (in 70 percent of patients), wheezing (in 34 percent), and rhonchi (in 44 percent), are clues to the diagnosis. In the past, digital clubbing was a frequent feature, but a more recent series describes a prevalence of only 3 percent.<sup>51</sup> The major confounding disease is chronic obstructive pulmonary disease (COPD). A comparison of the features of the two conditions is presented in Table 2.

#### DIAGNOSTIC TESTING

Diagnostic guidelines are outlined in Table 3. Because of its importance in the diagnosis of bronchiectasis, I discuss chest imaging in detail. Ninety percent of chest radiographs are abnormal in patients with chronic cough, phlegm, and shortness of breath who have bronchiectasis. The findings may be non-specific in that they may include focal pneumonitis, scattered irregular opacities, linear or plate-like atelectasis, or specifically dilated and thickened airways that appear as ring-like shadows (of airways that are seen on end) or tram lines (in the case of airways that are perpendicular to the x-ray beam).<sup>51</sup>

High-resolution CT has become the best tool for diagnosing bronchiectasis, clarifying the findings from

**TABLE 2.** COMPARISON OF BRONCHIECTASIS AND CHRONIC OBSTRUCTIVE PULMONARY DISEASE.

| VARIABLE                                     | CHRONIC OBSTRUCTIVE PULMONARY DISEASE                              | BRONCHIECTASIS                                       |
|--|--|--|
| Cause  | Cigarette smoking  | Infection or genetic or immune defect                |
| Role of infection                            | Secondary  | Primary  |
| Predominant organism in sputum               | <i>Streptococcus pneumoniae</i> ,<br><i>Haemophilus influenzae</i> | <i>H. influenzae</i> , <i>Pseudomonas aeruginosa</i> |
| Airflow obstruction and hyper-responsiveness | Present  | Present  |
| Findings on chest imaging                    | Hyperlucency, hyperinflation, airway dilatation                    | Airway dilatation and thickening, mucous plugs       |
| Quality of sputum (in the steady state)      | Mucoid, clear  | Purulent, three-layered                              |

**TABLE 3.** DIAGNOSTIC TESTING FOR BRONCHIECTASIS.\*

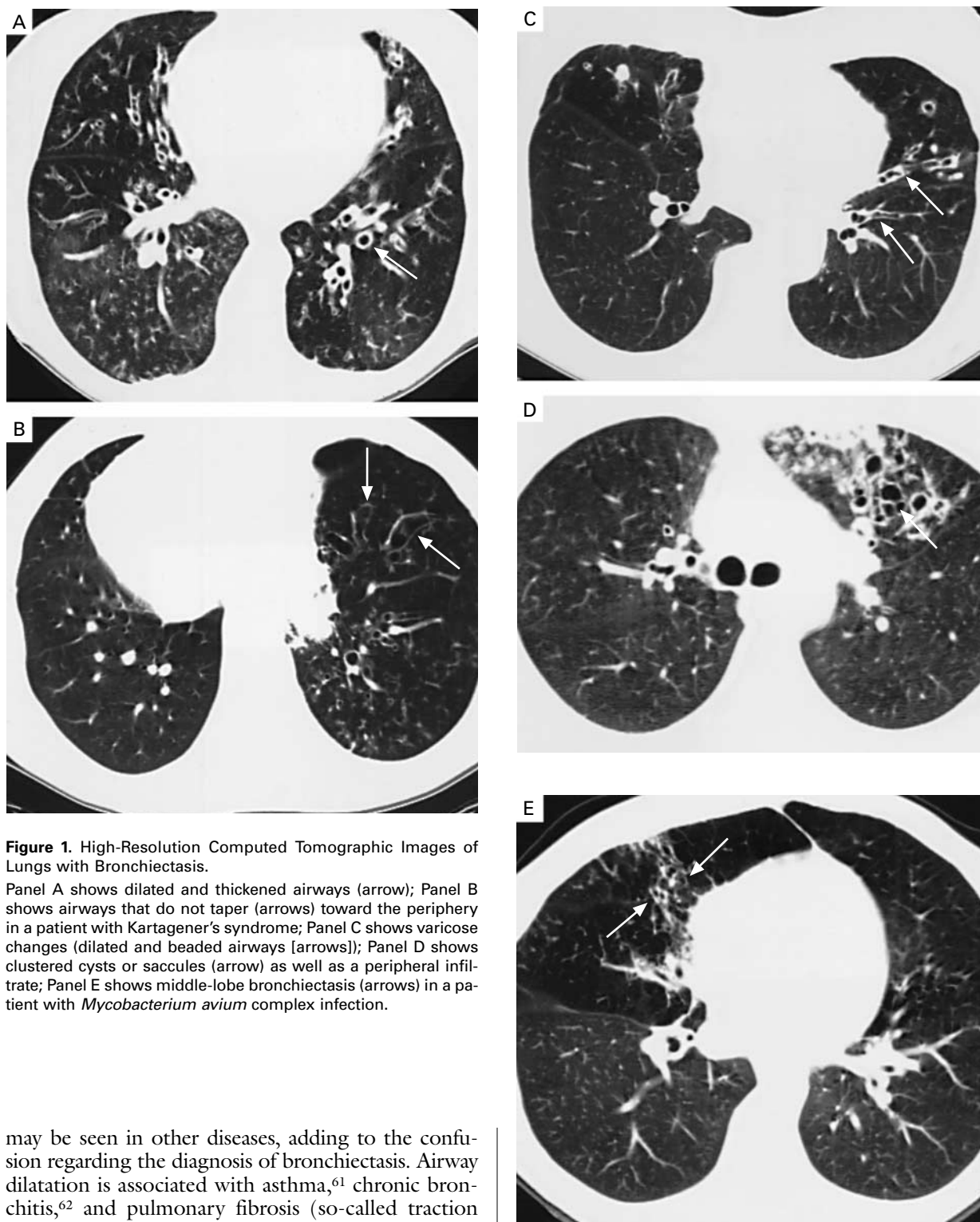
| LEVEL OF TESTING | APPROPRIATE TESTS   |                    |  |
|------------------|---|--------------------|--|
|                  | BLOOD   | IMAGING            | OTHER  |
| Primary          | Complete and differential blood count, IgG, IgA, IgM  | High-resolution CT | Spirometry or bronchodilator test  |
| Secondary        | Rheumatoid factor; IgE, aspergillus precipitins (ABPA); IgG subclasses; alpha <sub>1</sub> -antitrypsin level | Sinus CT           | Sputum bacterial, mycobacterial, fungal culture and sensitivity; bronchoscopy with mucosal biopsy, cultures (for focal obstruction, infection, primary ciliary dyskinesia); sweat chloride test analysis (for cystic fibrosis) |

\*The causes for suspicion of bronchiectasis are chronic cough, daily production of mucopurulent sputum, and persistent focal infiltrate on radiography. CT denotes computed tomography, and ABPA allergic bronchopulmonary aspergillosis.

chest radiography, and mapping airway abnormalities that cannot be seen on plain films of the chest.<sup>52</sup> The appropriate high-resolution CT study is a non-contrast study with the use of 1.0-to-1.5-mm window every 1 cm with acquisition times of one second, reconstructed with the use of a high-spatial-frequency algorithm during full inspiration.<sup>53</sup> Spiral CT may elucidate additional subtle changes, because it reduces motion artifact, but it requires a larger dose of radiation.<sup>54</sup> Specific abnormalities found on high-resolution CT include dilatation of an airway lumen (Fig. 1A), rendering it more than 1.5 times as wide as a nearby vessel<sup>55</sup>; lack of tapering of an airway toward the periphery (Fig. 1B)<sup>56,57</sup>; varicose constrictions along airways (Fig. 1C); and ballooned cysts at the

end of a bronchus (Fig. 1D). The bullae found in patients with emphysema have thinner walls and are away from an airway. Nonspecific findings include consolidation or infiltration of a lobe with dilatation of the airways, thickening of the bronchial walls, mucous plugs, enlarged lymph nodes,<sup>58</sup> and a reduction in vascular markings similar to that seen in emphysema, probably as a result of the inflammatory destruction of smaller airways and vessels.<sup>59</sup>

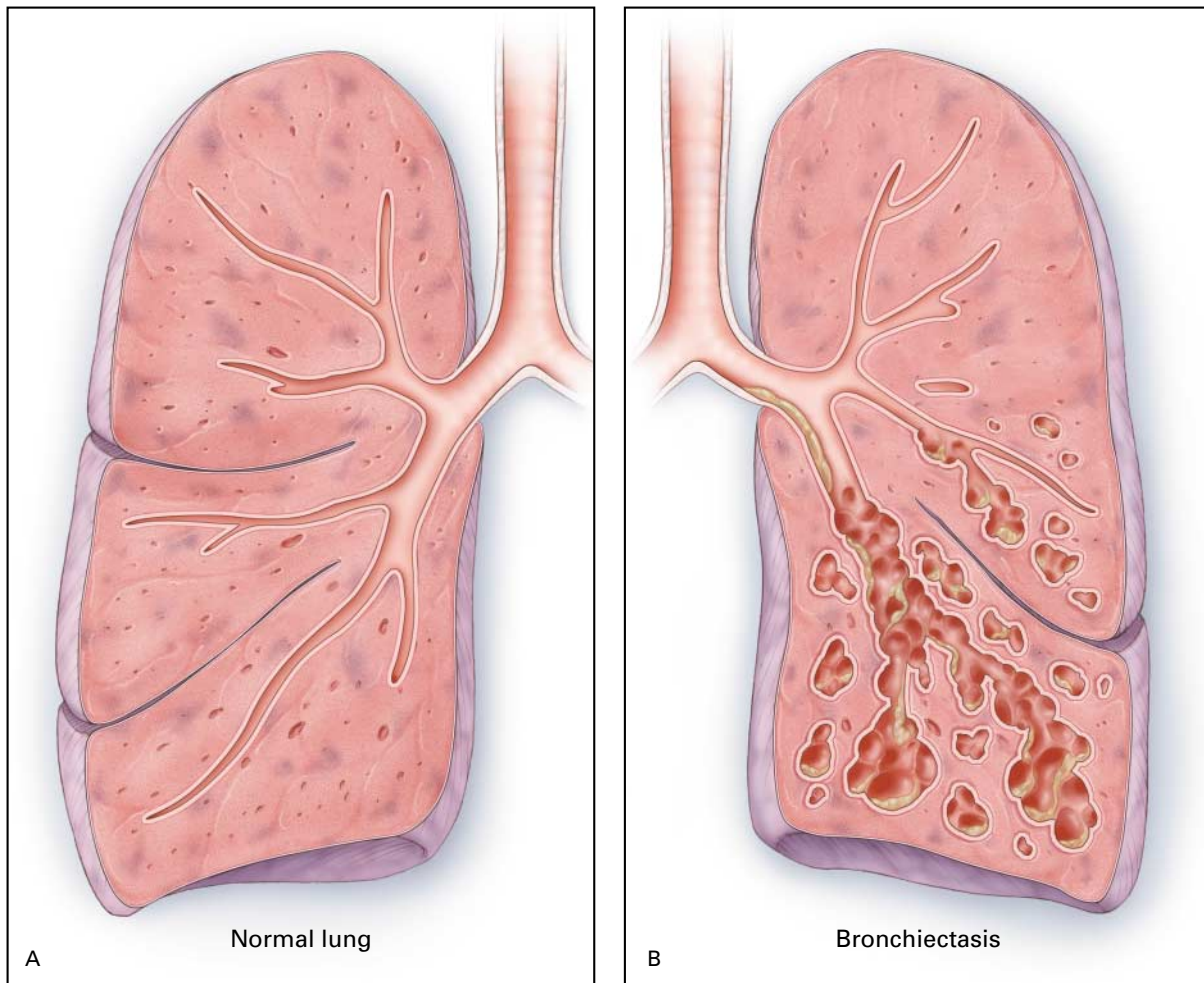
Cystic fibrosis and allergic bronchopulmonary aspergillosis involve an upper-lobe distribution, and *M. avium* complex infection (Fig. 1E) often involves the middle lobe or lingula.<sup>60</sup> Bronchiectasis, by contrast, most commonly affects the lower lobe (Fig. 2). With the use of high-resolution CT, dilated airways



**Figure 1.** High-Resolution Computed Tomographic Images of Lungs with Bronchiectasis.

Panel A shows dilated and thickened airways (arrow); Panel B shows airways that do not taper (arrows) toward the periphery in a patient with Kartagener's syndrome; Panel C shows varicose changes (dilated and beaded airways [arrows]); Panel D shows clustered cysts or saccules (arrow) as well as a peripheral infiltrate; Panel E shows middle-lobe bronchiectasis (arrows) in a patient with *Mycobacterium avium* complex infection.

may be seen in other diseases, adding to the confusion regarding the diagnosis of bronchiectasis. Airway dilatation is associated with asthma,<sup>61</sup> chronic bronchitis,<sup>62</sup> and pulmonary fibrosis (so-called traction bronchiectasis).<sup>63</sup> There is emerging evidence that the number of abnormal airways found on high-resolution CT is correlated with the degree of impairment of pulmonary function.<sup>57,64,65</sup>



**Figure 2.** Normal Lung and Airways (Panel A) and the Lung of a Patient with Bronchiectasis (Panel B). In Panel B, bronchiectasis is primarily in the lower lobe, which is the most common distribution. The saccular dilatations and grape-like clusters with pools of mucus are signs of severe bronchiectasis.

### PULMONARY FUNCTION

Spirometry often shows a limitation of airflow, with a reduced ratio of forced expiratory volume in one second ( $FEV_1$ ) to forced vital capacity (FVC), a normal or slightly reduced FVC, and a reduced  $FEV_1$ . A reduced FVC may indicate that airways are blocked by mucus, that they collapse with forced exhalation, or that there is pneumonitis in the lung. Cigarette smoking may worsen pulmonary function and accelerate the obstructive impairment.<sup>51</sup> Airway hyperresponsiveness can be demonstrated, since 40 percent of patients have 15 percent or greater improvement in  $FEV_1$  after the administration of a beta-adrenergic

agonist,<sup>66</sup> and 30 to 69 percent of patients who do not already have a markedly reduced  $FEV_1$  have a 20 percent decrease in  $FEV_1$  after histamine or methacholine challenge.<sup>67,68</sup>

### MANAGEMENT

The foundations of therapy include identification of acute exacerbations and administration of antibiotics, suppression of the microbial load, treatment of underlying conditions, reduction of the excessive inflammatory response, promotion of bronchial hygiene, control of bronchial hemorrhage, and surgical removal of extremely damaged segments or lobes that

may be a nidus for infection or bleeding. The literature regarding management covers strategies that have been evaluated in patients with cystic fibrosis or COPD; studies focused on bronchiectasis have included fewer patients, and the results have not been as favorable.

#### Acute Exacerbations or Bronchitis

The identification of a respiratory exacerbation is even more complex in patients with bronchiectasis than in patients with COPD. In COPD, a worsening of dyspnea and an increase in the volume and purulence of sputum are often used as criteria for identifying exacerbations. In patients with chronic bronchiectasis, sputum is chronically purulent. In the largest prospective study of patients with bronchiectasis,<sup>69</sup> an exacerbation was defined as including four of the nine symptoms listed in Table 4. Early antibiotic therapy for suspected exacerbations in patients with bronchiectasis would probably limit the vicious circle. Reasonable first choices for such therapy include a fluoroquinolone such as levofloxacin<sup>70</sup> or ciprofloxacin. The appropriate duration of therapy has not been established, but a minimum of 7 to 10 days is common practice. Sputum culture and sensitivity testing are indicated in patients who do not have a response to an initial course of antibiotics or have an organism that is known to be resistant.

#### Prevention or Suppression of Microbes

Four centers (in Hong Kong; Tyler, Texas; Barcelona, Spain; and Cambridge, United Kingdom) with a specialization in bronchiectasis have examined sputum or bronchoscopic specimens to isolate the bacterial flora in patients with steady-state bronchiectasis (no acute exacerbation). The most frequently isolated potential pathogens were *H. influenzae* (in 29 to 42 percent of cases), *P. aeruginosa* (13 to 31 percent), and *Streptococcus pneumoniae* (6 to 13 percent).<sup>15,51,71,72</sup> The dynamics of colonization can be demonstrated by genetic studies of bacteria. Six of 28 patients with bronchiectasis from whom cultures were obtained monthly over a period of two years repeatedly tested positive for *Branhamella catarrhalis*. Analysis of restriction-fragment-length polymorphisms after pulsed-field gel electrophoresis of DNA from the organisms found multiple strains and revealed that each strain remained present for a mean of 2.3 months. There was no relation between the changes in strain and either the occurrence of exacerbations or the use of antibiotic therapy. The acquisition and clearance of a strain is a complex, dynamic process involving host factors and receptor sites on the organism that may help define the ability of an organism to persist or to damage airways.<sup>73</sup> There are no data available to indicate whether virus infection plays a direct part in

**TABLE 4.** SYMPTOMS OF ACUTE EXACERBATION OF BRONCHIECTASIS.\*

|  |
|--|
| Change in sputum production                                  |
| Increased dyspnea  |
| Increased cough  |
| Fever (temperature, > 38.0°C)                                |
| Increased wheezing   |
| Malaise, fatigue, lethargy, or decreased exercise tolerance  |
| Reduced pulmonary function                                   |
| Radiographic changes consistent with a new pulmonary process |
| Changes in chest sounds                                      |

\*In a study by O'Donnell et al.,<sup>69</sup> a patient with four of these symptoms was defined as having an acute exacerbation.

acute exacerbations, although when neutrophils from patients with bronchiectasis are infected in vitro with strains of influenza A (but not when they are infected with influenza B), there is a reduction in lysozyme release and bactericidal activity. This effect may contribute to the increased bacterial load and to acute exacerbations.<sup>74</sup>

Emerging evidence regarding the presence and quantity of bacteria such as *P. aeruginosa* and *H. influenzae* suggests that these pathogens stimulate a neutrophilic and inflammatory mediator response in the airway.<sup>75</sup> The presence of *P. aeruginosa* is associated with increased sputum production, more extensive bronchiectasis visible on CT,<sup>57,76</sup> more hospitalizations, and reduced quality of life.<sup>77,78</sup> Since bacterial pathogens are thought to have an active destructive role, various suppressive antibiotic strategies have been used. Erythromycin, administered in a dose of 500 mg twice daily, has been shown in a small eight-week pilot study to reduce the volume of sputum and to improve pulmonary function.<sup>79</sup> The fluoroquinolones are the only oral agents that are effective against *P. aeruginosa*. Resistance often develops after one or two treatment cycles.<sup>80</sup> The administration of aerosolized antibiotics is an intriguing alternative that would allow concentrated regional therapy, reduced systemic absorption and toxic effects, and use of a delivery device that is already familiar to many patients with respiratory disease. Two randomized, double-blind pilot studies have been reported. In one, 300 mg of tobramycin was administered by aerosol twice daily for four weeks; treatment reduced sputum pseudomonas density by 10,000 colony-forming units per gram of sputum, whereas there was no reduction with placebo, but there was no change in pulmonary function.<sup>81</sup> In the other study, 40 mg of aerosolized gentamicin administered twice daily for three days reduced the level of neutrophilic enzymes in sputum, sputum

production, and the frequency of nocturnal desaturation; peak expiratory flow was also improved.<sup>82</sup>

The American Thoracic Society has developed a statement to help guide the management of *M. avium* complex infection; it recommends the use of an antibiotic regimen, including azithromycin or clarithromycin, rifampin or rifabutin, and ethambutol, until the cultures have remained negative for one year.<sup>83</sup> Inspired by a report on the effectiveness of interferon gamma as an adjunctive treatment for *M. avium* complex infection,<sup>84</sup> a prospective multicenter study of aerosolized interferon gamma has been initiated by InterMune Pharmaceuticals (Burlingame, Calif.).

Traditional therapy for allergic bronchopulmonary aspergillosis has involved the augmentation of corticosteroid dosing. In a randomized trial (which was double-blind for the first 16 weeks and open-label for the second 16 weeks), the addition of itraconazole (200 mg twice daily for the first 16 weeks and 200 mg once daily for the second 16 weeks) resulted in significantly better clinical responses than with placebo (a decrease in the level of total IgE, an increase in exercise tolerance, and an improvement in pulmonary function, as well as a decrease in the dose of prednisone). The results were more favorable among those without bronchiectasis (60 percent of whom had a response) than among those with bronchiectasis (31 percent of whom had a response).<sup>23</sup>

#### Bronchopulmonary Hygiene

Enhancing the removal of respiratory secretions in patients with bronchiectasis is beneficial.<sup>85</sup> In addition to the control of cough, postural drainage, chest physiotherapy, and thinning and loosening of secretions, the administration of a bronchodilator and of inhaled corticosteroids has been part of maintenance therapy and treatment for acute exacerbations.

The action of chest percussion and postural drainage is analogous to forcefully emptying the last remnants from a ketchup bottle. Traditional chest clapping or cupping has largely been replaced by the use of inflatable vests or mechanical vibrators applied to the chest. Reclining prone on a bed with the head down over the side is necessary, but it is difficult or uncomfortable for many patients. Oral devices that apply positive end-expiratory pressure maintain the patency of the airway during exhalation and accomplish many of the same goals as postural drainage in a shorter time and with less discomfort.<sup>86</sup> In spite of decades of experience and many uncontrolled trials, a systematic review (by the methods of the Cochrane Collaboration) found little justification for chest percussion and postural drainage.<sup>87</sup>

Maintaining adequate systemic hydration, enhanced by nebulization with saline, remains a necessity for patients with viscous secretions and mucous plug-

ging. Acetylcysteine (20 percent solution) delivered by nebulizer thins secretions, but it is unclear whether such therapy improves clinical end points. DNA is a major degradation product of neutrophils and bacteria that contributes to viscous secretions. The use of aerosolized recombinant human DNase (rhDNase) in patients with bronchiectasis has been studied in a large, international, randomized, controlled trial. At the end of the six-month trial, 173 patients receiving rhDNase had more pulmonary exacerbations and a greater reduction in FEV<sub>1</sub> than 176 patients receiving placebo.<sup>69</sup> The rhDNase is approved for patients with cystic fibrosis but not for those with bronchiectasis.

There have been no long-term studies of aerosolized bronchodilator therapy with beta-adrenergic agonists or anticholinergic medications, but the use of aerosolized corticosteroids has been studied. In a double-blind, placebo-controlled, six-week crossover study involving 20 patients, 750  $\mu$ g of beclomethasone dipropionate twice daily reduced the mean sputum volume and improved the FEV<sub>1</sub>.<sup>88</sup> In a double-blind, randomized, placebo-controlled, four-week study involving 24 patients, 500  $\mu$ g of fluticasone propionate twice daily reduced sputum leukocyte density and the levels of inflammatory mediators (interleukin-1B, interleukin-8, and leukotriene B4); there was no change in pulmonary function.<sup>89</sup> There have been no studies of oral prednisone therapy in patients with bronchiectasis. Oral indomethacin and inhaled indomethacin (which has not been approved by the Food and Drug Administration) have been shown to reduce sputum volume and neutrophil mediators.<sup>9</sup>

#### Surgery

The role of surgery for bronchiectasis has declined but not disappeared. The goals of surgery include the removal of an obstructing tumor or the residue of a foreign body; the elimination of the segments or lobes that are the most damaged and that are suspected of contributing to acute exacerbations, overwhelming viscous secretions, mucous impaction, and plugs; the elimination of areas that are subject to uncontrolled hemorrhage; and the removal of damaged lung suspected of harboring problematic organisms such as multidrug-resistant *M. tuberculosis*<sup>90</sup> or *M. avium* complex.<sup>91</sup> Three surgical centers have described their experience with such surgery during the past decade, with a mean follow-up of four to six years. They have noted improvement in symptoms in more than 90 percent of patients, with perioperative mortality of less than 3 percent.<sup>92-95</sup> Double-lung transplantation is now considered for patients with cystic fibrosis and respiratory failure; it is associated with a survival rate of 75 percent at one year and 48 percent at five years.<sup>96</sup> Patients with other forms of bron-



chiectasis have also undergone lung transplantation, but separate statistics on outcomes are not available.<sup>97</sup>

### Hemoptysis

Life-threatening hemoptysis (of more than 600 ml of blood per day) may occur in patients with bronchiectasis and requires an aggressive, coordinated approach to management. After the airway has been protected by having the patient recline on the side where the bleeding is suspected or by endotracheal intubation, bronchoscopy or CT of the chest<sup>98</sup> is warranted to help determine which lobe or side is bleeding. If interventional radiology is available, aortography and cannulation of the bronchial arteries may visualize the site of extravasation of blood or collateral neovascularization so that embolization can be performed.<sup>99</sup> Surgery may still be required to resect an area suspected of bleeding.<sup>92,95</sup>

### PROGNOSIS

Keistinen et al.<sup>100</sup> reviewed the National Hospital Discharge Register in Finland and identified 842 patients with bronchiectasis who were 35 to 74 years of age between 1982 and 1986 and matched them (according to sex and age) with patients with asthma and patients with COPD. During a follow-up period of 8.0 to 12.9 years ending in 1993, the number of hospitalizations for patients with bronchiectasis varied widely (range, 1 to 51; mean, 2.2). There were 239 deaths among the patients with bronchiectasis (28 percent), 165 deaths among the patients with asthma (20 percent), and 319 deaths among the patients with COPD (38 percent). The underlying disease was the primary cause of death in the patients with bronchiectasis and those with COPD. Cardiac disease was the primary cause of death in the patients with asthma.<sup>100</sup>

### CONCLUSION AND REVISED DEFINITIONS

Bronchiectasis involves chronic respiratory tract infection and an up-regulation of the host inflammatory response. The emergence of high-resolution CT as the gold standard for testing has brought both precision and confusion, because other respiratory diseases also involve dilatation of the airways. A revised definition of purulent bronchiectasis based on findings in two large series of patients<sup>15,69</sup> might include as criteria for diagnosis the chronic daily production of mucopurulent sputum plus compatible findings on high-resolution CT. Although there is no defined cause in 50 percent of cases, the identification of humoral immunodeficiency, infections due to mycobacteria and pseudomonas, cystic fibrosis, or allergic bronchopulmonary aspergillosis has important implications for prognosis and management. A definition of acute exacerbations should involve a combi-

nation of criteria related to clinical findings, concentrations of inflammatory airway cells and mediators, types of microbiologic organisms, and pulmonary function, so that treatment strategies may be compared and assessed. Acute exacerbations must be treated promptly. Attention to bronchopulmonary hygiene is probably beneficial but requires confirmatory investigations with useful end points, including sputum volume, pulmonary function, and standardized measures of quality of life.<sup>77</sup>

*I am indebted to Drs. Sonia Buist, Steven Primack, and Steven Weinberger for their review and comments; and to Linda Alms for assistance in the preparation of the manuscript.*

### REFERENCES

1. Laennec RTH. A treatise on the disease of the chest. Forbes J, trans. New York: Library of the New York Academy of Medicine, Hafner Publishing, 1962:78.
2. Reid LM. Reduction in bronchial subdivision in bronchiectasis. *Thorax* 1950;5:233-47.
3. Singleton R, Morris A, Redding G, et al. Bronchiectasis in Alaska Native children: causes and clinical courses. *Pediatr Pulmonol* 2000;29:182-7.
4. Cole PJ. Inflammation: a two-edged sword — the model of bronchiectasis. *Eur J Respir Dis Suppl* 1986;147:6-15.
5. Gaga M, Bentley AM, Humbert M, et al. Increases in CD4+ T lymphocytes, macrophages, neutrophils and interleukin 8 positive cells in the airways of patients with bronchiectasis. *Thorax* 1998;53:685-91.
6. Tsang KW, Chan K, Ho P, et al. Sputum elastase in steady-state bronchiectasis. *Chest* 2000;117:420-6.
7. Richman-Eisenstat JBY, Jorens PG, Hebert CA, Ueki I, Nadel JA. Interleukin-8: an important chemoattractant in sputum of patients with chronic inflammatory airway diseases. *Am J Physiol* 1993;264:L413-L418.
8. Shum DKY, Chan SCH, Ip MSM. Neutrophil-mediated degradation of lung proteoglycans: stimulation by tumor necrosis factor-alpha in sputum of patients with bronchiectasis. *Am J Respir Crit Care Med* 2000;162:1925-31.
9. Tamaoki J, Chiyotani A, Kobayashi K, Sakai N, Kanemura T, Takizawa T. Effect of indomethacin on bronchorrhea in patients with chronic bronchitis, diffuse panbronchiolitis, or bronchiectasis. *Am Rev Respir Dis* 1992;145:548-52.
10. Limper AH, Prakash UBS. Tracheobronchial foreign bodies in adults. *Ann Intern Med* 1990;112:604-9.
11. Kwon KY, Myers JL, Swensen SJ, Colby TV. Middle lobe syndrome: a clinicopathological study of 21 patients. *Hum Pathol* 1995;26:302-7.
12. Seijo LM, Sterman DH. Interventional pulmonology. *N Engl J Med* 2001;344:740-9.
13. Cohen M, Sahn SA. Bronchiectasis in systemic diseases. *Chest* 1999;116:1063-74.
14. Johnston IDA, Strachan DP, Anderson HR. Effect of pneumonia and whooping cough in childhood on adult lung function. *N Engl J Med* 1998;338:581-7.
15. Pasteur MC, Helliwell SM, Houghton SJ, et al. An investigation into causative factors in patients with bronchiectasis. *Am J Respir Crit Care Med* 2000;162:1277-84.
16. Shah PL, Mawdsley S, Nash K, Cullinan P, Cole PJ, Wilson R. Determinants of chronic infection with *Staphylococcus aureus* in patients with bronchiectasis. *Eur Respir J* 1999;14:1340-4.
17. Prince DS, Peterson DD, Steiner RM, et al. Infection with *Mycobacterium avium* complex in patients without predisposing conditions. *N Engl J Med* 1989;321:863-8.
18. Huang JH, Kao PN, Adi V, Ruoss SJ. *Mycobacterium avium*-intracellular pulmonary infection in HIV-negative patients without preexisting lung disease: diagnostic and management limitations. *Chest* 1999;115:1033-40.
19. Newport MJ, Huxley CM, Huston S, et al. A mutation in the interferon- $\gamma$ -receptor gene and susceptibility to mycobacterial infection. *N Engl J Med* 1996;335:1941-9.
20. Huang JH, Oefner PJ, Adi V, et al. Analyses of the NRAMP1 and

- IFN-gammaR1 genes in women with Mycobacterium avium-intracellulare pulmonary disease. *Am J Respir Crit Care Med* 1998;157:377-81.
21. Kauffman HF, Tomee JFC, van der Werf TS, de Monchy JGR, Koeter GK. Review of fungus-induced asthmatic reactions. *Am J Respir Crit Care Med* 1995;151:2109-16.
  22. Chauhan B, Knutsen AP, Hutcheson PS, Slavin RG, Bellone CJ. T cell subsets, epitope mapping, and HLA-restriction in patients with allergic bronchopulmonary aspergillosis. *J Clin Invest* 1996;97:2324-31.
  23. Stevens DA, Schwartz HJ, Lee JY, et al. A randomized trial of itraconazole in allergic bronchopulmonary aspergillosis. *N Engl J Med* 2000;342:756-62.
  24. Holmes AH, Trotman-Dickenson B, Edwards A, Peto T, Luzzi GA. Bronchiectasis in HIV disease. *Q J Med* 1992;85:875-82.
  25. Shiekh S, Madiraju K, Steiner P, Rao M. Bronchiectasis in pediatric AIDS. *Chest* 1997;112:1202-7.
  26. McGuinness G, Naidich DP, Garay S, Leitman BS, McCauley DI. AIDS associated bronchiectasis: CT features. *J Comput Assist Tomogr* 1993;17:260-6.
  27. Le Mauviel L. Primary ciliary dyskinesia. *West J Med* 1991;155:280-3.
  28. Bush A, Cole P, Hariri M, et al. Primary ciliary dyskinesia: diagnosis and standards of care. *Eur Respir J* 1998;12:982-8.
  29. Reed W, Carson JL, Moats-Staats BM, et al. Characterization of an axonemal dynein heavy chain expressed early in airway epithelial ciliogenesis. *Am J Respir Cell Mol Biol* 2000;23:734-41.
  30. Pennarun G, Escudier E, Chapelin C, et al. Loss-of-function mutations in a human gene related to *Cblamydomonas reinhardtii* dynein IC78 result in primary ciliary dyskinesia. *Am J Hum Genet* 1999;65:1508-19.
  31. Omran H, Häffner K, Völkel A, et al. Homozygosity mapping of a gene locus for primary ciliary dyskinesia on chromosome 5p and identification of the heavy dynein chain DNAH5 as a candidate gene. *Am J Respir Cell Mol Biol* 2000;23:696-702.
  32. Rosen FS, Cooper MD, Wedgwood RJP. The primary immunodeficiencies. *N Engl J Med* 1995;333:431-40.
  33. Manson D, Reid B, Dalal I, Roifman CM. Clinical utility of high-resolution pulmonary computed tomography in children with antibody deficiency disorders. *Pediatr Radiol* 1997;27:794-8.
  34. Cunningham-Rundles C, Bodian C. Common variable immunodeficiency: clinical and immunological features of 248 patients. *Clin Immunol* 1999;92:34-48.
  35. De Gracia J, Rodrigo MJ, Morell F, et al. IgG subclass deficiencies associated with bronchiectasis. *Am J Respir Crit Care Med* 1996;153:650-5.
  36. Hill SL, Mitchell JL, Burnett D, Stockley RA. IgG subclasses in the serum and sputum from patients with bronchiectasis. *Thorax* 1998;53:463-8.
  37. Umetsu DT, Ambrosino DM, Quinti I, Siber GR, Geha RS. Recurrent sinopulmonary infection and impaired antibody response to bacterial capsular polysaccharide antigen in children with selective IgG-subclass deficiency. *N Engl J Med* 1985;313:1247-51.
  38. Rodrigo MJ, Miravittles M, Cruz MJ, et al. Characterization of specific immunoglobulin G (IgG) and its subclasses (IgG1 and IgG2) against the 23-valent pneumococcal vaccine in a healthy adult population: proposal for response criteria. *Clin Diagn Lab Immunol* 1997;4:168-72.
  39. Buckley RH, Schiff RL. The use of intravenous immune globulin in immunodeficiency diseases. *N Engl J Med* 1991;325:110-7.
  40. Davis PB, Drumm M, Konstan MW. Cystic fibrosis. *Am J Respir Crit Care Med* 1996;154:1229-56.
  41. Highsmith WE, Burch LH, Zhou Z, et al. A novel mutation in the cystic fibrosis gene in patients with pulmonary disease but normal sweat chloride concentrations. *N Engl J Med* 1994;331:974-80.
  42. McMahon MJ, Swinson DR, Shettar S, et al. Bronchiectasis and rheumatoid arthritis: a clinical study. *Ann Rheum Dis* 1993;52:776-9.
  43. Shadick NA, Fanta CH, Weimblatt ME, O'Donnell W, Cobllyn JS. Bronchiectasis: a late feature of severe rheumatoid arthritis. *Medicine (Baltimore)* 1994;73:161-70.
  44. Cortet B, Flipo RM, Remy-Jardin M, et al. Use of high resolution computed tomography of the lungs in patients with rheumatoid arthritis. *Ann Rheum Dis* 1995;54:815-9.
  45. Hassan WU, Keaney NP, Holland CD, Kelly CA. High resolution computed tomography of the lung in lifelong non-smoking patients with rheumatoid arthritis. *Ann Rheum Dis* 1995;54:308-10.
  46. Swinson DR, Symmons D, Suresh U, Jones M, Booth J. Decreased survival in patients with co-existent rheumatoid arthritis and bronchiectasis. *Br J Rheumatol* 1997;36:689-91.
  47. Camus P, Colby TV. The lung in inflammatory bowel disease. *Eur Respir J* 2000;15:5-10.
  48. Camus P, Piard F, Ashcroft T, Gal AA, Colby TV. The lung in inflammatory bowel disease. *Medicine (Baltimore)* 1993;72:151-83.
  49. Mahadeva R, Walsh G, Flower CDR, Shneerson JM. Clinical and radiologic characteristics of lung disease in inflammatory bowel disease. *Eur Respir J* 2000;15:41-8.
  50. Silva JR, Jones JAH, Cole PJ, Poulter LW. The immunologic component of the cellular inflammatory infiltrate in bronchiectasis. *Thorax* 1989;44:668-73.
  51. Nicotra MB, Rivera M, Dale AM, Shepherd R, Carter R. Clinical, pathophysiological, and microbiologic characterization of bronchiectasis in an aging cohort. *Chest* 1995;108:955-61.
  52. Hansell DM. Bronchiectasis. *Radiol Clin North Am* 1998;36:107-28.
  53. Munro NC, Cooke JC, Currie DC, Strickland B, Cole PJ. Comparison of thin section computed tomography with bronchography for identifying bronchiectatic segments in patients with chronic sputum production. *Thorax* 1990;45:135-9.
  54. van der Bruggen-Bogaarts BABA, van der Bruggen HMJG, van Waes PFGM, Lammers JWJ. Assessment of bronchiectasis: comparison of HRCT and spiral volumetric CT. *J Comput Assist Tomogr* 1996;20:15-9.
  55. Desai SR, Wells AU, Cheah FK, Cole PJ, Hansell DM. The reproducibility of bronchial circumference measurements using computed tomography. *Br J Radiol* 1994;67:257-62.
  56. Kang EY, Miller RR, Muller NL. Bronchiectasis: comparison of preoperative thin section CT and pathologic findings in resected specimens. *Radiology* 1995;195:649-54.
  57. Lynch DA, Newell J, Hale V, et al. Correlation of CT findings with clinical evaluations in 261 patients with symptomatic bronchiectasis. *AJR Am J Roentgenol* 1999;173:53-8.
  58. Thomas RD, Blaquiére RM. Reactive mediastinal lymphadenopathy in bronchiectasis assessed by CT. *Acta Radiol* 1993;34:489-91.
  59. Loubeyre P, Paret M, Revel D, Wiesendanger T, Brune J. Thin-section CT detection of emphysema associated with bronchiectasis and correlation with pulmonary function tests. *Chest* 1996;109:360-5.
  60. Cartier Y, Kavanagh PV, Johkoh T, Mason AC, Muller NL. Bronchiectasis: accuracy of high resolution CT in the differentiation of specific diseases. *AJR Am J Roentgenol* 1999;173:47-52.
  61. Lynch DA, Newell JD, Tschomper BA, Cink TM, Newman LS, Bethel R. Uncomplicated asthma in adults: comparison of CT appearance of the lungs in asthmatic and healthy subjects. *Radiology* 1993;188:829-33.
  62. O'Brien C, Guest PJ, Hill SL, Stockley RA. Physiological and radiological characterisation of patients diagnosed with chronic obstructive pulmonary disease in primary care. *Thorax* 2000;55:635-42.
  63. Westcott JL, Cole SR. Traction bronchiectasis in end-stage pulmonary fibrosis. *Radiology* 1986;161:665-9.
  64. Wong-You-Cheong JJ, Leahy BC, Taylor PM, Church SE. Airways obstruction and bronchiectasis: correlation with duration of symptoms and extent of bronchiectasis on computed tomography. *Clin Radiol* 1992;45:256-9.
  65. Roberts HR, Wells AU, Milne DG, et al. Airflow obstruction in bronchiectasis: correlation between computed tomography features and pulmonary function tests. *Thorax* 2000;55:198-204.
  66. Murphy MB, Reen DJ, Fitzgerald MX. Atopy, immunological changes, and respiratory function in bronchiectasis. *Thorax* 1984;39:179-84.
  67. Pang J, Chan HS, Sung JY. Prevalence of asthma, atopy, and bronchial hyperreactivity in bronchiectasis: a controlled study. *Thorax* 1989;44:948-51.
  68. Bahous J, Cartier A, Pineau L, et al. Pulmonary function tests and airway responsiveness to methacholine in chronic bronchiectasis of the adult. *Bull Eur Physiopathol Respir* 1984;20:375-80.
  69. O'Donnell AE, Barker AF, Ilowite JS, Fick RB. Treatment of idiopathic bronchiectasis with aerosolized recombinant human DNase I. *Chest* 1998;113:1329-34.
  70. Tsang KWT, Chan W-M, Ho P-L, Chan K, Lam W-K, Ip MSM. A comparative study on the efficacy of levofloxacin and ceftazidime in acute exacerbation of bronchiectasis. *Eur Respir J* 1999;14:1206-9.
  71. Pang JA, Cheng A, Chan HS, Poon D, French G. The bacteriology of bronchiectasis in Hong Kong investigated by protected catheter brush and bronchoalveolar lavage. *Am Rev Respir Dis* 1989;139:14-7.
  72. Angrill J, Agusti C, de Celis R, et al. Bacterial colonisation in patients with bronchiectasis: microbiological pattern and risk factors. *Thorax* 2002;57:15-9.
  73. Klingman KL, Pye A, Murphy TF, Hill SL. Dynamics of respiratory tract colonization by *Branhamella catarrhalis* in bronchiectasis. *Am J Respir Crit Care Med* 1995;152:1072-8.
  74. Pang G, Clancy R, Cong M, Ortega M, Zhigang R, Reeves G. Influenza virus inhibits lysozyme secretion by sputum neutrophils in subjects with chronic bronchial sepsis. *Am J Respir Crit Care Med* 2000;161:718-22.
  75. Angrill J, Agusti C, de Celis R, et al. Bronchial inflammation and col-

- onization in patients with clinically stable bronchiectasis. *Am J Respir Crit Care Med* 2001;164:1628-32.
76. Miszkiel KA, Wells AU, Rubens MB, Cole PJ, Hansell DM. Effects of airway infection by *Pseudomonas aeruginosa*: a computed tomographic study. *Thorax* 1997;52:260-4.
77. Wilson CB, Jones PW, O'Leary CJ, Cole PJ, Wilson R. Validation of the St. George's Respiratory Questionnaire in bronchiectasis. *Am J Respir Crit Care Med* 1997;156:536-41.
78. Ho PL, Chan KN, Ip MSM, et al. The effect of *Pseudomonas aeruginosa* infection on clinical parameters in steady-state bronchiectasis. *Chest* 1998;114:1594-8.
79. Tsang KWT, Ho P-I, Chan K-N, et al. A pilot study of low-dose erythromycin in bronchiectasis. *Eur Respir J* 1999;13:361-4.
80. Rayner CFJ, Tillotson G, Cole PJ, Wilson R. Efficacy and safety of long-term ciprofloxacin in the management of severe bronchiectasis. *J Antimicrob Chemother* 1994;34:149-56.
81. Barker AF, Couch L, Fiel SB, et al. Tobramycin solution for inhalation reduces sputum *Pseudomonas aeruginosa* density in bronchiectasis. *Am J Respir Crit Care Med* 2000;162:481-5.
82. Lin HC, Cheng HF, Wang CH, Liu CY, Yu CT, Kuo HP. Inhaled gentamicin reduces airway neutrophil activity and mucus hypersecretion in bronchiectasis. *Am J Respir Crit Care Med* 1997;155:2024-9.
83. Wallace RJ Jr, Glassroth J, Griffith DE, Olivier KN, Cook JL, Gordin F. Diagnosis and treatment of disease caused by nontuberculous mycobacteria. *Am J Respir Crit Care Med* 1997;156:Suppl:S1-S25.
84. Holland SM, Eisenstein EM, Kuhns DB, et al. Treatment of refractory disseminated nontuberculous mycobacterial infection with interferon gamma: a preliminary report. *N Engl J Med* 1994;330:1348-55.
85. Pryor JA. Physiotherapy for airway clearance in adults. *Eur Respir J* 1999;14:1418-24.
86. Christensen EF, Nedergaard T, Dahl R. Long-term treatment of chronic bronchitis with positive expiratory pressure mask and chest physiotherapy. *Chest* 1990;97:645-50.
87. Jones A, Rowe BH. Bronchopulmonary hygiene physical therapy in bronchiectasis and chronic obstructive pulmonary disease: a systematic review. *Heart Lung* 2000;29:125-35.
88. Elborn JS, Johnston B, Allen E, Clarke J, McGarry J, Varghese G. Inhaled steroids in patients with bronchiectasis. *Respir Med* 1992;86:121-4.
89. Tsang KWT, Ho PL, Lam WK, et al. Inhaled fluticasone reduces sputum inflammatory indices in severe bronchiectasis. *Am J Respir Crit Care Med* 1998;158:723-7.
90. Pomerantz BJ, Cleveland JC Jr, Olson HK, Pomerantz M. Pulmonary resection for multi-drug resistant tuberculosis. *J Thorac Cardiovasc Surg* 2001;121:448-53.
91. Pomerantz M, Denton JR, Huitt GA, Brown JM, Powell LA, Iseman MD. Resection of the right middle lobe and lingula for mycobacterial infection. *Ann Thorac Surg* 1996;62:990-3.
92. Agasthian T, Deschamps C, Trastek VF, Allen MS, Pairolero PC. Surgical management of bronchiectasis. *Ann Thorac Surg* 1996;62:976-80.
93. Chiang TC, Kok VK, Tu HH, Su YM, Yeh CH, Chung MT. Surgical treatment of bronchiectasis: 10 years' experience. *Zhonghua Yi Xue Za Zhi (Taipei)* 1999;62:690-4.
94. Ashour M, Al-Kattan K, Rafay MA, Saja KF, Hajjar W, Al-Fraye AR. Current surgical therapy for bronchiectasis. *World J Surg* 1999;23:1096-104.
95. Fujimoto T, Hillejan L, Stamatis G. Current strategy for surgical management of bronchiectasis. *Ann Thorac Surg* 2001;72:1711-5.
96. Yankaskas JR, Mallory GB Jr. Lung transplantation in cystic fibrosis: consensus conference statement. *Chest* 1998;113:217-26.
97. Arcasoy SM, Kotloff RM. Lung transplantation. *N Engl J Med* 1999;340:1081-91.
98. McGuinness G, Beacher JR, Harkin TJ, Garay SM, Rom WN, Naidich DP. Hemoptysis: prospective high-resolution CT/bronchoscopic correlation. *Chest* 1994;105:1155-62.
99. Mal H, Rullon I, Mellot F, et al. Immediate and long-term results of bronchial artery embolization for life-threatening hemoptysis. *Chest* 1999;115:996-1001.
100. Keistinen T, Saynajakangas O, Tuupponen T, Kivela SL. Bronchiectasis: an orphan disease with a poorly-understood prognosis. *Eur Respir J* 1997;10:2784-7.

Copyright © 2002 Massachusetts Medical Society.

---

#### IMAGES IN CLINICAL MEDICINE

---

The *Journal* welcomes consideration of new submissions for Images in Clinical Medicine. Instructions for authors and procedures for submissions can be found on the *Journal's* Web site at <http://www.nejm.org>. At the discretion of the editor, images that are accepted for publication may appear in the print version of the *Journal*, the electronic version, or both.

---