

# FEVER & RASH | The perplexing presentation of a common disease

Shahana Baig-Lewis, MD, MPH and Targol Saedi, MD, FACP  
Oregon Health & Science University, Department of Internal Medicine



## INTRODUCTION

Epstein-Barr virus (EBV) is a widely disseminated herpesvirus that is spread by intimate contact between susceptible persons and asymptomatic EBV shedders. Though the majority of EBV infections worldwide are sub-clinical, EBV can cause a number of primary infections, complications and malignancies and should be considered in the differential for any patient presenting with fever, rash and cytopenias (particularly lymphocytopenia).

## CASE DESCRIPTION

35 year old G5P4 was admitted to the hospital 17 days post partum with acute onset fever, arthralgia and rash.

- Symptoms started approximately 2 weeks post partum
- Daily fever (102-103 F)
- Extensive pruritic rash (face, torso, upper and lower extremities)
- Diffuse painful swelling of bilateral hands and feet



### ROS

- Recent productive cough
- No coryza, rhinorrhea, chest pain, dyspnea, abdominal pain, dysuria, diarrhea, initiation of new medication (except Labetalol) or sick contacts
- No prior history of arthralgia, IBD, rash, or uveitis



### Family Hx

- Younger sister died from complications of leukemia
- Maternal grandmother with hx of thyroid malignancy



### PMHx

- Gestational Diabetes and Preeclampsia
- Iron Deficiency Anemia



### Medications

- Labetalol 300 mg BID (discontinued 12 days post partum)
- ASA 81 mg daily
- Ferrous Sulfate 325 mg daily

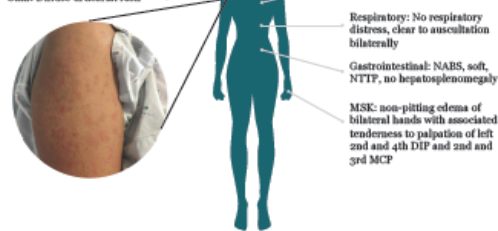
## PHYSICAL EXAM

Vitals: T max: 103.3 F, HR: 94, BP: 120/80, RR: 16, SpO2: 97% on RA

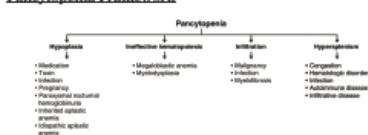
General: Young female, NAD

HEENT: No scleral injection or discharge, no oral lesions

Skin: Diffuse urticarial rash



## Pancytopenia Framework

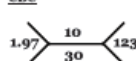


## Blood Smear



## LABORATORY STUDIES

### CBC



### Differential

- 74% neutrophils
- 11% lymphocytes (low)
- 1.8% monocytes
- 13.3% eosinophils (high, though absolute eosinophil count normal)

### BMP

137/4.0/107/22/8.0/0.42/93

### LEIs

AST: 59 (last 20)  
ALT: 36  
Alk Phos: 186  
T.Bili: 0.5  
Total Protein: 7.5  
Albumin: 3.1

ANA: negative  
C3: 148 (nl)  
C4: 15 (low, nl range 16-47)

HIV 1-2: negative  
HCV Ab: not detected  
HBV not detected  
Group A Strep: negative  
CMV: negative  
EBV: Positive, EBV Ab to viral capsid antigen IgG >600, IgM not detected,  
Ab to nuclear Ag >600, EBV Ab to early D antigen IgG positive

## DISCUSSION

Rheumatology was consulted due to concern for possible autoimmune etiology, particularly SLE, who felt history and exam were not typical for SLE, though advised checking ANA and complements, which were negative and normal respectively.

Dermatology was consulted and their differential for her urticaria was broad, including infection and malignancy given her leukopenia.

Hematology was consulted who felt her cytopenias were likely secondary to marrow suppression from viral infection versus medication toxicity and recommended checking for infectious etiologies. Evaluation notable for negative HIV 1-2, negative hepatitis C Ab, non-detectable hepatitis B surface Ag, surface Ab and core Ab, negative group A streptococcus, negative CMV and positive EBV studies (EBV Ab to viral capsid antigen IgG > 600, Ab to nuclear Ag >600 and detectable EBV Ab to early D antigen). Based on this constellation of findings and EBV results, diagnosis of EBV viremia was made. Patient clinically and objectively improved and was able to be discharged home with continued supportive care.

Most people will be infected with Epstein-Barr virus during their lifetime and remain asymptomatic. Associated signs/symptoms include fatigue, fever, sore throat, lymphadenopathy, hepatosplenomegaly, rash, neurologic disorders and hematologic disorders including cytopenias which can mimic other rheumatologic, malignant or viral diseases. Checking antibodies against EBV capsid antigen, which typically appear at the onset of acute infection and remain positive for life, EBV nuclear antigen-2 and EBV early Ag can be helpful in diagnosis.

## TAKE HOME POINTS

- 1) Consider EBV infection in patients with fever, rash and cytopenias.
- 2) Confirm EBV diagnosis by checking EBV viral capsid Ag (IgM and IgG), Early Ag, and EBV Nuclear Ag.
- 3) Supportive care is the cornerstone of treatment for acute EBV infection/viremia. There is limited data to support the use of corticosteroids or antiviral agents.

## REFERENCES

- 1) Center's for Disease Control and Prevention. Epstein-Barr Virus and Infectious Mononucleosis. May 10 2018. <https://www.cdc.gov/epstein-barr/laboratory-testing.html>. Accessed 07 August 2018.
- 2) Nofal R, E, et al, Steroids for symptom control in infectious mononucleosis (review). Cochrane Reviews. 2015 (11) 1-59.
- 3) Pauchale et al. Serologic diagnosis of Epstein-Barr Virus infection. Problems and Solutions. World Journal of Virology. 2012 Feb 12 (1): 31-43.