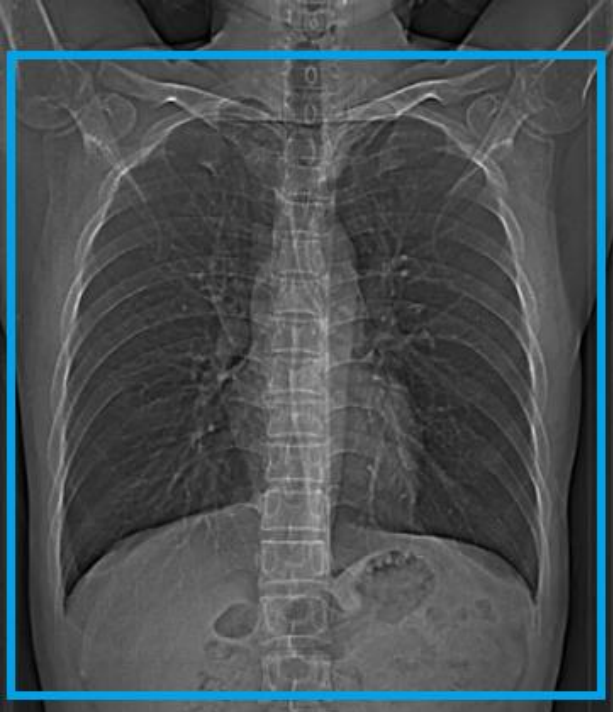


CT Chest Navigational Bronchoscopy WO

Position/Landmark	Feet first. Position at chin
Scout	
Scan coverage	Entire lungs. Apices of lungs to mid kidney
Respiratory Phase	Inspiratory
Scan Type	Helical
PO Prep	None
Reason for exam	The scan is primarily used as a planning scan for navigational bronchoscopy
Scan notes	FoV must be within 1cm of lung field for Ion (manufacturer) standards

Scan Settings – CT Chest Navigational Bronchoscopy WO			
	Siemens SOMATOM Force	Philips iCT/Ingenuity	Canon Aquilion ONE Vision
kV Setting:	CAREkV Ref kV= 110	120	120
mA/mAs/TCM Setting:	CAREdose4D QRM = 61, Dose Savings Slider at 3	120 mAs (264 mA)	250 mA
Iterative Reconstruction Setting:	Admire Strength 3	iDose 2	AIDR 3D Mild

Scan and Recon Instructions – CT Chest Navigational Bronchoscopy WO	
1.	Scout – Shoulders to mid abdomen (Arms above head)
2.	Inspiratory- Practice with the patient! Make sure the patient takes a deep breath in and is able to hold it for scan duration.
3.	<p>Scan above Lung Apices to below lung Costophrenic Angles.</p> <ul style="list-style-type: none"> - Axial 3mm x 1.5mm (soft tissue) - Axial 3mm x 1.5mm (lung) - Coronal 3mm x 1.5mm (lung) - Coronal 3mm x 1.5mm (soft tissue) - Sagittal 3mm x 1.5mm (soft tissue) - Thins 0.8mm x 0.6m (soft tissue)- varies based on scanner. Per manufacturer requirements thickness must be 0.5mm-1.0mm and spacing should be 0.5-0.8mm.