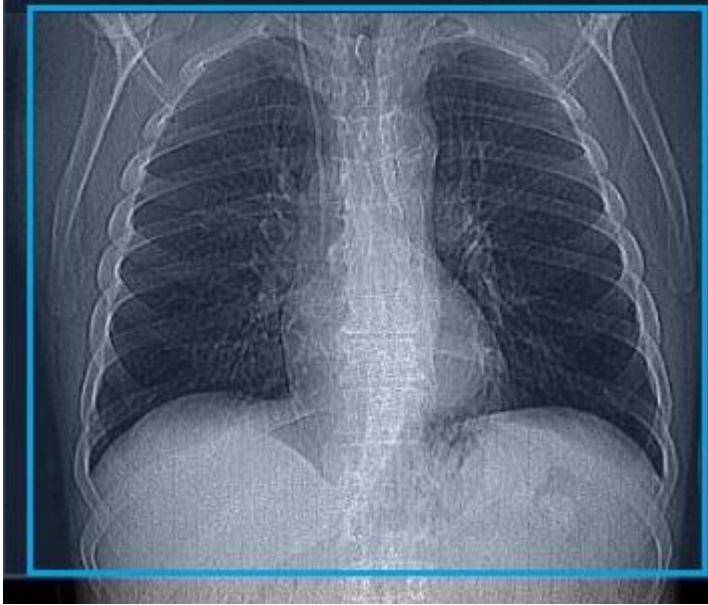


CT Lung Screening/ 6mo FU Lung Screening

****6 Mo Follow Up Lung Screening is the same as the initial lung screening – just ordered differently so the nurse case managers can follow patients progress* Per Gail Stanton.**

Position/Landmark	Feet first. Position at chin
Scout	
Scan coverage	Entire lungs. Apices of lungs to mid kidney
Respiratory Phase	Inspiratory
Scan Type	Helical
PO Prep	None
Reason for exam	The scan is primarily used as a screening tool to detect lung cancer at an early stage
Scan notes	Has very specific requirements for billing, do not change an order to lung screening unless instructed by a radiologist as insurance will not cover it. FOV must be within 1cm of lung field for ACR standards

Scan Settings - CT Lung Screening				
	Siemens SOMATOM Force	Philips iCT/Ingenuity	Canon Aquilion ONE Vision	GE Discovery PET CT
kV Setting:	CAREKV Ref kV= Sn100	120	120	120
mA/mAs/TCM Setting:	CAREdose4D QRM = 101, Dose Savings Slider at 3	DoseRight DRI = 10	SureExposure3D (SD =25)	Smart mA, NI=24, 40 %Dose Reduction, 5mm Slice Thickness
Iterative Reconstruction Setting:	Admire Strength 3	iDose 2	AIDR 3D STD	ASIR 40%

Scan and Recon Instructions - CT Lung Screening	
1.	Scout – Above lung Apices through below Lungs (Arms above head)
2.	Inspiratory- Practice with the patient! Make sure the patient takes a deep breath in and is able to hold it for scan duration.
3.	Apices of lungs to mid kidney (Blue box) <ul style="list-style-type: none"> - Axial 1mm x 0.5mm (soft tissue) - Axial 1mm x 0.5mm (lung) - Coronal 1mm x 0.5mm (lung) - Coronal 3mm x 1.5mm (soft tissue) - Sagittal 3mm x 1.5mm (soft tissue) - Coronal MIP 10mm x 5mm (lung) - Axial MIP 10mm x 5mm (lung)