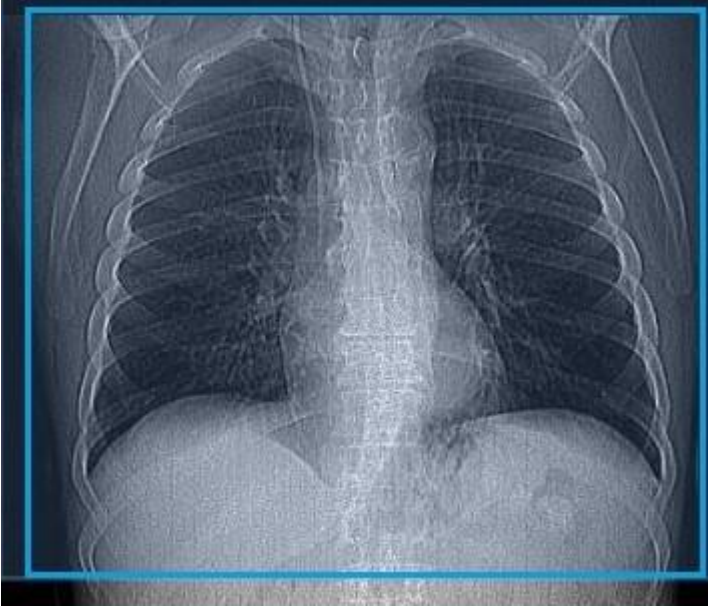


CT Chest Venogram

Position/Landmark	Feet first. Position at chin or mid-shoulder
Scout	
Scan coverage	Entire lungs. Apices of lungs to mid kidney
Respiratory Phase	Inspiratory
Scan Type	Helical
IV access	22G minimum Antecubital
IV contrast	100mL OMNI 350 @ 2.0mL/sec.
PO Prep	None
Reason for exam	The scan is primarily used for assessment of central venous system in chest.

Scan Settings – CT Chest Venogram			
	Siemens SOMATOM Force	Philips iCT/Ingenuity	Canon Aquilion ONE Vision
kV Setting:	CAREkV Ref kV= 110	120	120
mA/mAs/TCM Setting:	CAREdose4D QRM = 61, Dose Savings Slider at 7	DoseRight DRI = 19, Liver Boost +3	SureExposure3D (SD=12.5)
Iterative Reconstruction Setting:	Admire Strength 3	iDose 2	AIDR 3D Mild

Scan – CT Chest Venogram	
1.	Scout – Chin through Lungs to mid abdomen (Arms above head)
2.	Inspiratory- Practice with the patient! Make sure the patient takes a deep breath in and is able to hold it for scan duration.
3.	Begin injection at 2ml/sec for a total of 100ml.
4.	Initialize scan at 90s post injection start time. This time may vary depending on protocol – <i>Contact rads with any questions for a specific patient</i>
5.	Apices of lungs to mid kidney (Blue box) <ul style="list-style-type: none"> - Axial 3mm x 1.5mm (soft tissue) - Axial 3mm x 1.5mm (lung) - Coronal 3mm x 1.5mm (lung) - Coronal 3mm x 1.5mm (soft tissue) - Sagittal 3mm x 1.5mm (soft tissue)