

# Ophthalmic Diseases for Older Adults

Dong-wouk Park, MD



CASEY EYE  
*Institute*

# Disclosures

- No pertinent conflict of interest

OHSU

CPD

# Objectives

- Understand the most common causes of vision loss in the older population
- Review common but non-urgent presentation of ocular pathologies
- Review the common presentation of ocular pathologies that require urgent evaluation

# Eye and senescence

## Why should you care?

- Vision loss is a/w...
  - Falls
    - 3x risk of multiple falls with decreased vision<sup>1</sup>
    - Increased risk of hip, wrist, and humerus fractures<sup>2,3</sup>
  - Depression<sup>4</sup>
  - Dementia/delirium<sup>5-7</sup>
  - Inability to drive<sup>8-10</sup>
  - Overall function<sup>11</sup>
  - And many more...

1. Nevitt MC, Cummings SR, Kidd S, Black D. Risk factors for recurrent nonsyncopal falls. A prospective study. *JAMA* 1989;261:2663-2668.

2. Cummings SR, Nevitt MC, Browner WS, et al. Risk factors for hip fracture in white women. Study of Osteoporotic Fractures Research Group. *N Engl J Med* 1995;332:767-773.

3. Kelsey JL, Browner WS, Seeley DG, et al. Risk factors for fractures of the distal forearm and proximal humerus. The Study of Osteoporotic Fractures Research Group (published erratum appears in *Am J Epidemiol* 1992;135:1183). *Am J Epidemiol* 1992;135:477-489.

4. Carabellese C, Appollonio I, Rozzini R, et al. Sensory impairment and quality of life in a community elderly population. *J Am Geriatr Soc* 1993;41:401-407.

5. Uhlmann RF, Larson EB, Koepsell TD, et al. Visual impairment and cognitive dysfunction in Alzheimer's disease. *J Gen Intern Med* 1991;6:126-132.

6. George J, Bleasdale S, Singleton SJ. Causes and prognosis of delirium in elderly patients admitted to a district general hospital. *Age Ageing* 1997;26:423-427.

7. Steinman SB, Steinman BA, Trick GL, Lehmkuhle S. A sensory explanation for visual attention deficits in the elderly. *Optom Vis Sci* 1994;71:743-749.

8. Kosnik WD, Sekuler R, Kline DW. Self-reported visual problems of older drivers. *Hum Factors* 1990;32:597-608.

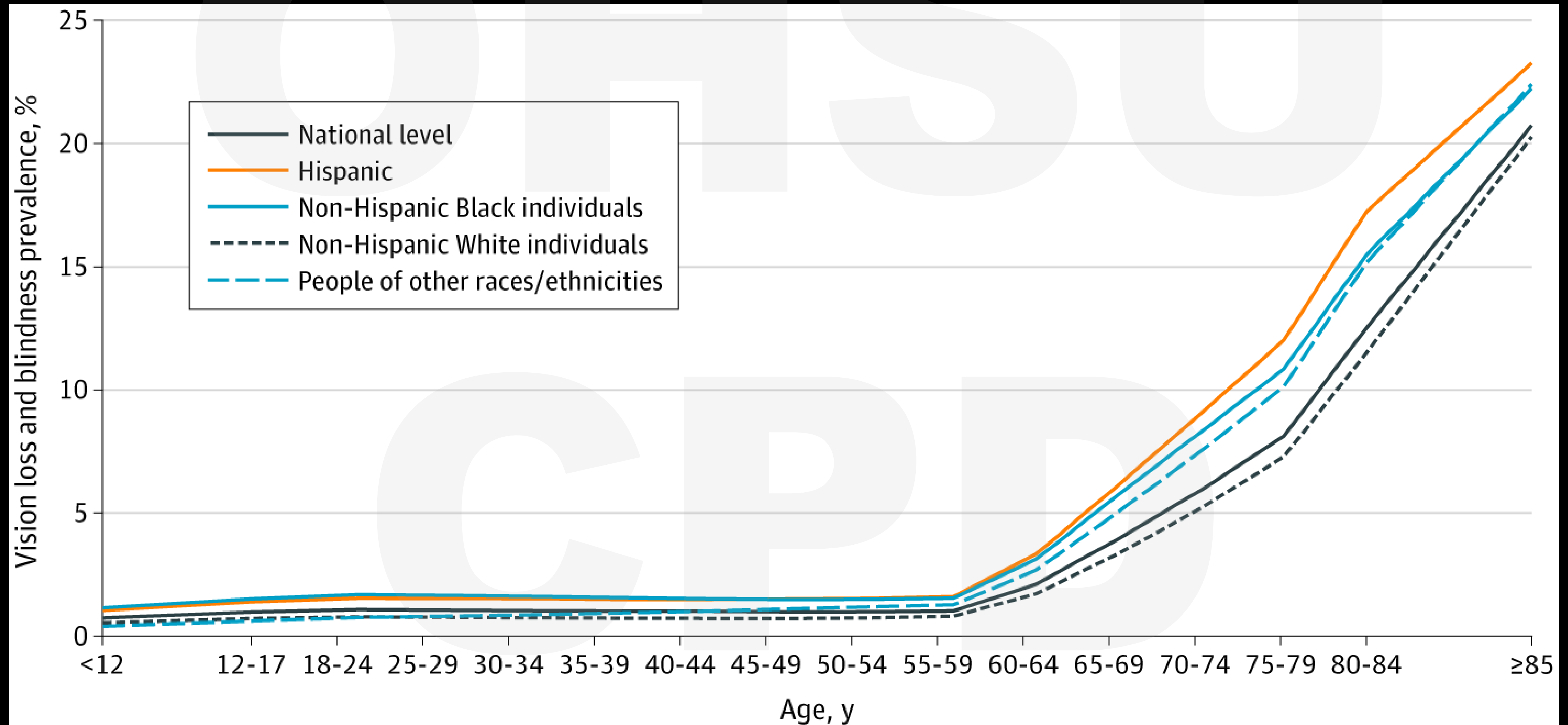
9. Kline DW, Kline TJ, Fozard JL, et al. Vision, aging, and driving: the problems of older drivers. *J Gerontol* 1992;47:P27-P34.

10. Ball K, Owsley C, Stalvey B, et al. Driving avoidance and functional impairment in older drivers. *Accid Anal Prev* 1998;30:313-322.

11. Salive ME, Guralnik J, Glynn RJ, et al. Association of visual impairment with mobility and physical function. *J Am Geriatr Soc* 1994;42:287-292.

# Vision Loss Increases after age 60


JAMA Ophthalmol. 2021;139(7):717-723. doi:10.1001/jamaophthalmol.2021.0527



# Eye and senescence

## Where to find biological aging?

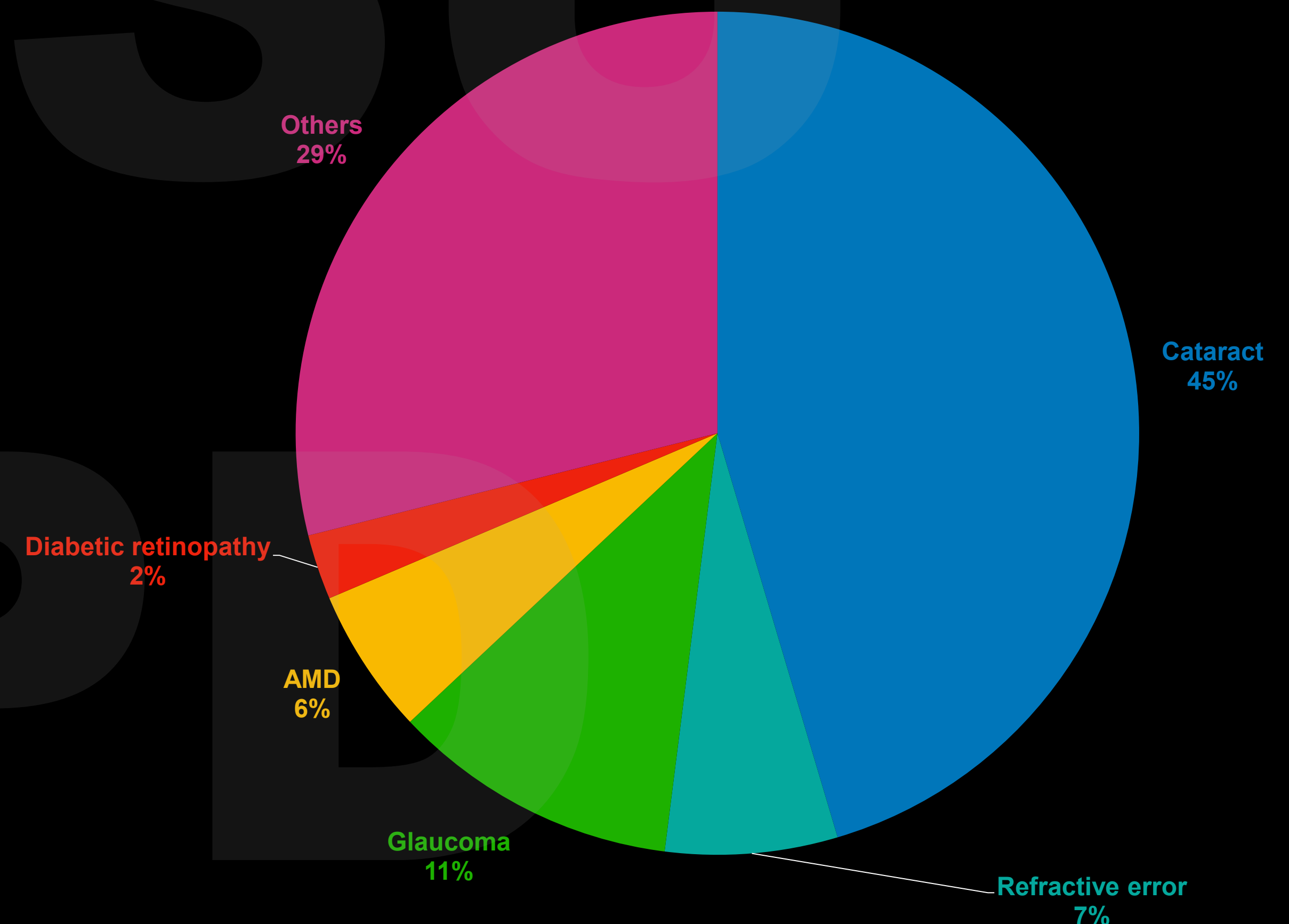
- Eye may be the first organ to detect senescence
  - Uveitis
  - Similarity of AMD and other aging diseases
  - Detection of early dementia
  - Chronic disease



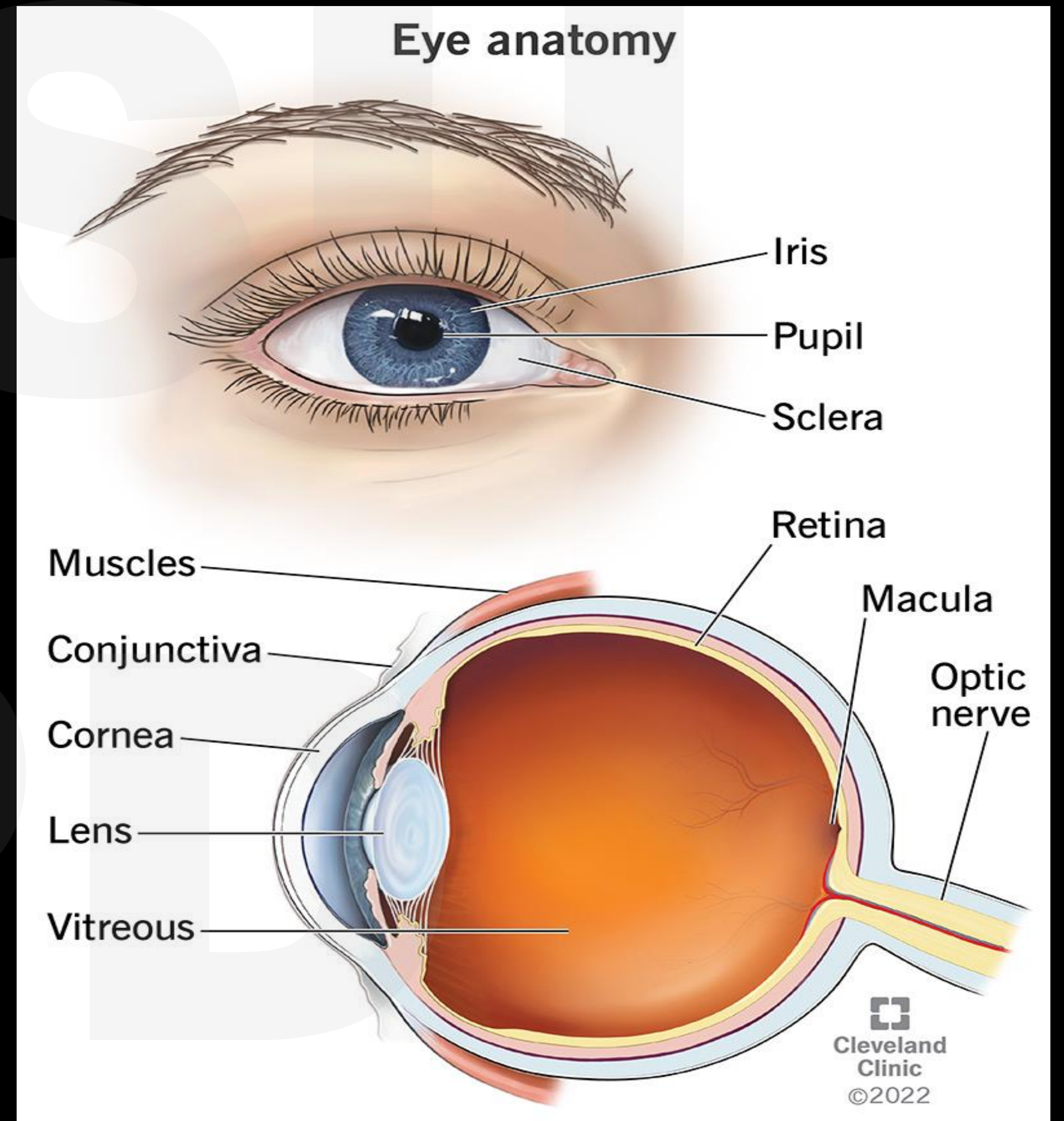
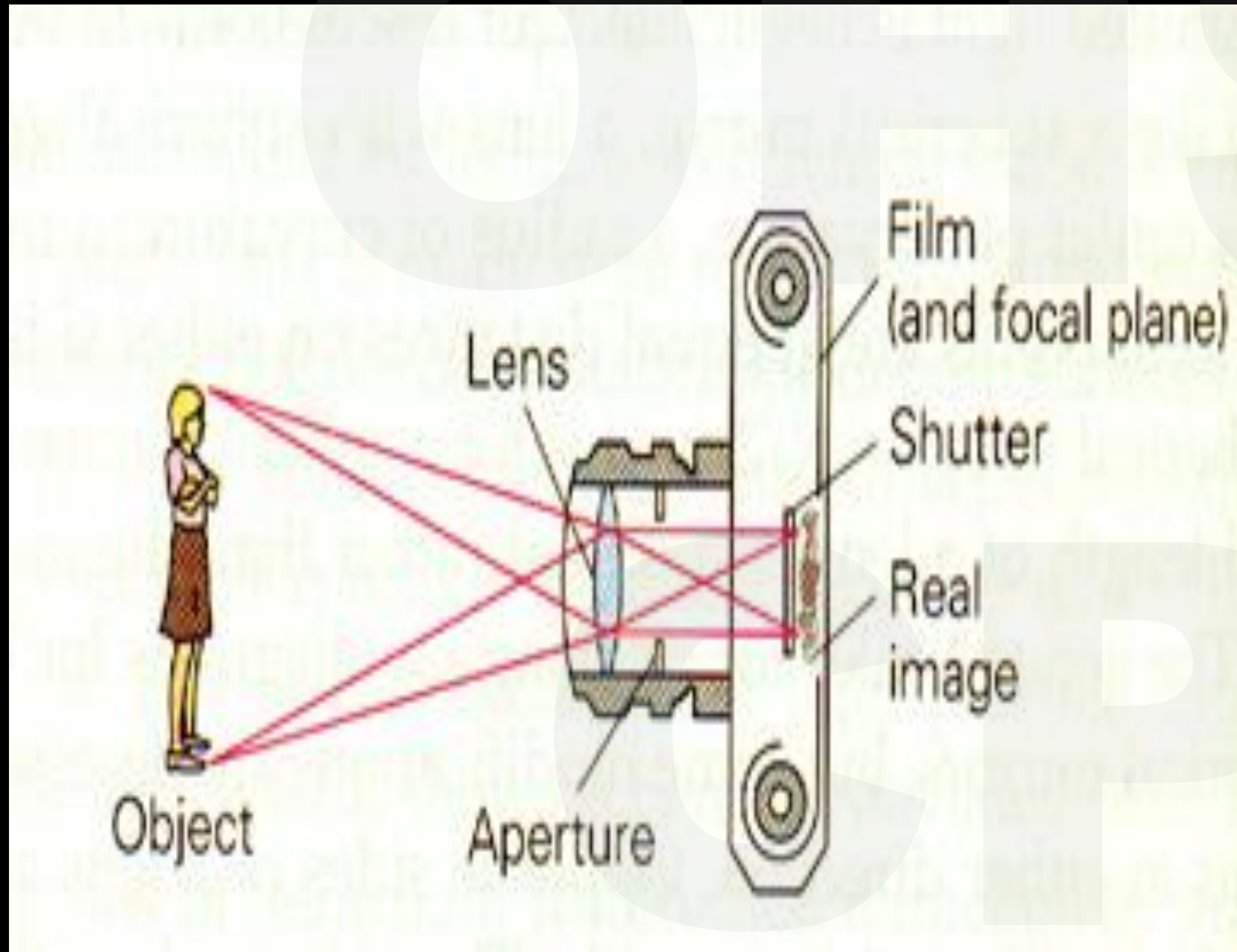
# Leading Causes of Blindness

CAUSES OF BLINDNESS WORLDWIDE IN PERCENTAGE

- Leading causes of blindness worldwide
- ~15 million in age 50 or older in 2020
- ~80 million with vision impairment
  - 20/60 - 20/400
- State of Oregon: 4.26 million (2021)



# A quick eye anatomy review



# History

- Blurry vision
- Painful eye
- Red eye

OHSU

CPD

# Age-related Macular Degeneration (AMD)

## Presentation

- Asymptomatic until certain threshold is reached
- Blurred or distorted central vision
  - Difficulty recognizing faces
  - Difficulty reading or seeing fine details
  - Difficulty watching TV



# Risk Factors

- Age

- Genes (Fhx, Caucasians, gene mutations, etc.)

- Smoking

- HTN

- Hyperlipidemia

- Obesity

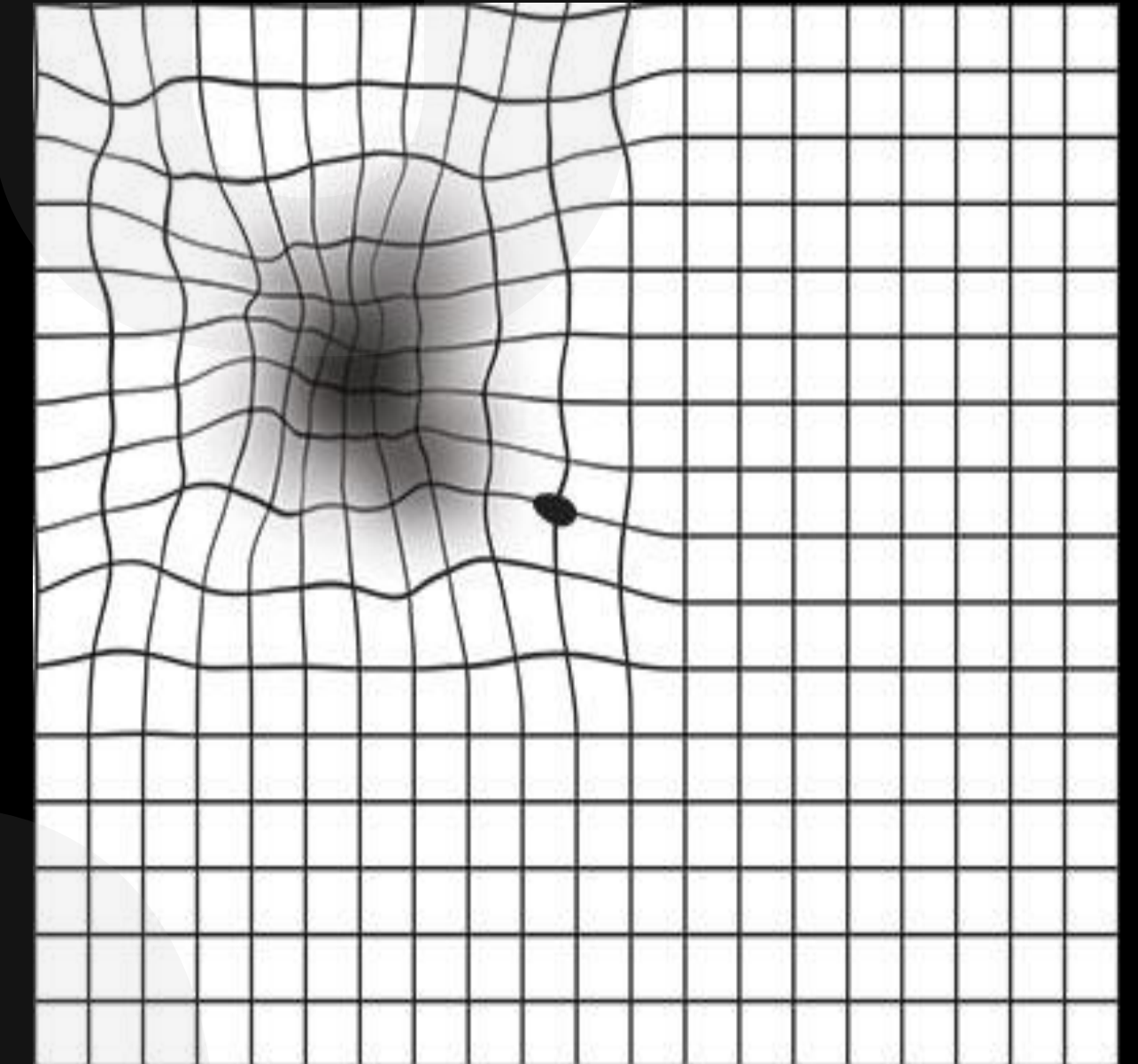
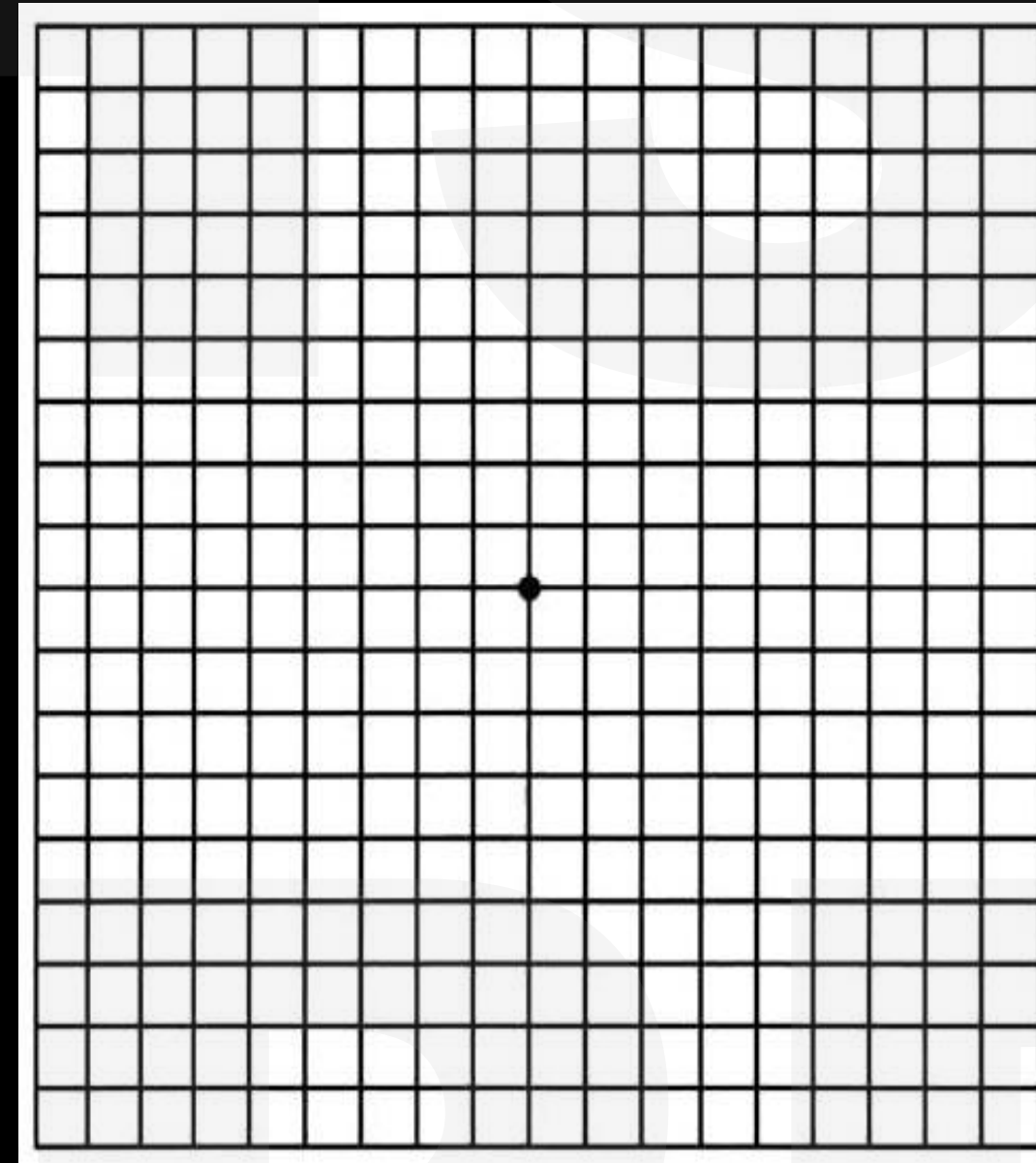
- Diet

OHSU

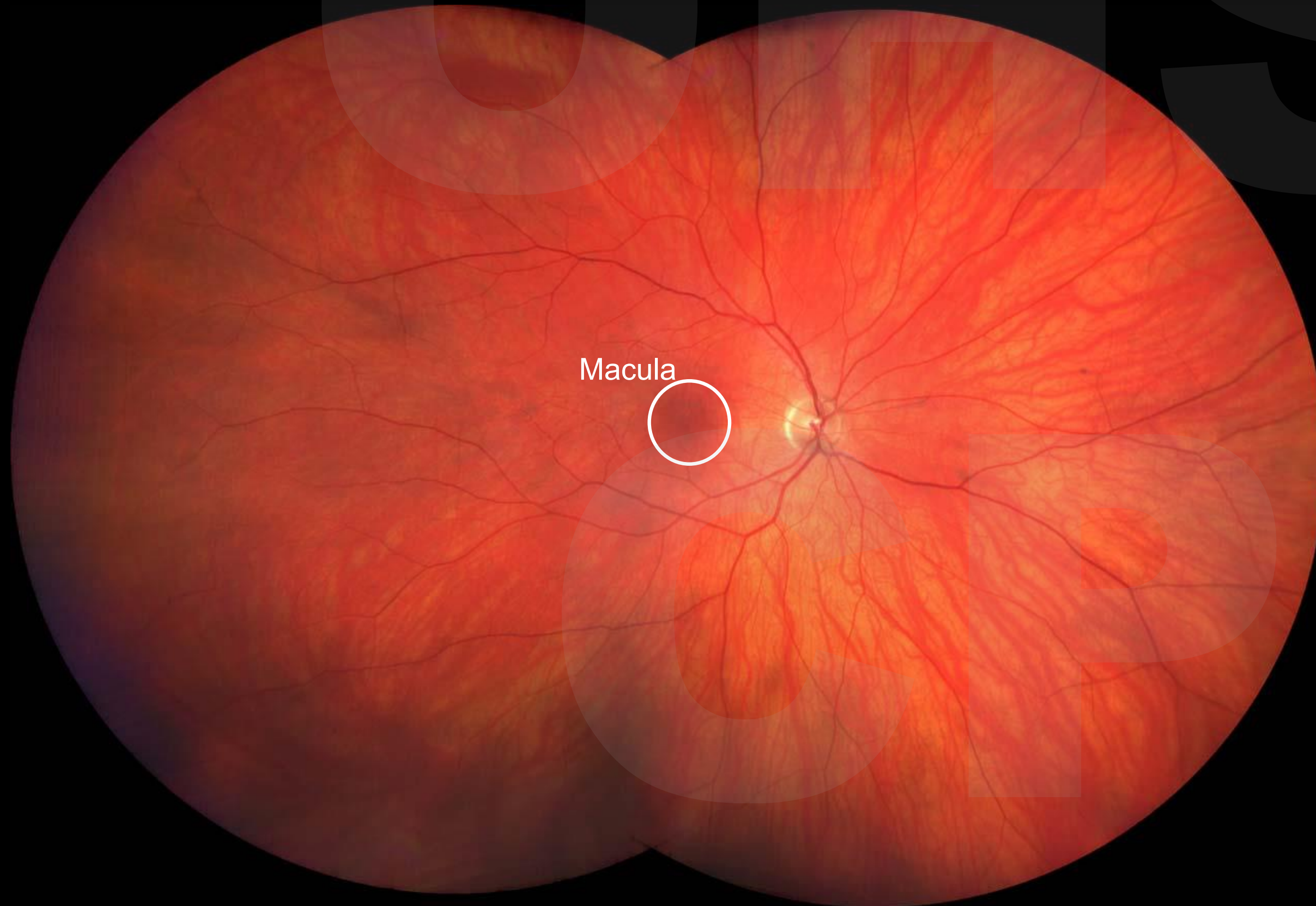
CPD

# Dx

- Comprehensive eye examination
- Visual acuity test
- **Amsler grid test**
- Optical coherence tomography (OCT)
- Angiogram (FA or OCTA)



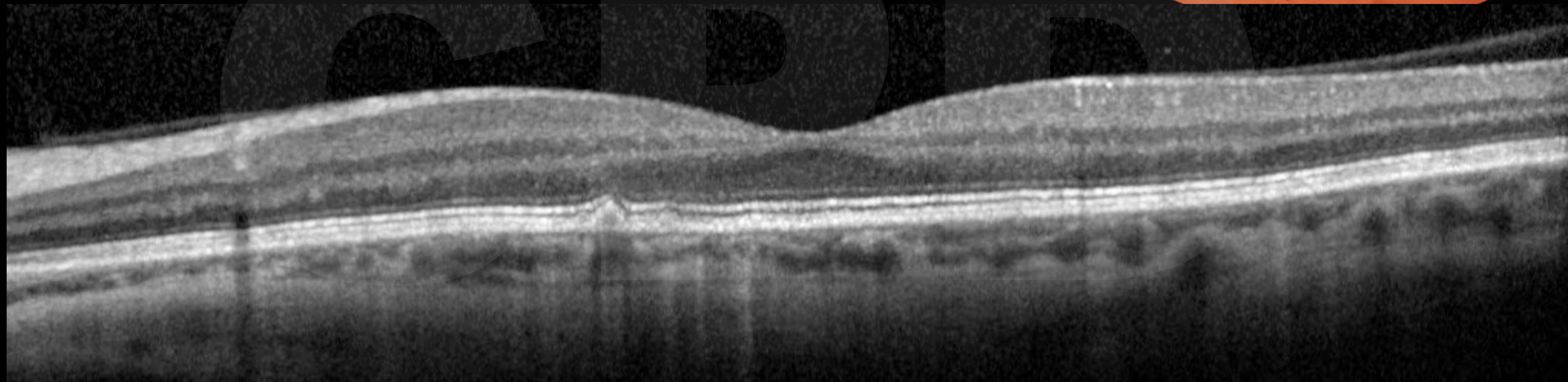
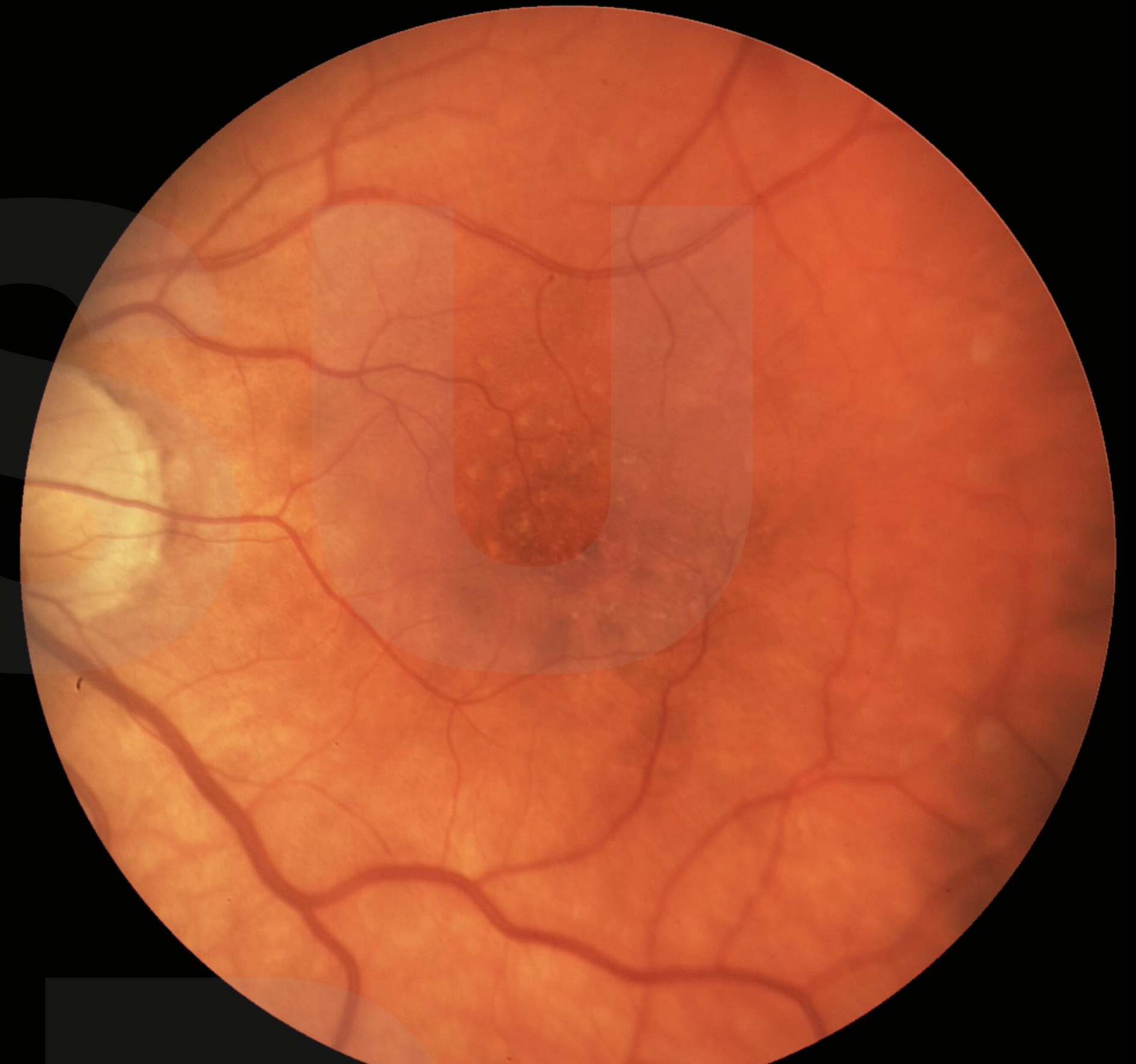# What is the macula?



- Responsible for the central, fine vision
- Crucial for reading, recognizing faces, and qualifying for a driver's license

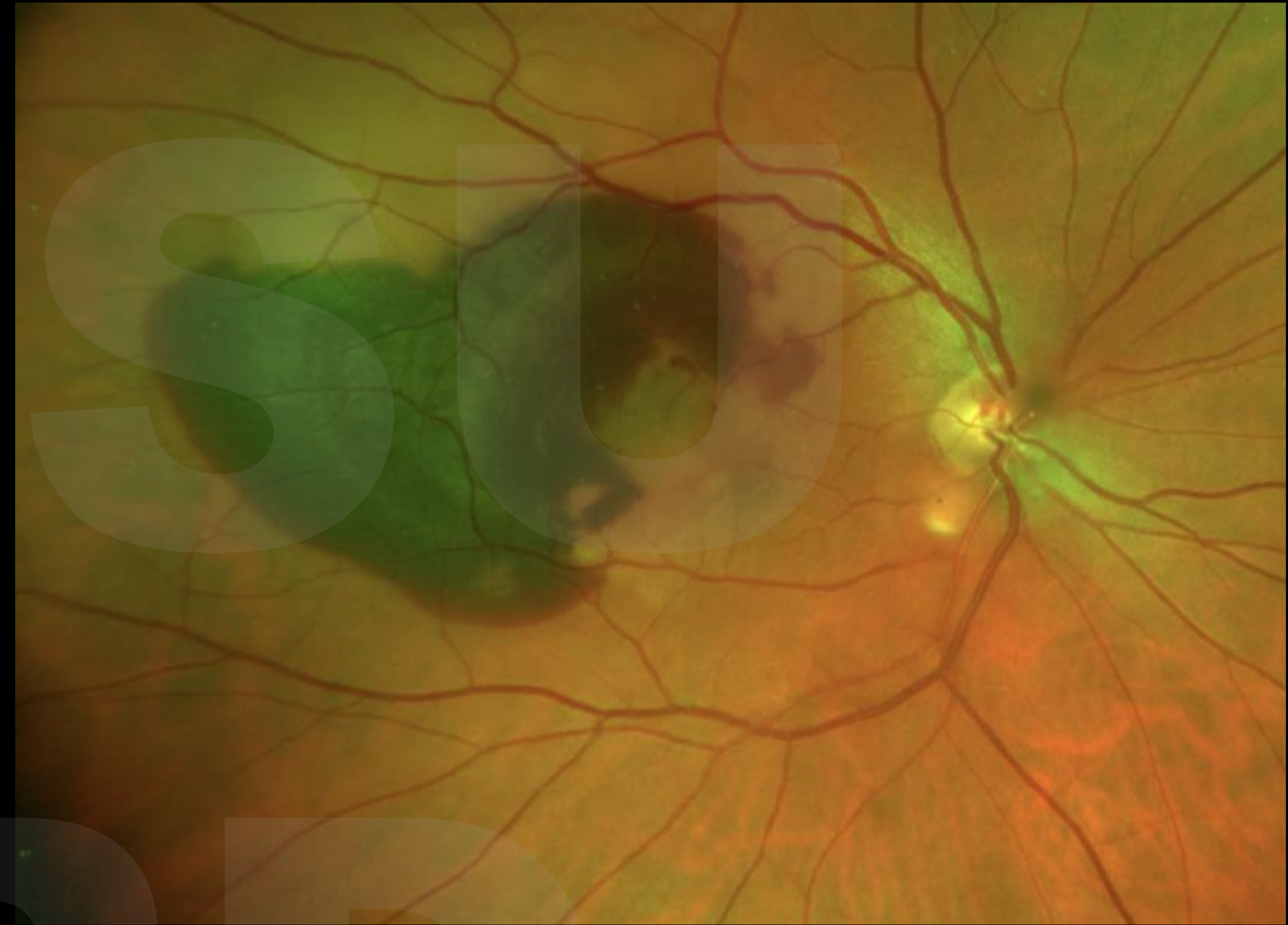
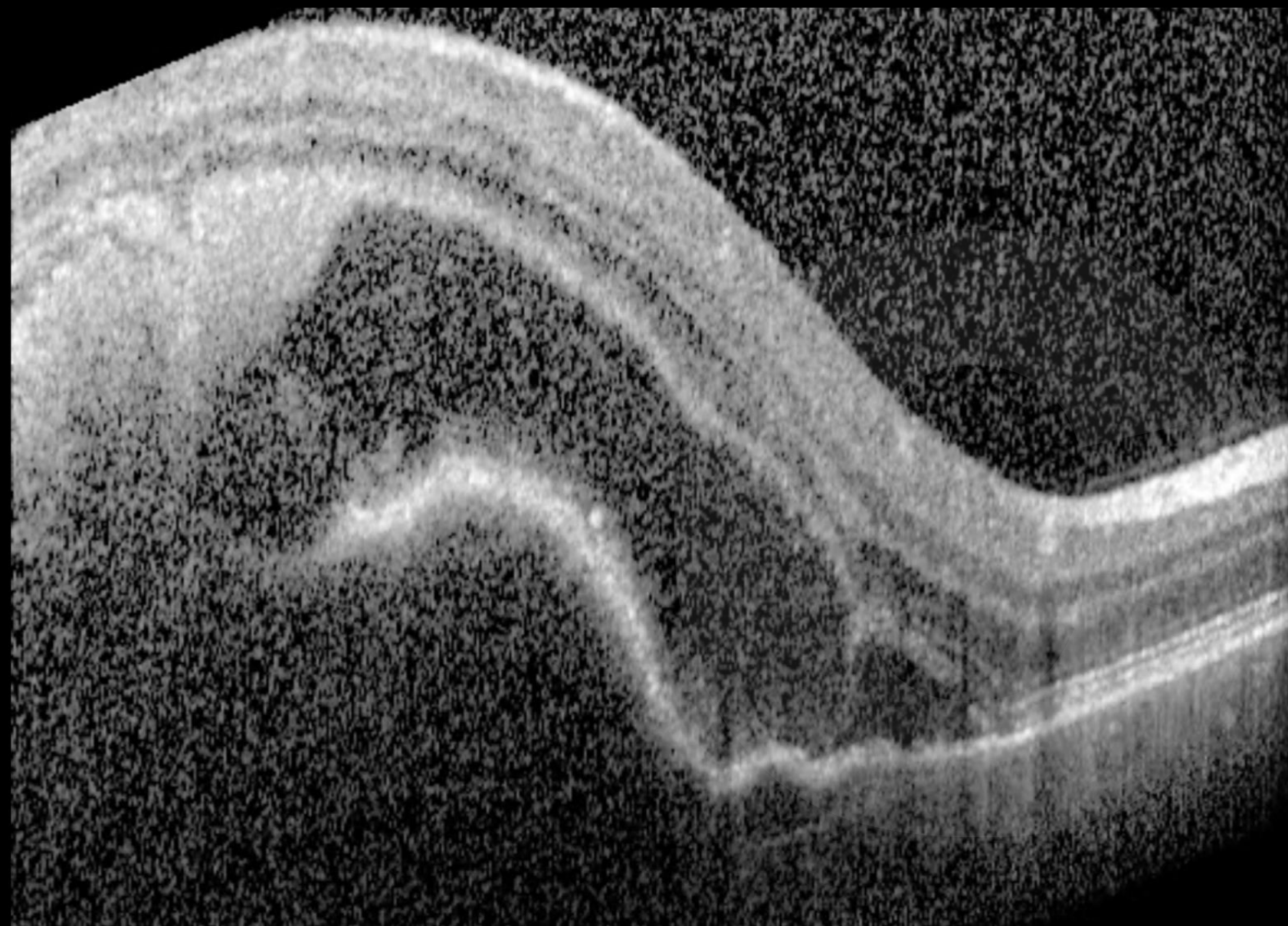
# Case #1

- 67 year old woman with family history of AMD and 20/20 vision in both eyes for routine eye examination and this on the fundus examination:



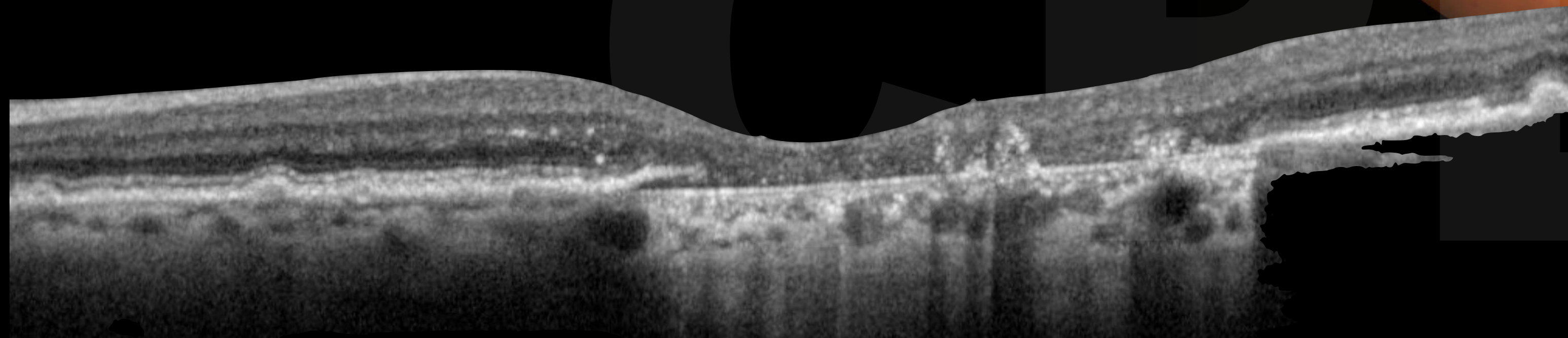
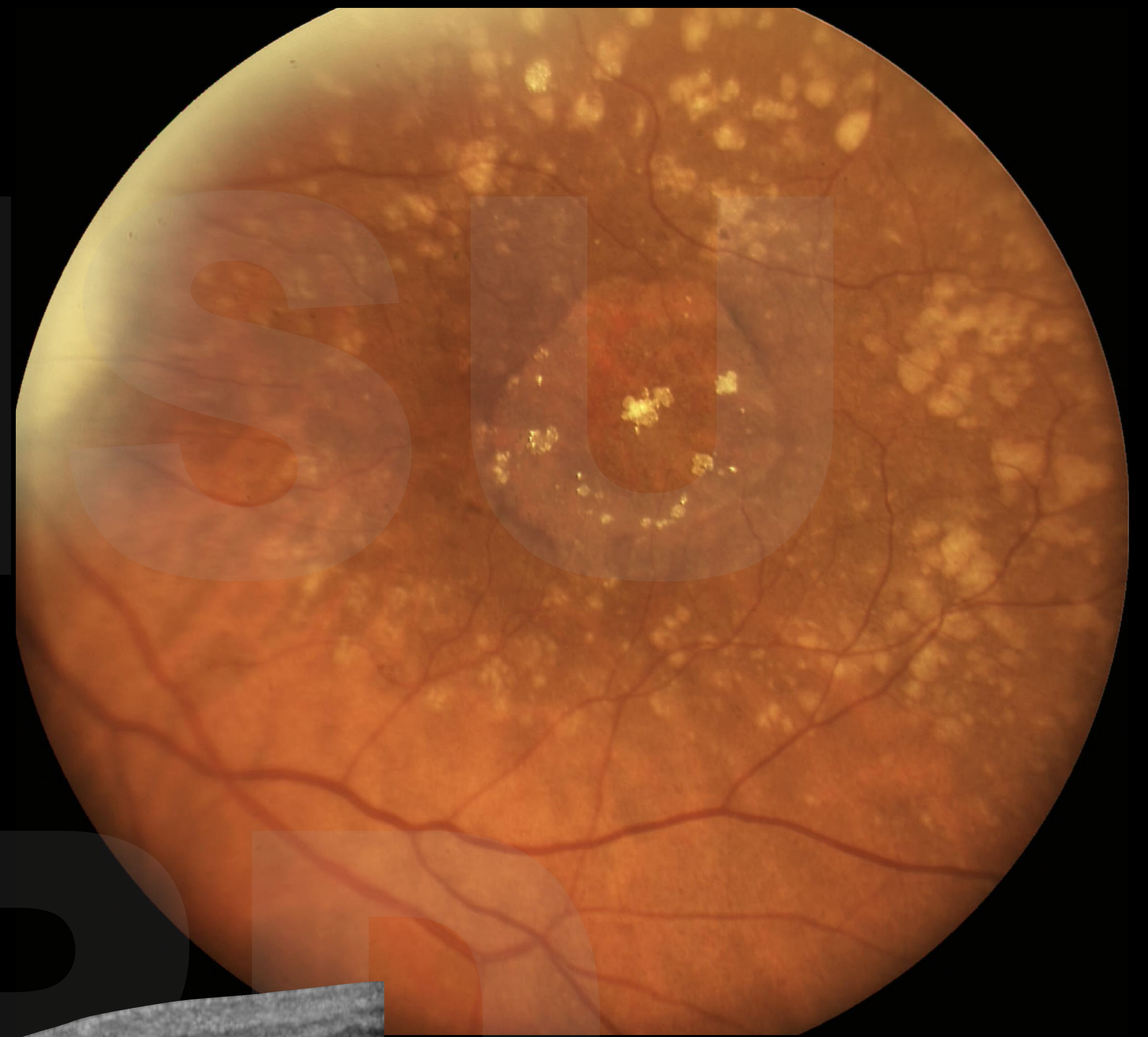
# Case #2

- 75 year old man with new distortion in vision in the right eye and 20/100 vision



# Case #3

- 76 year old woman with slow decrease in vision to 20/100 level

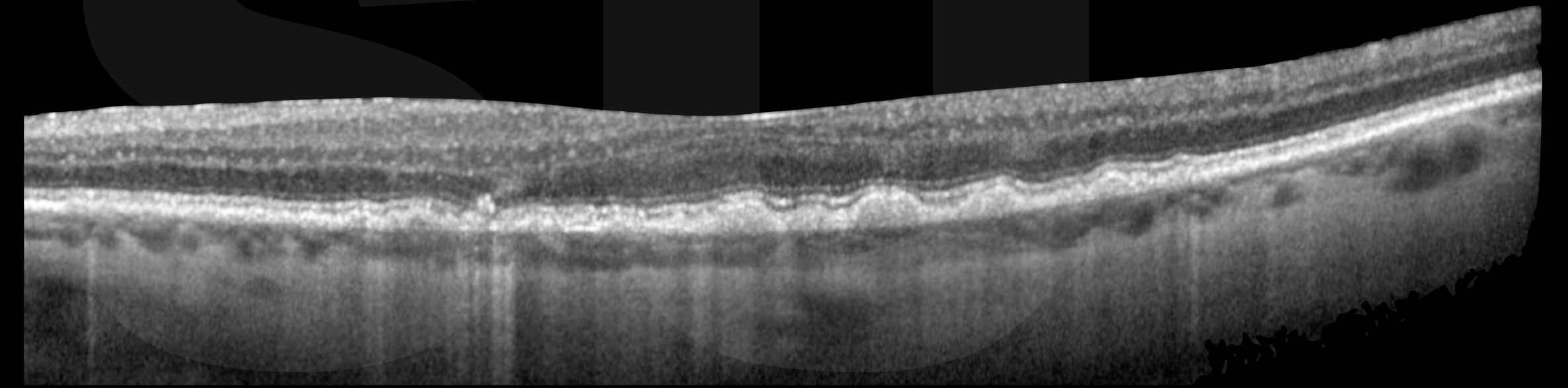
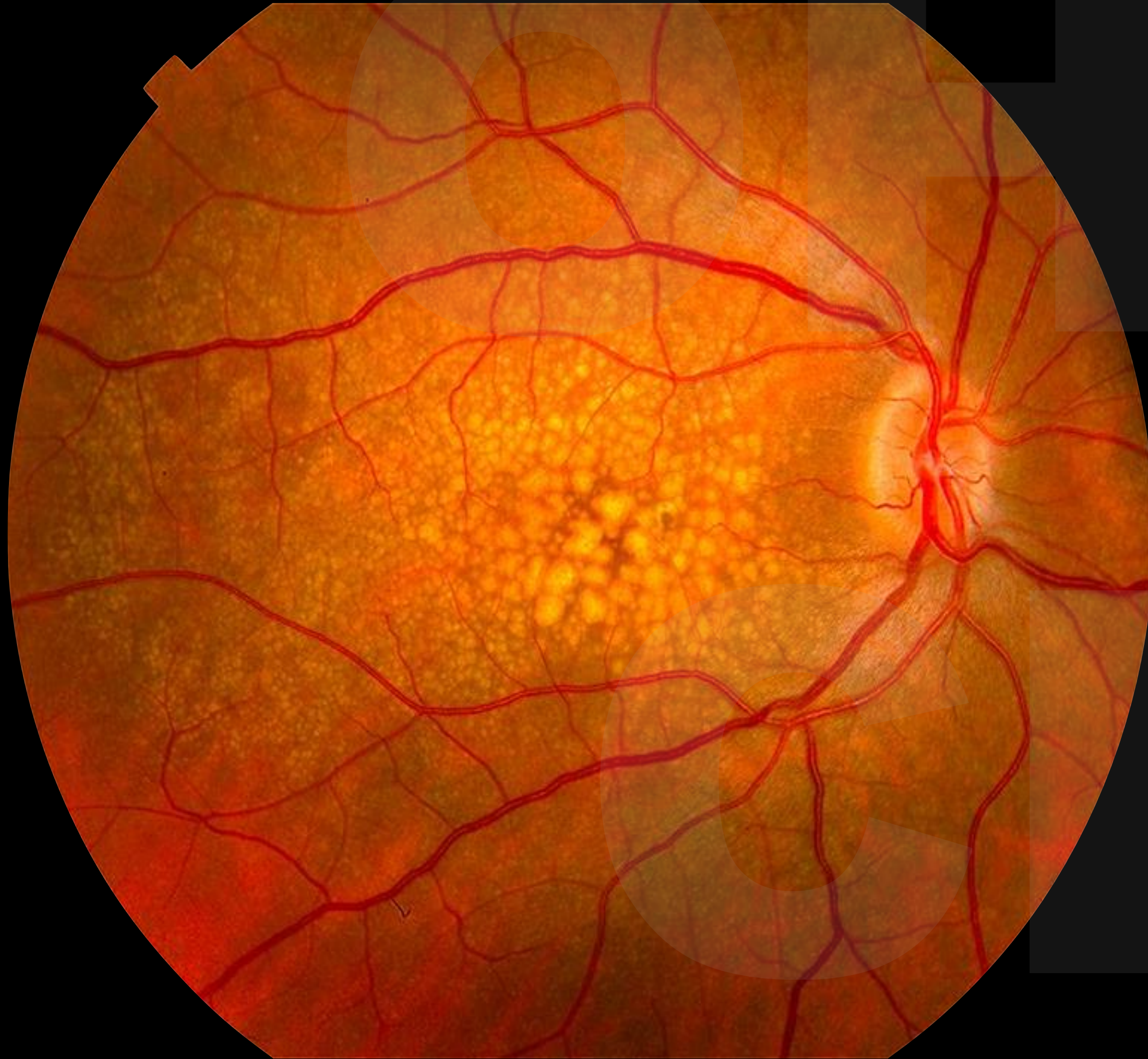

# Vision loss related to macular disease isn't total

- Peripheral vision is spared
- Even those who are legally blind from AMD typically retain the ability to ambulate independently



# Drusen



- These yellow deposits under the retina are the hallmark of AMD
- These don't cause vision loss by themselves, but their presence predicts increased risk of progression to "advanced AMD"

# Advanced AMD

Wet

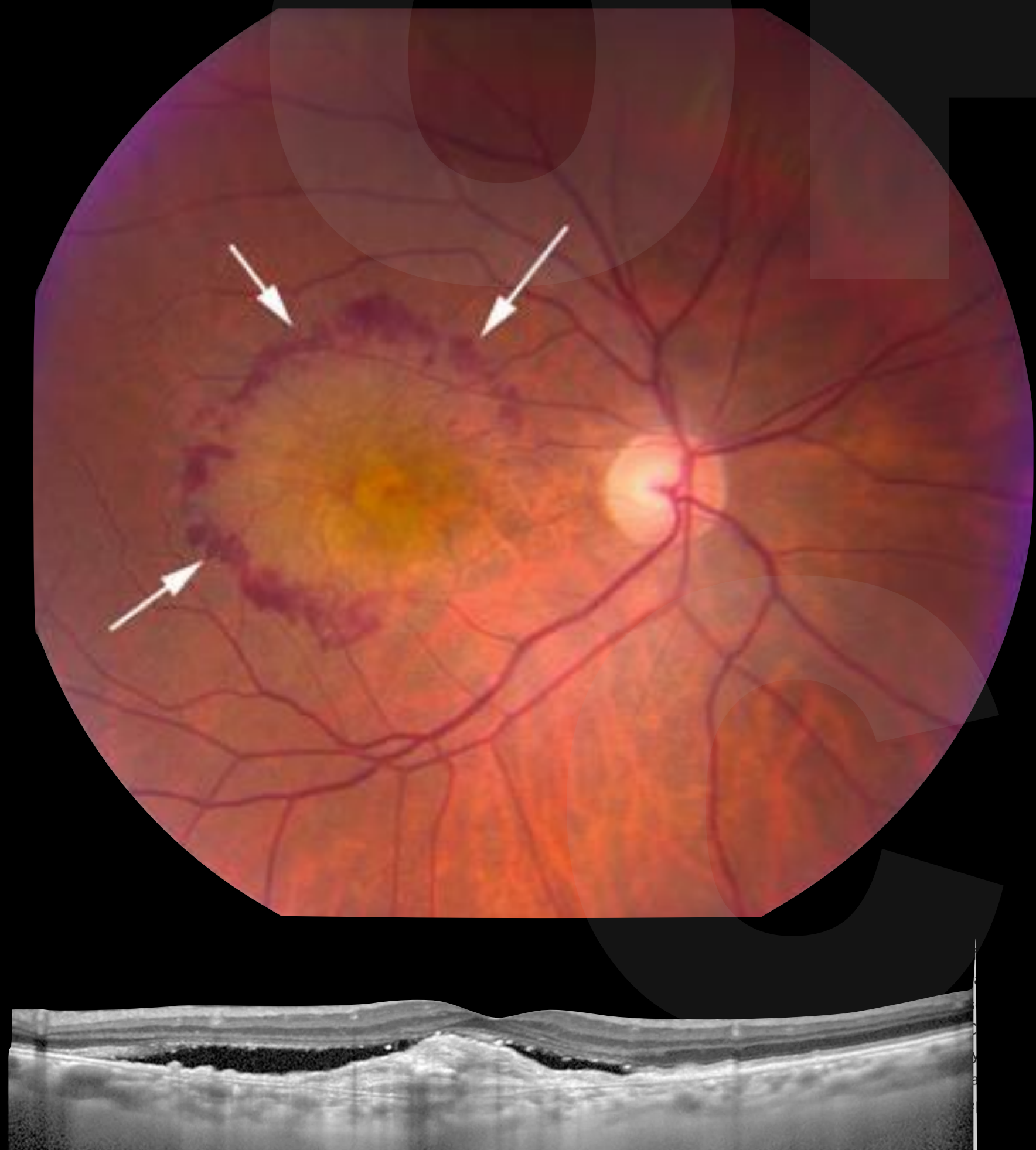

Dry

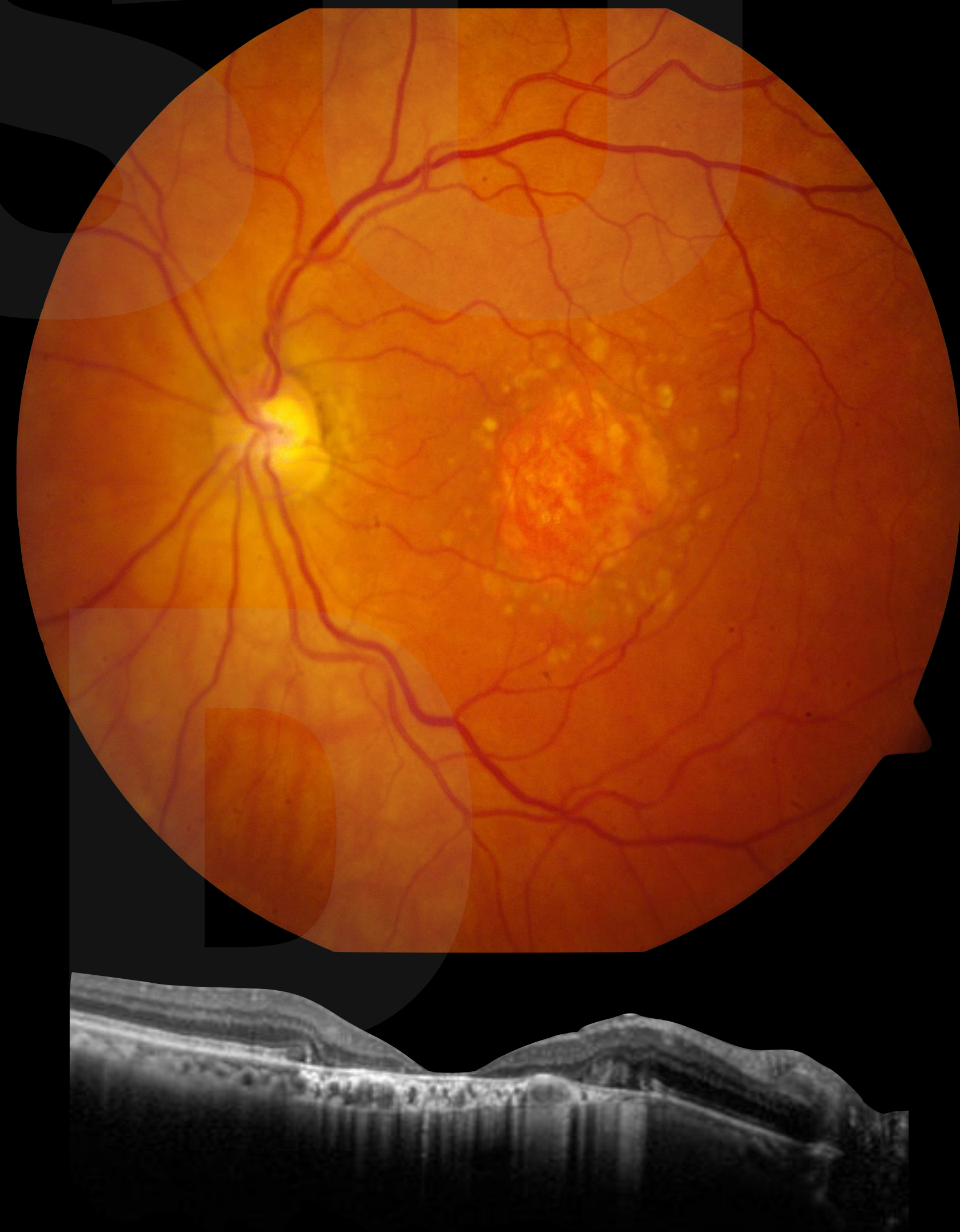

# Advanced AMD

Wet



Dry



# AMD Road Map

## Early AMD

Small Drusen

Common



## Intermediate AMD

Large Drusen

Or

Lots of intermediate size drusen

Less Common

12%

6%

## Wet AMD

Abnormal Blood Vessels

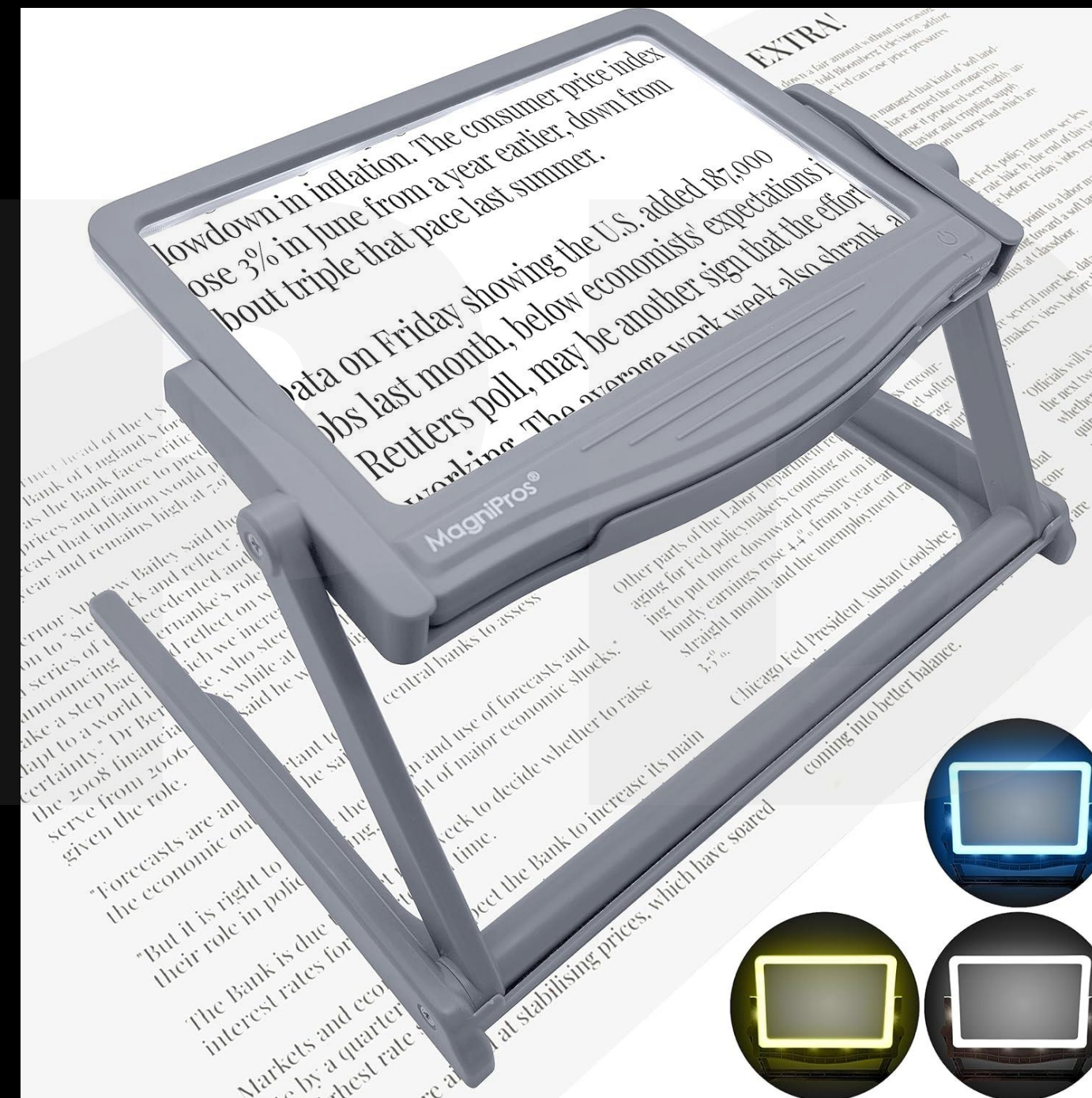## Advanced Dry AMD

## Dry AMD

Geographic Atrophy

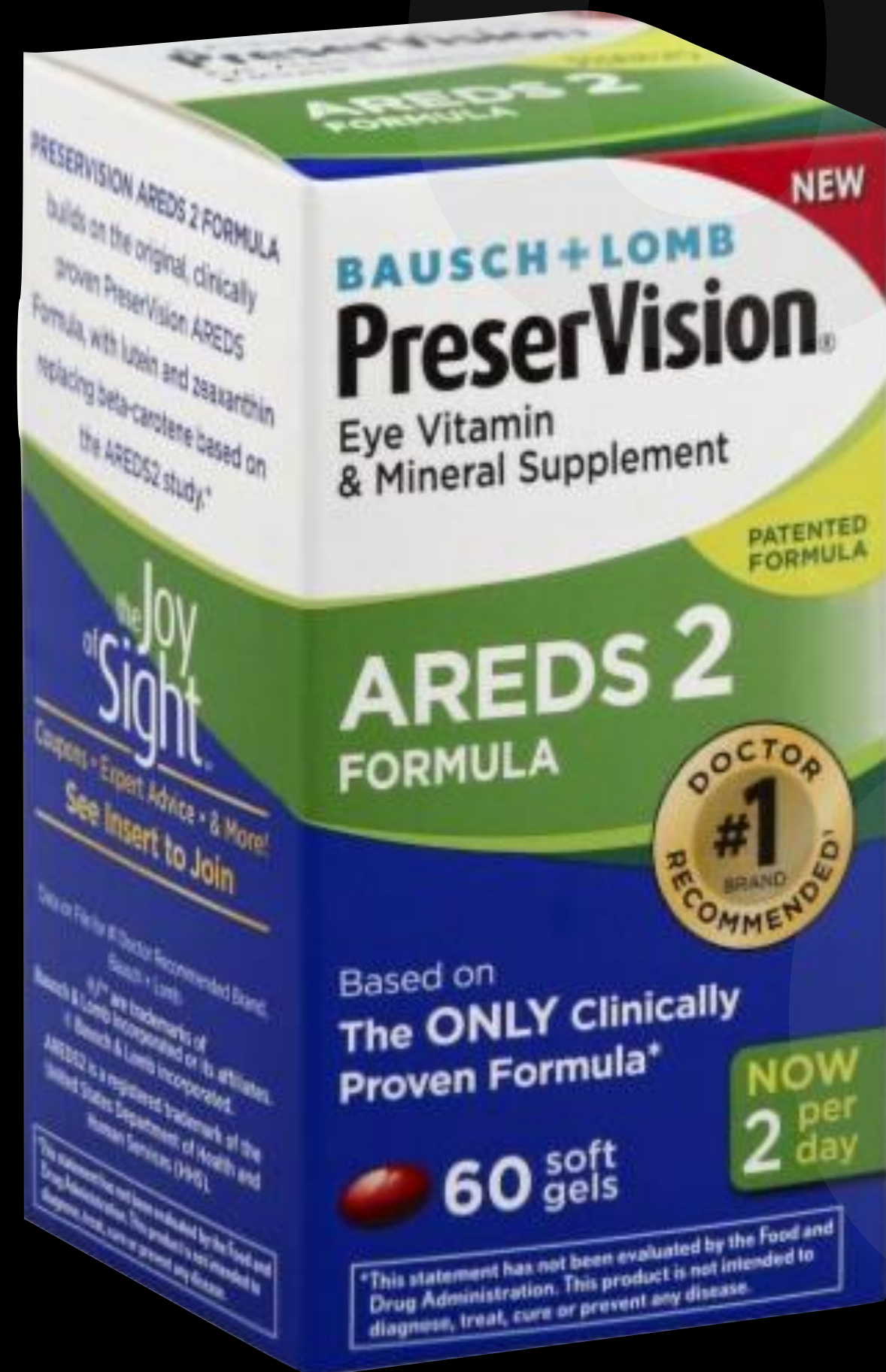
# Management

- Dry AMD: lifestyle changes, nutritional supplements (AREDS2 formula)
- Wet AMD: anti-VEGF injections, (photodynamic therapy)
- Low vision aids: magnifying devices, special glasses, big tablet
- Regular f/u exam



# Intermediate AMD

AREDS Supplement lowers risk of wet AMD



Intermediate  
AMD

Large Drusen

Or

Lots of intermediate size  
drusen

Less Common

Reduce  
by 25%

Wet AMD

Abnormal Blood Vessels

Vision loss!

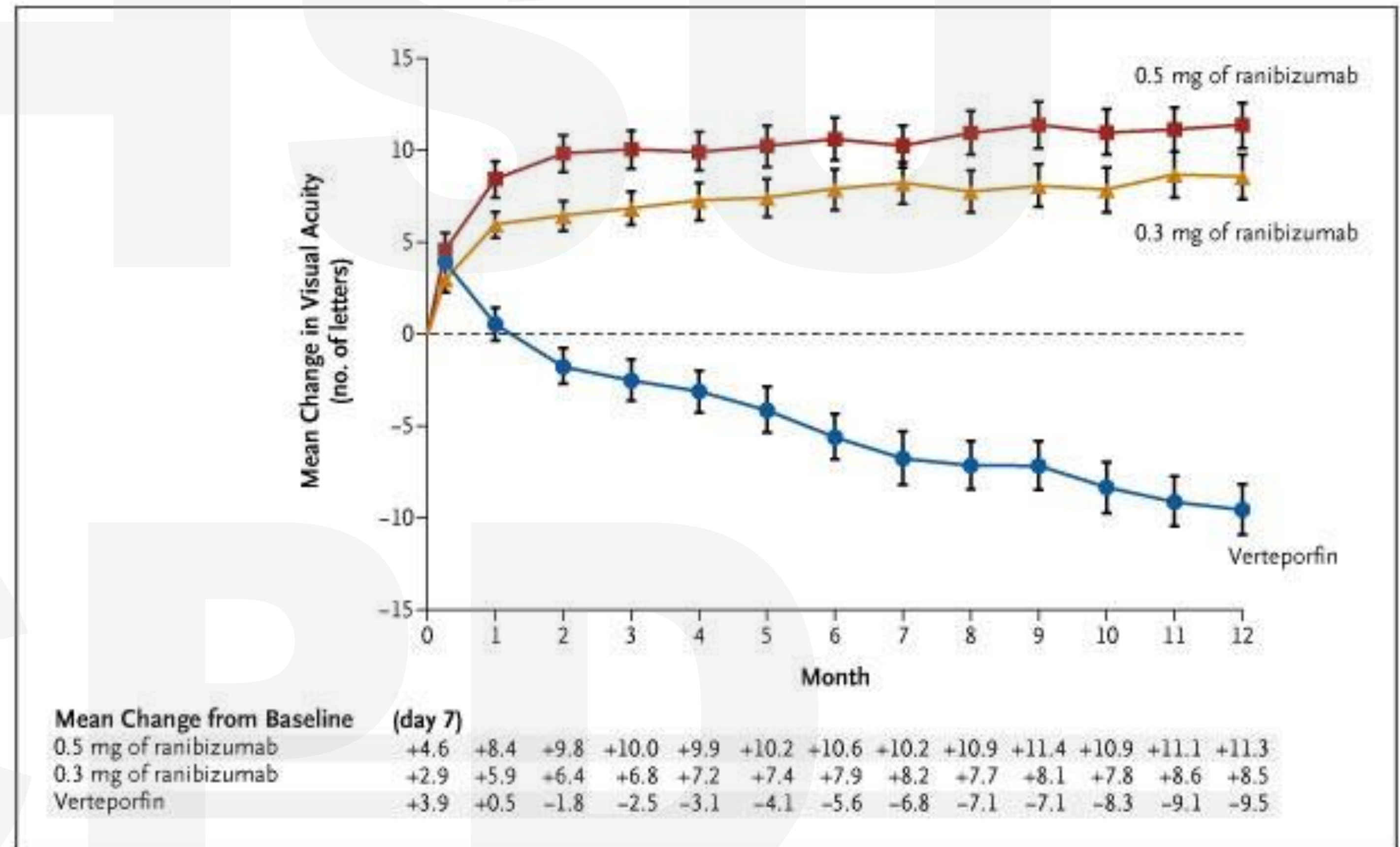
Advanced

Dry AMD

Geographic Atrophy

# What do we do for wet macular degeneration?

- Anti-VEGF (vascular endothelial growth factor) injections into the vitreous cavity
  - 90% without significant vision loss at 2 years
  - On average, the treatment results in gain in visual acuity
  - Requires repeated, and often indefinite treatment

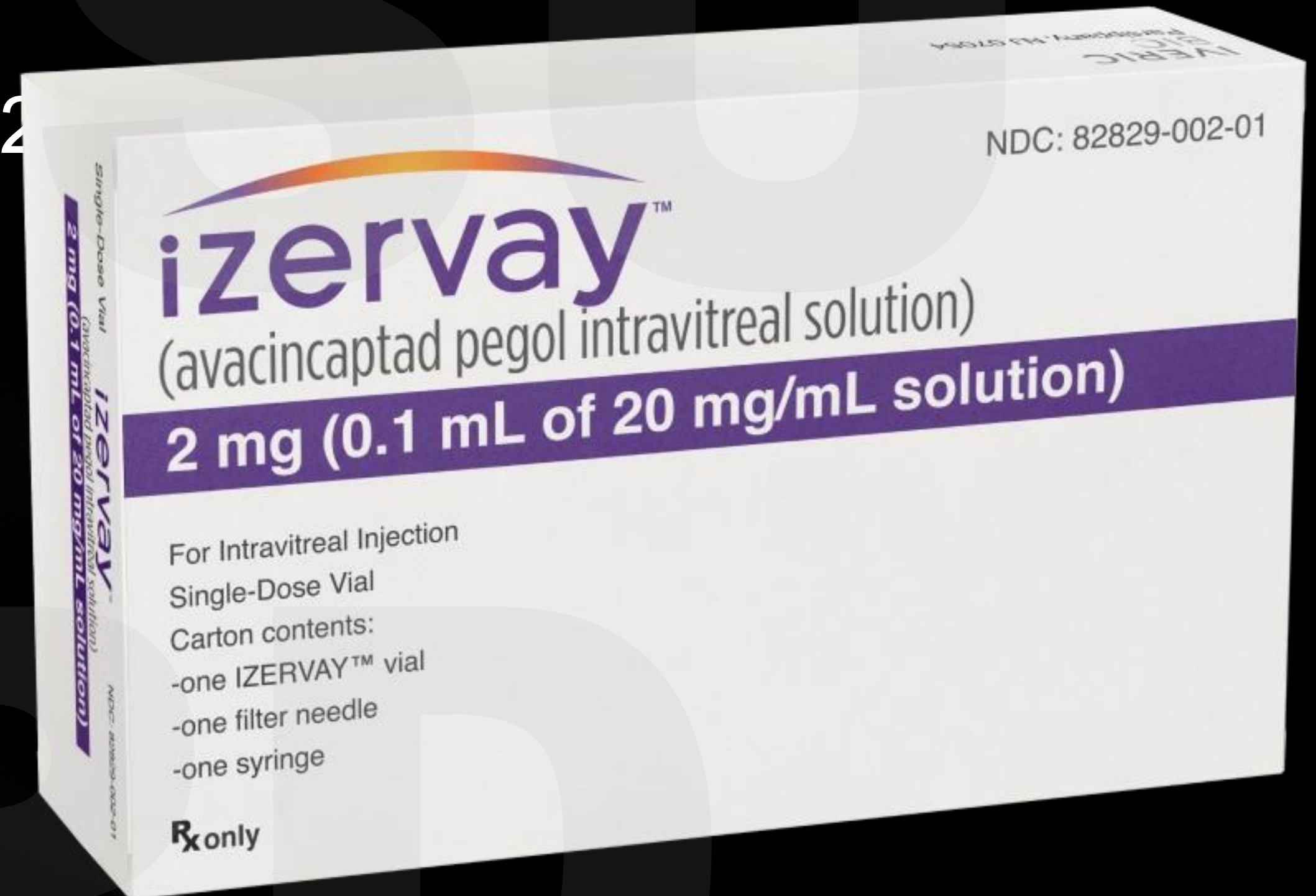
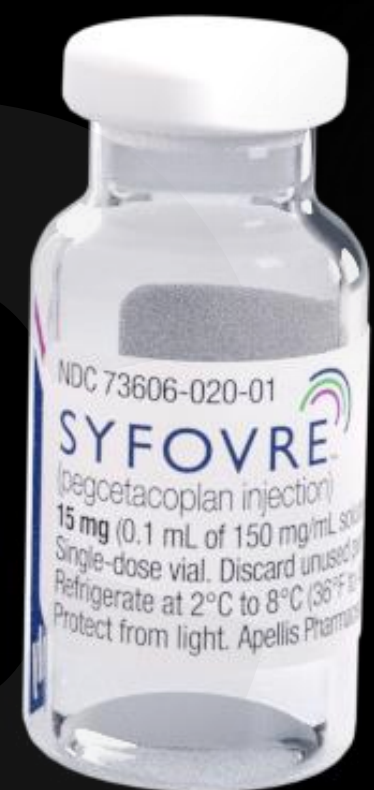
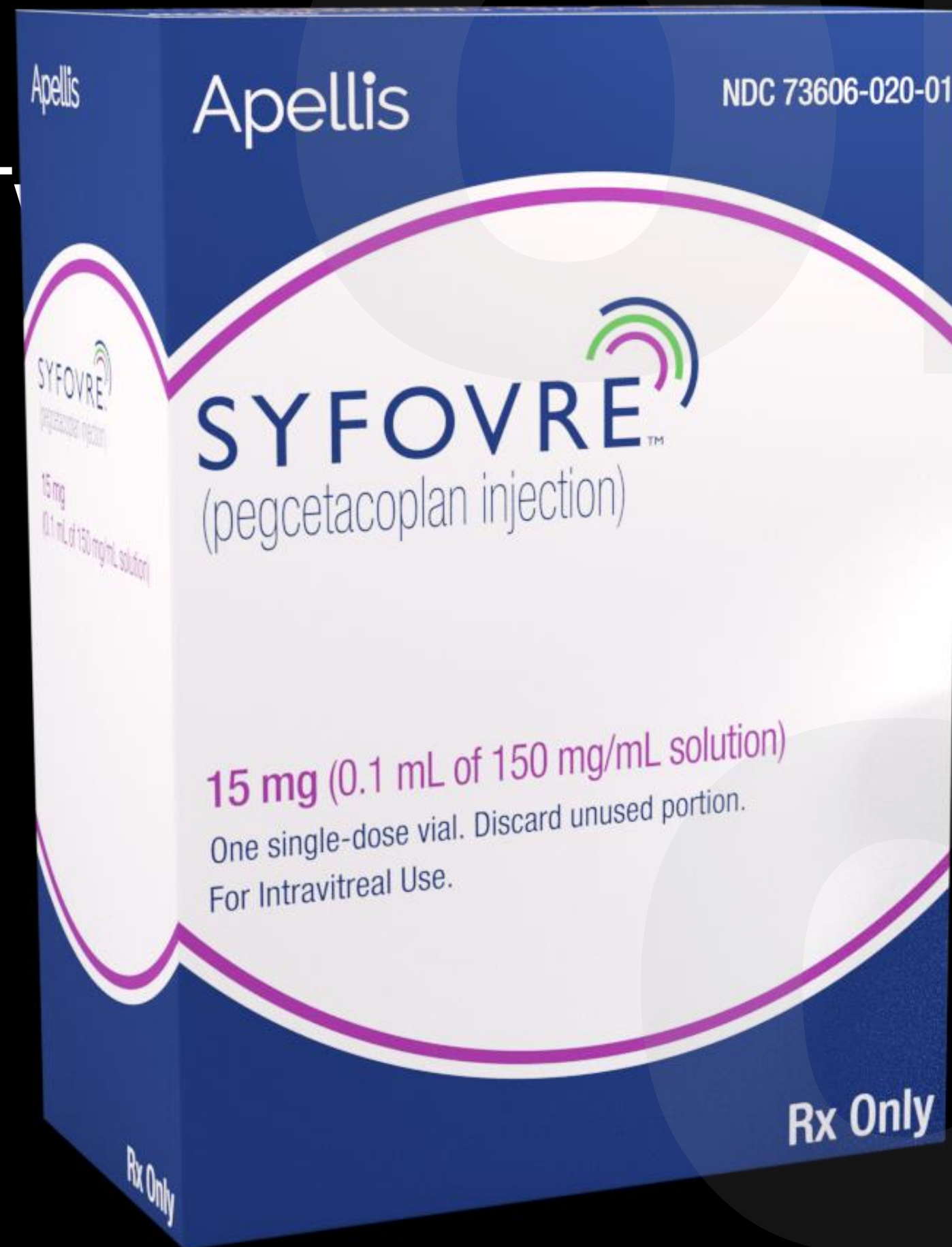
# For Geographic Atrophy. . .

- Two drugs that were FDA approved in 2023

# For GA...

- T... approved in 2...



# Reduces the growth of lesion but

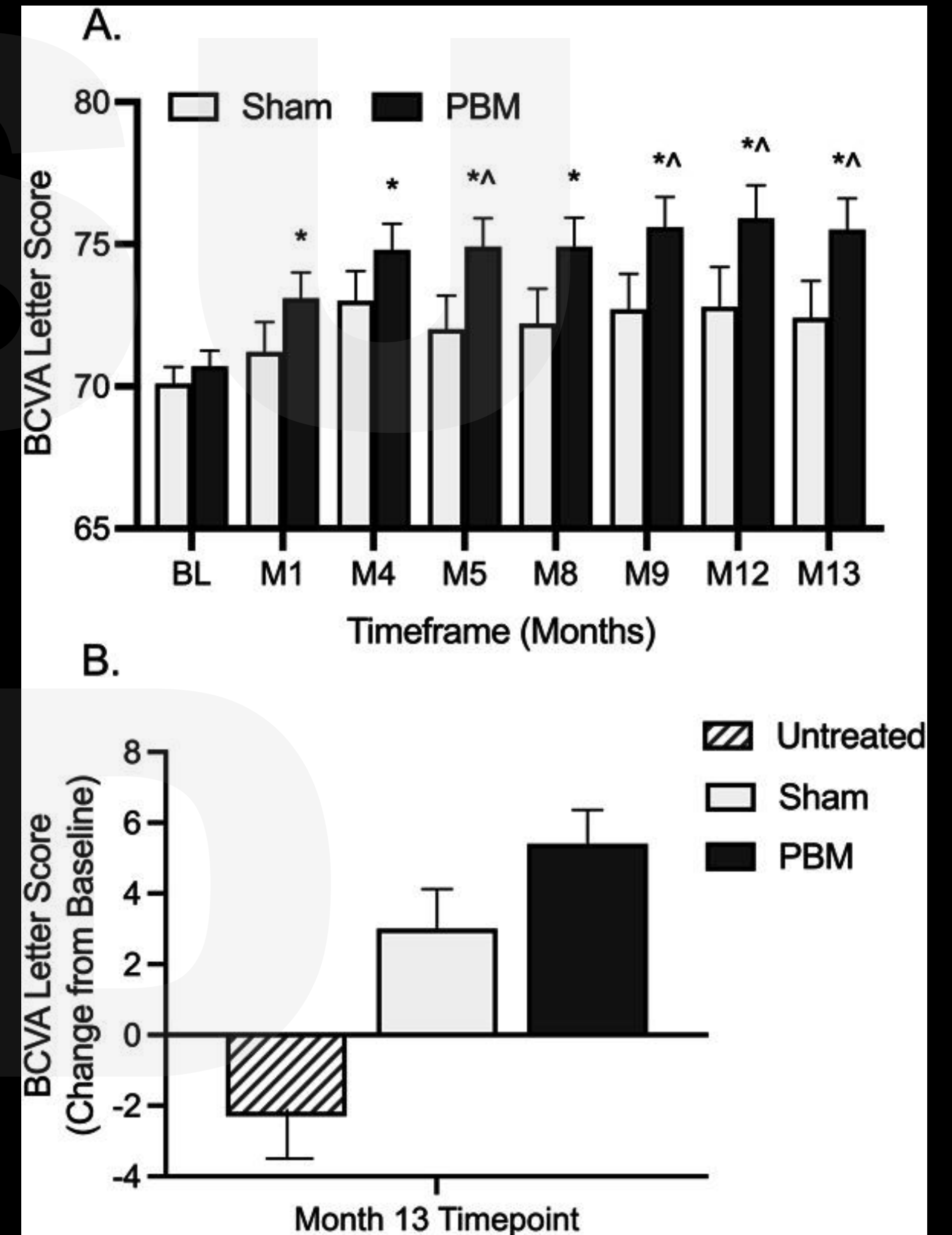
- No difference in vision, reading speed, or contrast sensitivity
- Some safety concerns
- Increases risk of wet macular degeneration

# PBM

- LIGHTSIGHT III
- PBM: yellow (590 nm; 4 mW/cm<sup>2</sup>; 2× 35 seconds), red (660 nm; 65 mW/cm<sup>2</sup>; 2× 90 seconds), and NIR (850 nm; 0.6 mW/cm<sup>2</sup>; 2× 35 seconds)
- Sham: 50x reduction of the 590 nm and a 100x reduction of the 660 nm. 850 nm was omitted
- Sunlight is about ~1000 mW/cm<sup>2</sup> at midday high noon
- Enrolled 100 pt with early-intermediate nonexudative (dry) age-related macular degenerati

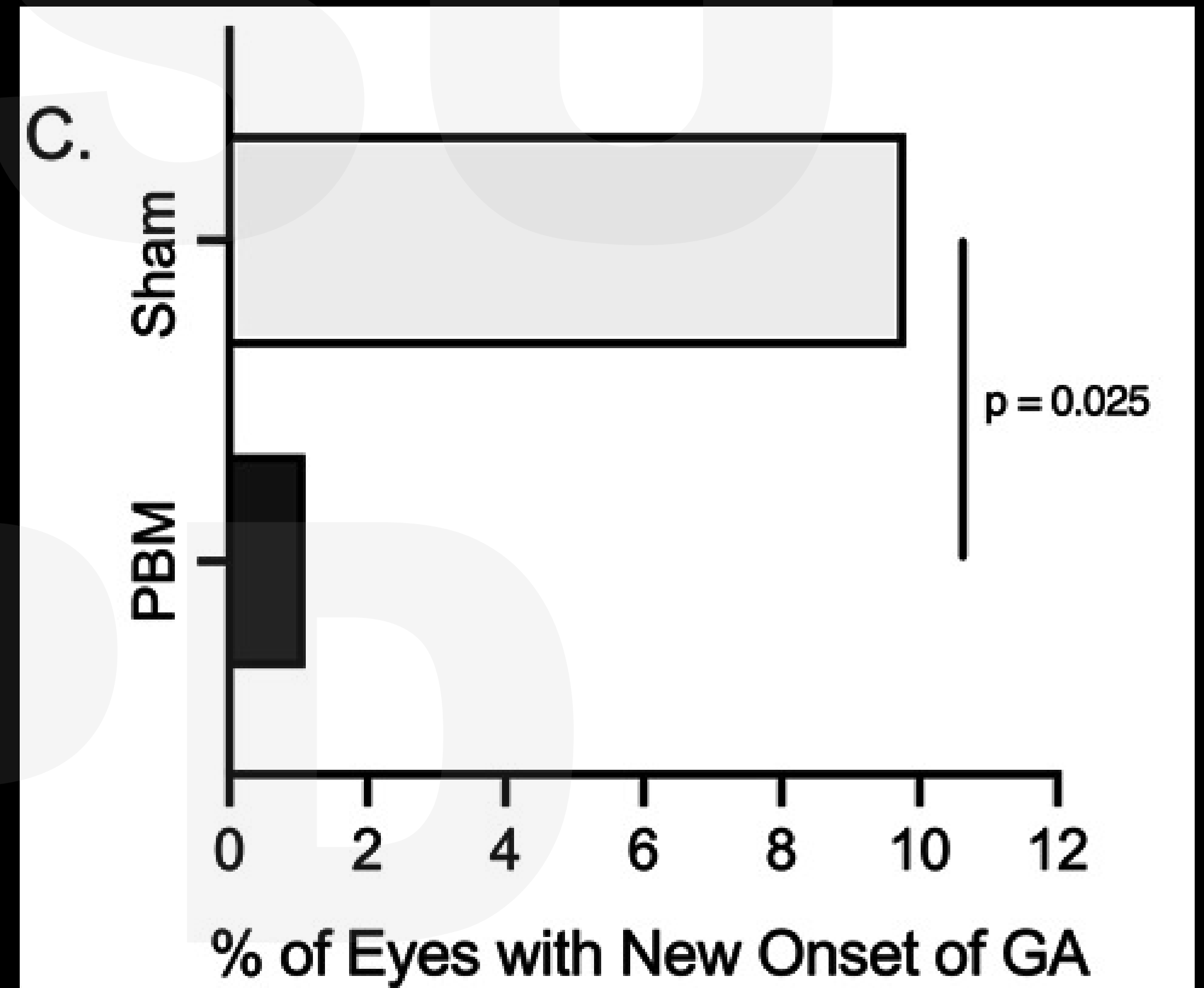
# LIGHTSIGHT III

- Both groups had improvement in VA, compared to untreated eye
- At Month 13, nonstudy eyes showed a mean letter loss of 2.3 letters, Sham-treated eyes showed a mean letter gain of 3.0 letters, and PBM-treated eyes showed a mean letter gain of 5.4 letters ( $p < 0.005$ )



# LIGHTSIGHT III

- The occurrence of new GA was significantly higher in the Sham versus PBM group ( $P = 0.024$ , Fisher exact test, odds ratio 9.4)
- A total of 10.0% ( $n = 5/50$ ) of new-onset GA events were observed in Sham eyes compared to in Sham, and 1.1% ( $n = 1/87$ ) observed in PBM-treated eyes.



# Diabetic Retinopathy

## Speed dating style

- Usually billed as “the most important cause of vision loss in working-age adults” also affects older adults, with increasing risk with older age

# Presentation

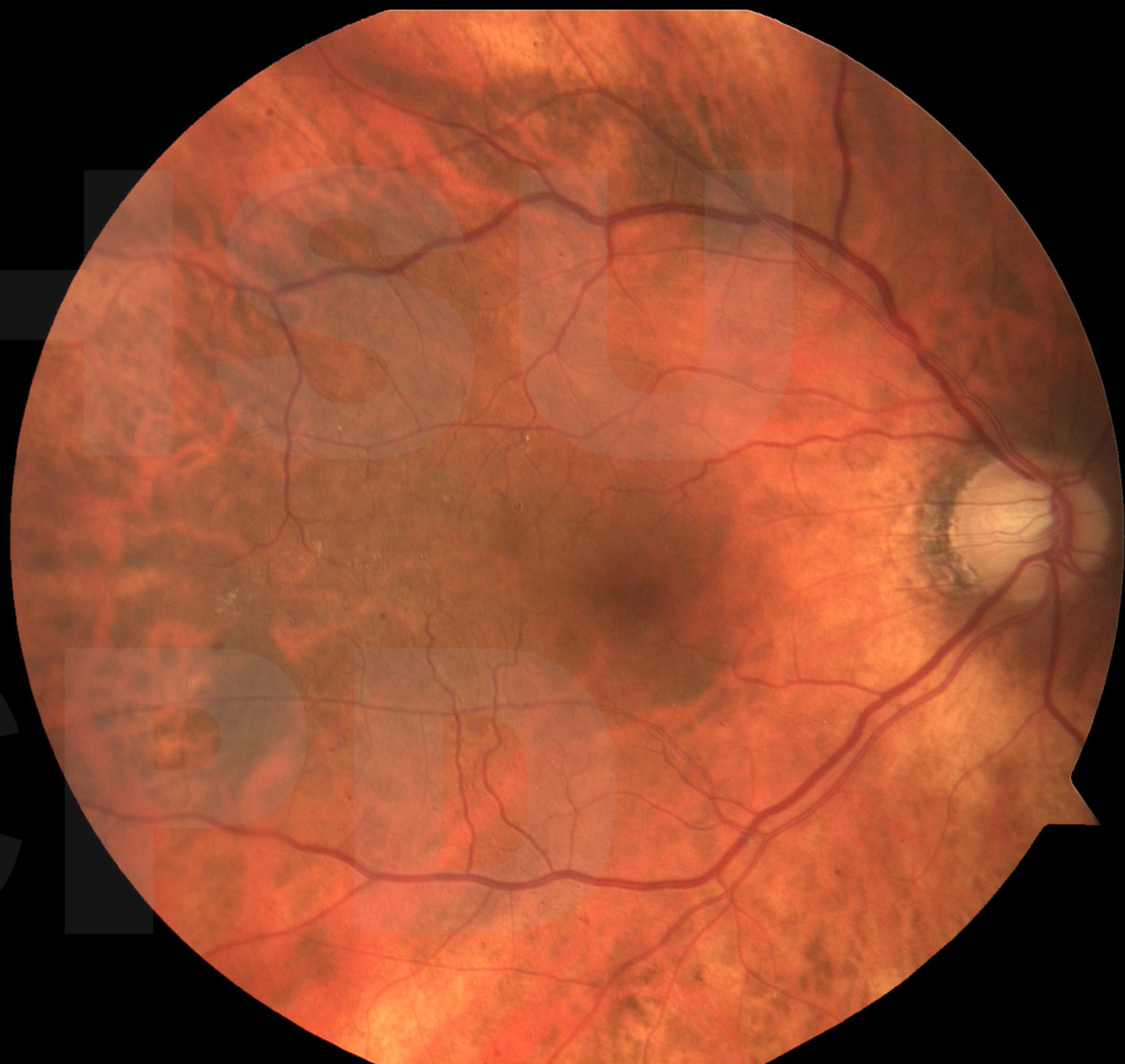- Asymptomatic until certain threshold is reached
- Blurred vision
- Poor night vision
- **Floaters or dark spots in vision**

# Risk Factors

- Diabetes
  - Duration of diabetes – hence age
  - Poor blood sugar control
- HTN
- Hyperlipidemia
- Smoking
- Kidney disease

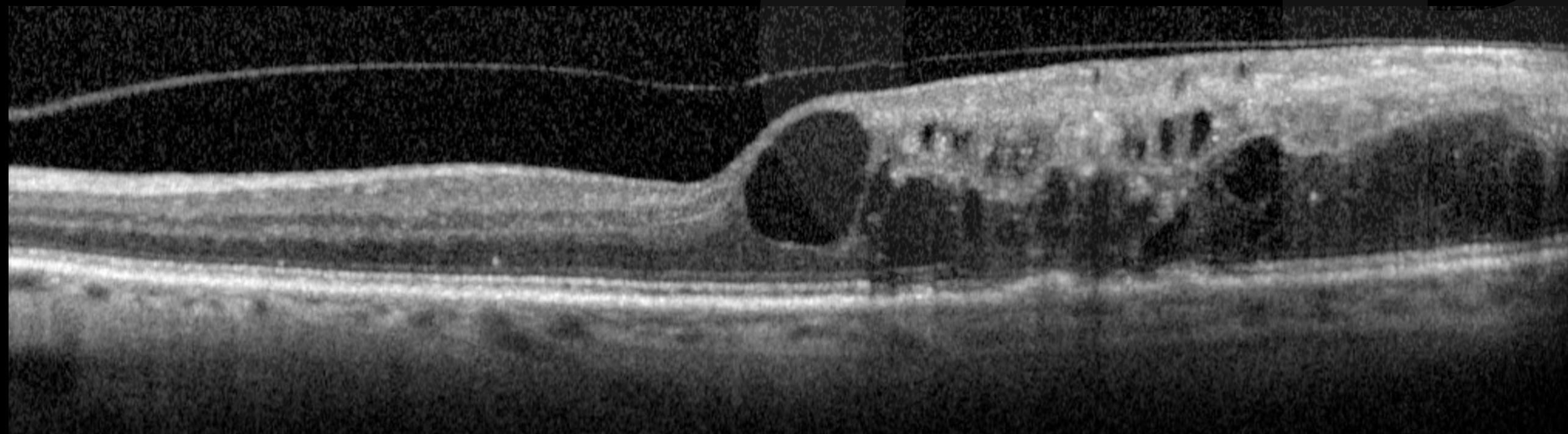
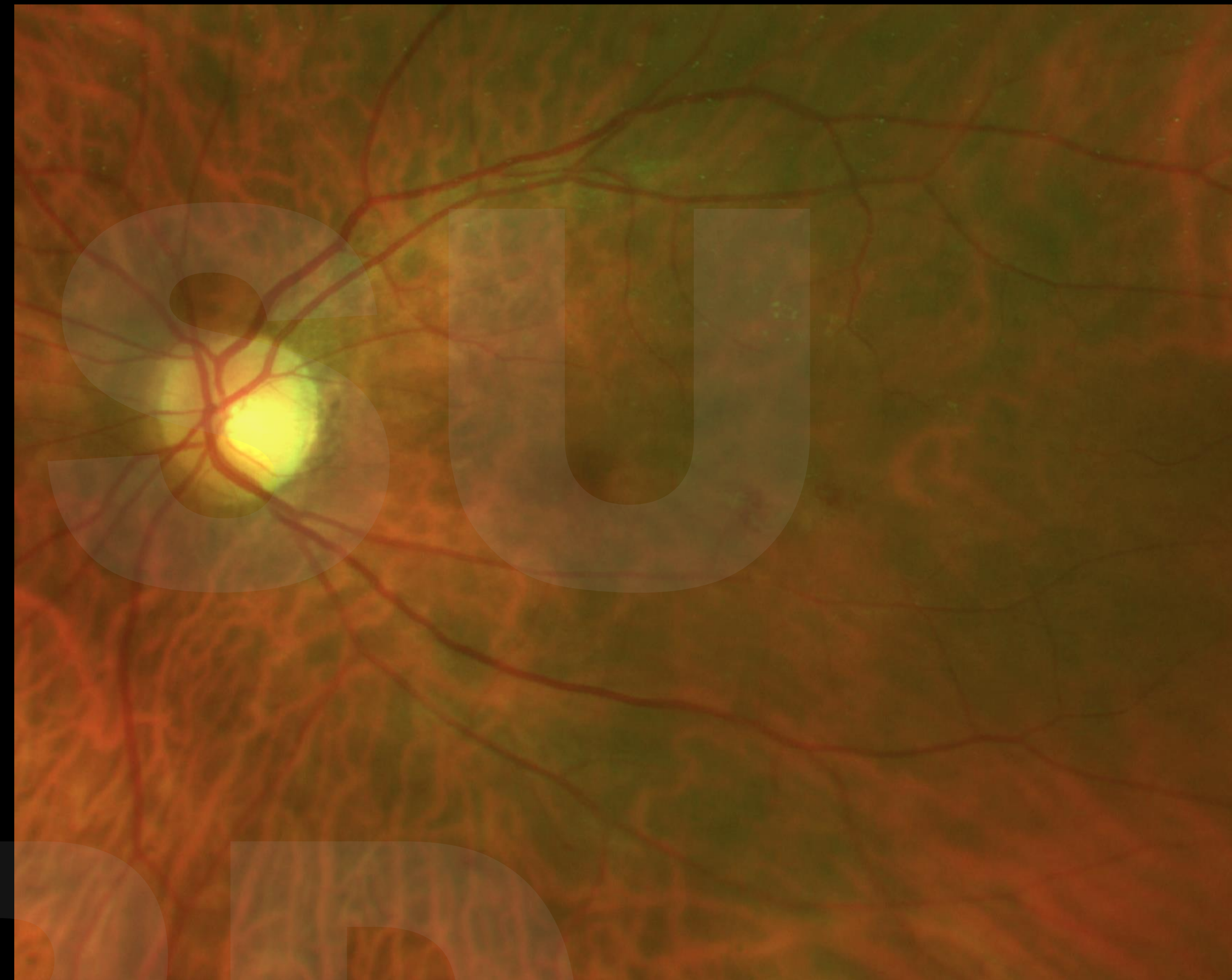
# Case #4

- 72 year old woman with 10 year history of DM and good vision presenting for screening exam



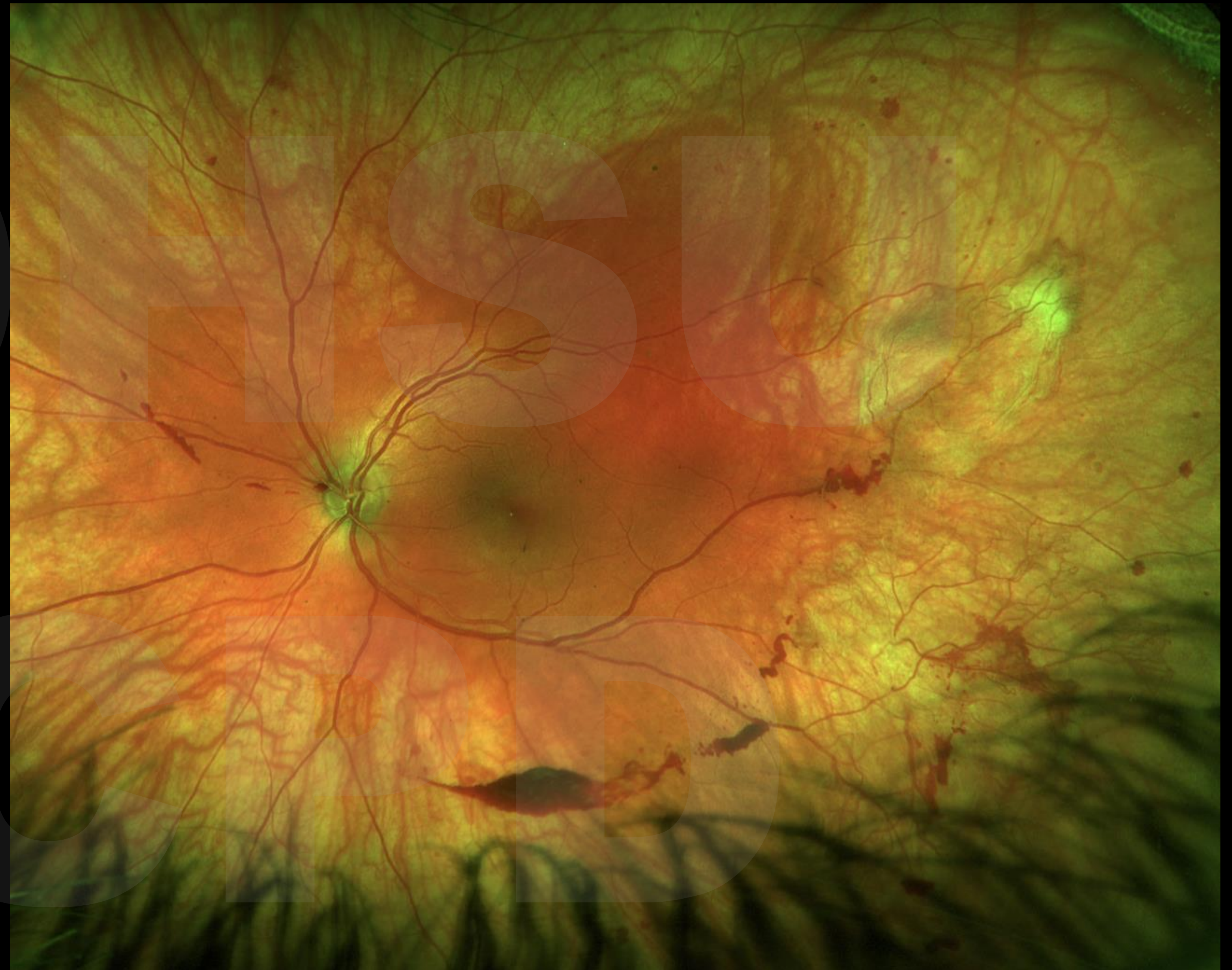
# Case #5

- 80 year old woman with type 2 diabetes and decreased vision to 20/70 level



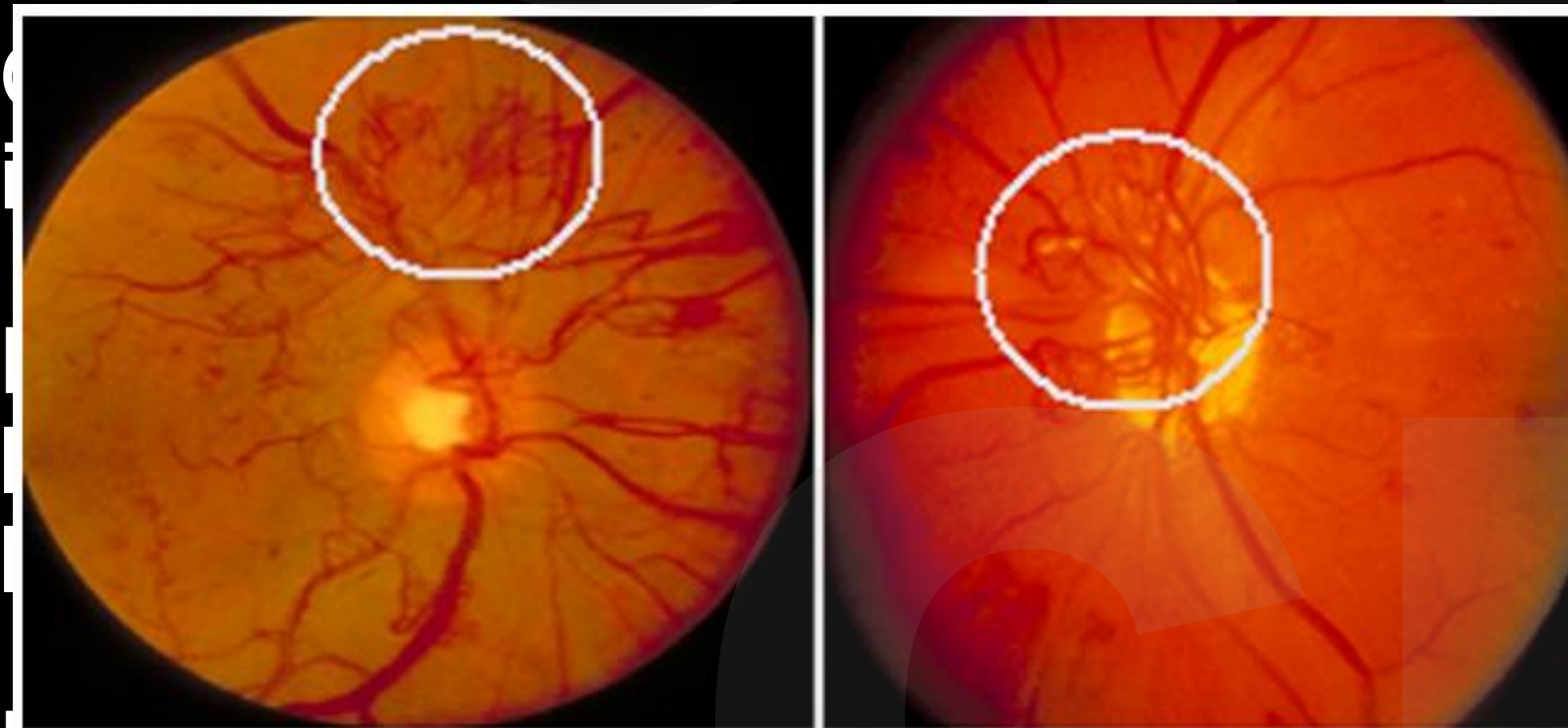
# Case #6

- 60 year old diabetic woman with a new floater in the left eye and 20/20 vision both eyes



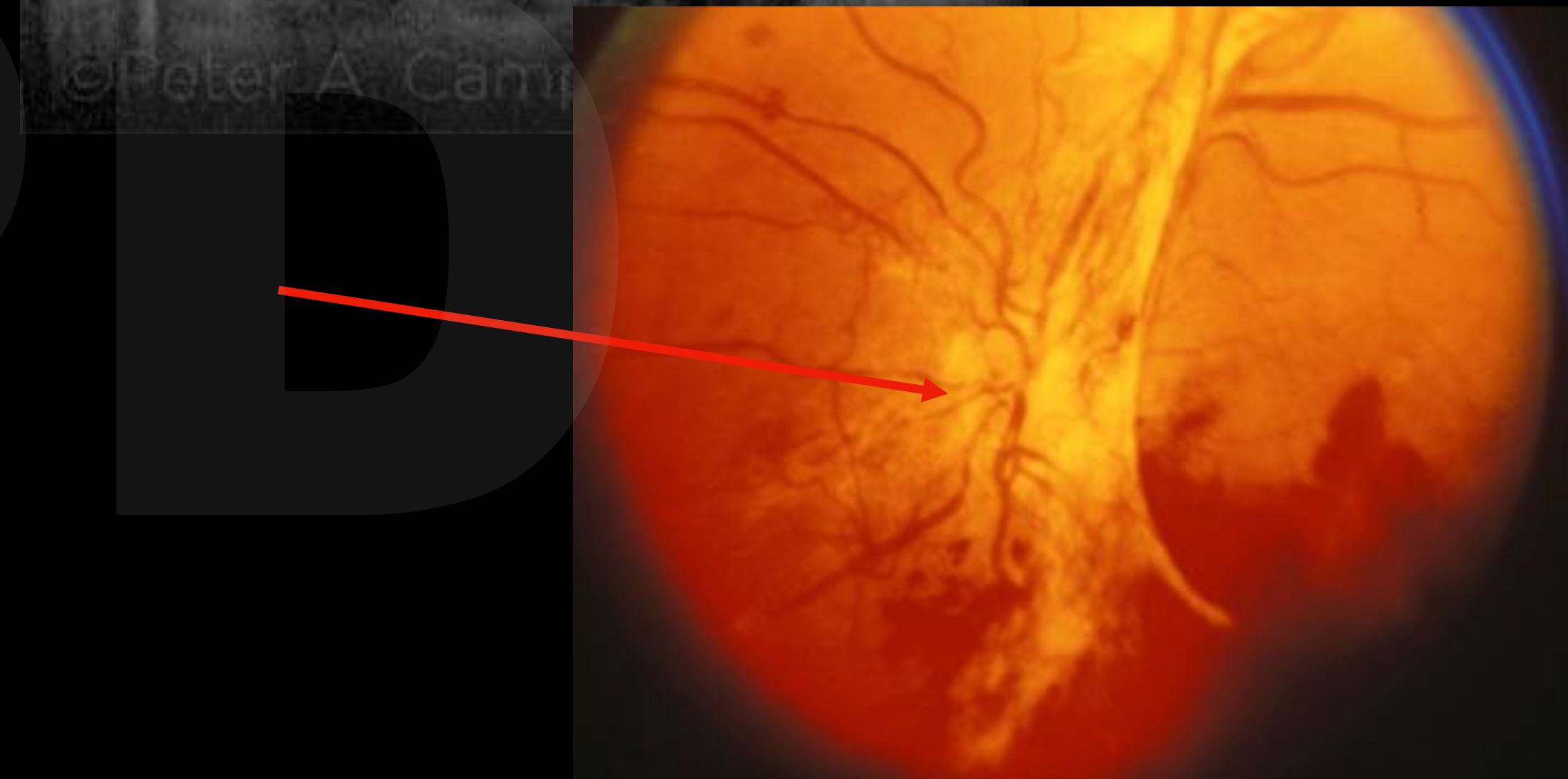
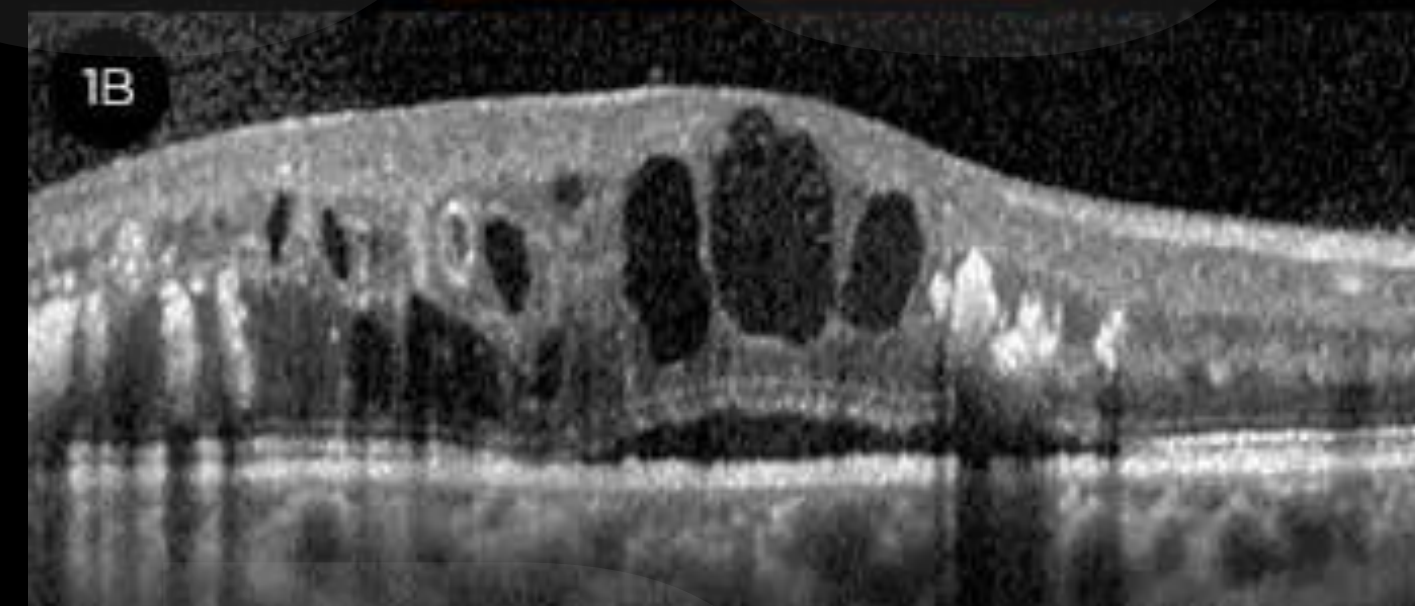
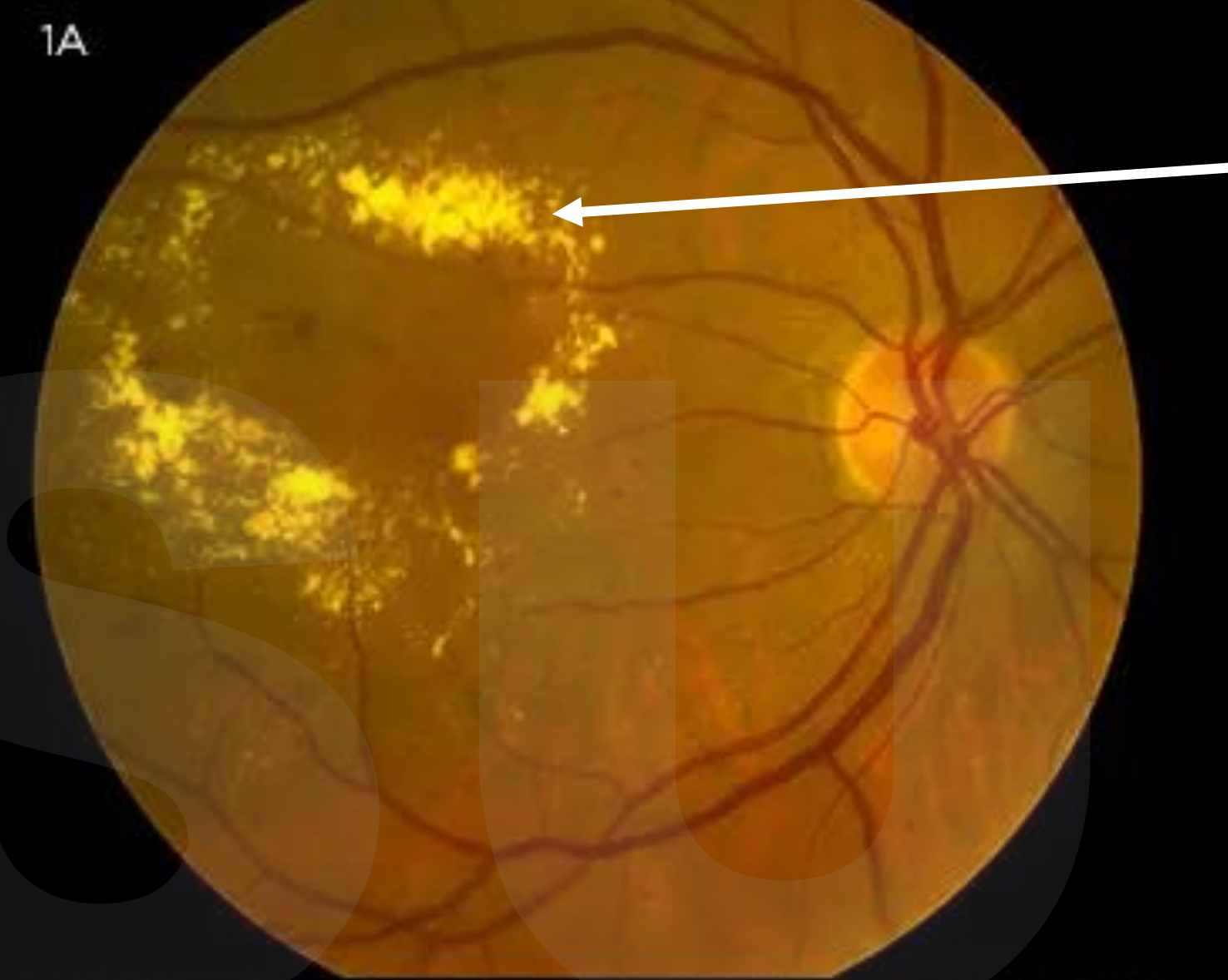# Diabetic retinopathy

- Microvasculopathy: damages the capillaries of the retina causing occlusion and leakage




(a) New vessels elsewhere (NVE) (b) New vessels on disc (NVD)

vessels cause hemorrhage and traction  
retinal detachment, causes severe vision loss




# DR Road Map

Mild NPDR  
Low Risk





Moderate  
NPDR  
Medium Risk



Severe  
NPDR  
High Risk

Proliferative  
DR

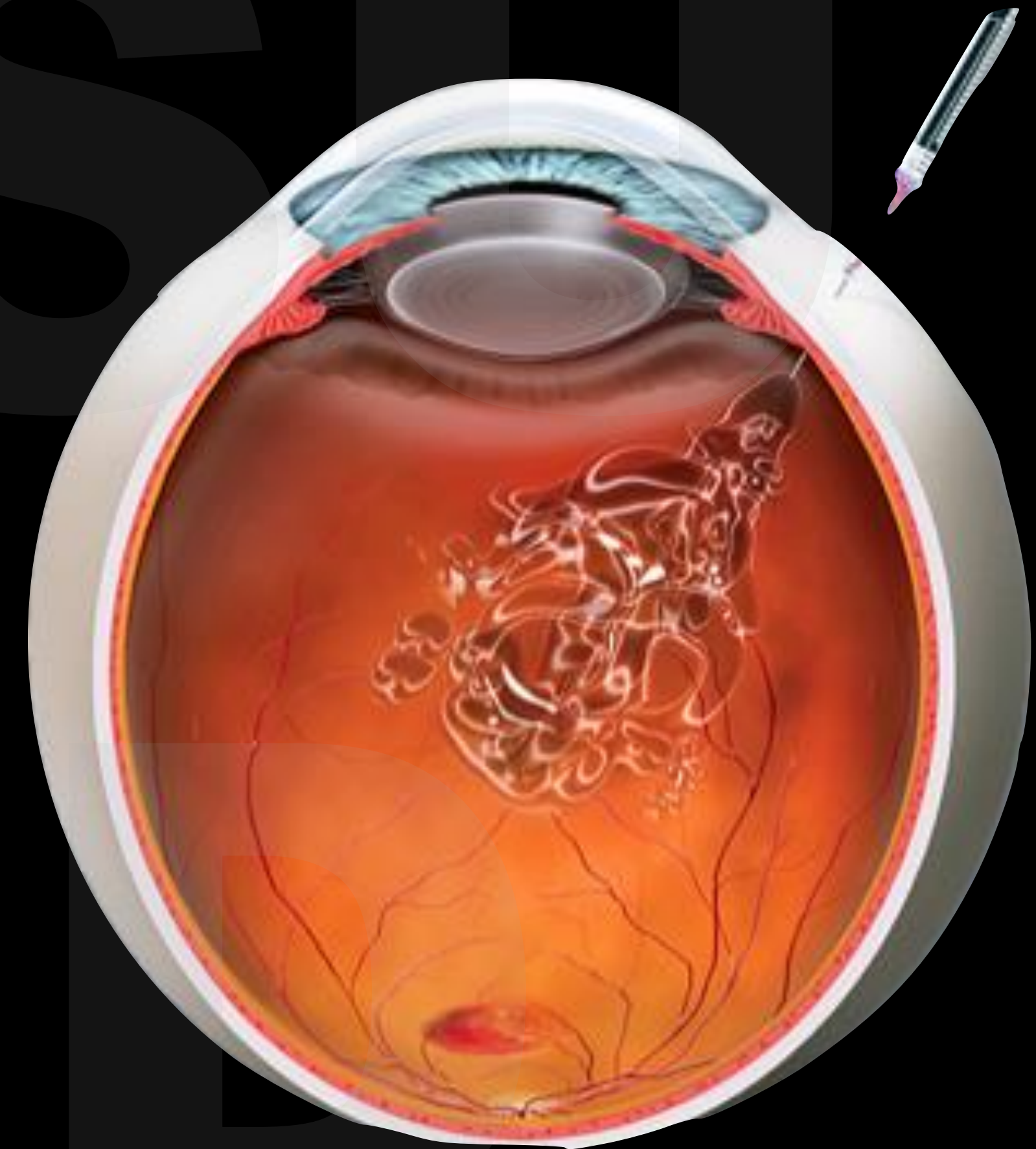Diabetes  
without  
retinopathy



Diabetic  
Macular  
Edema

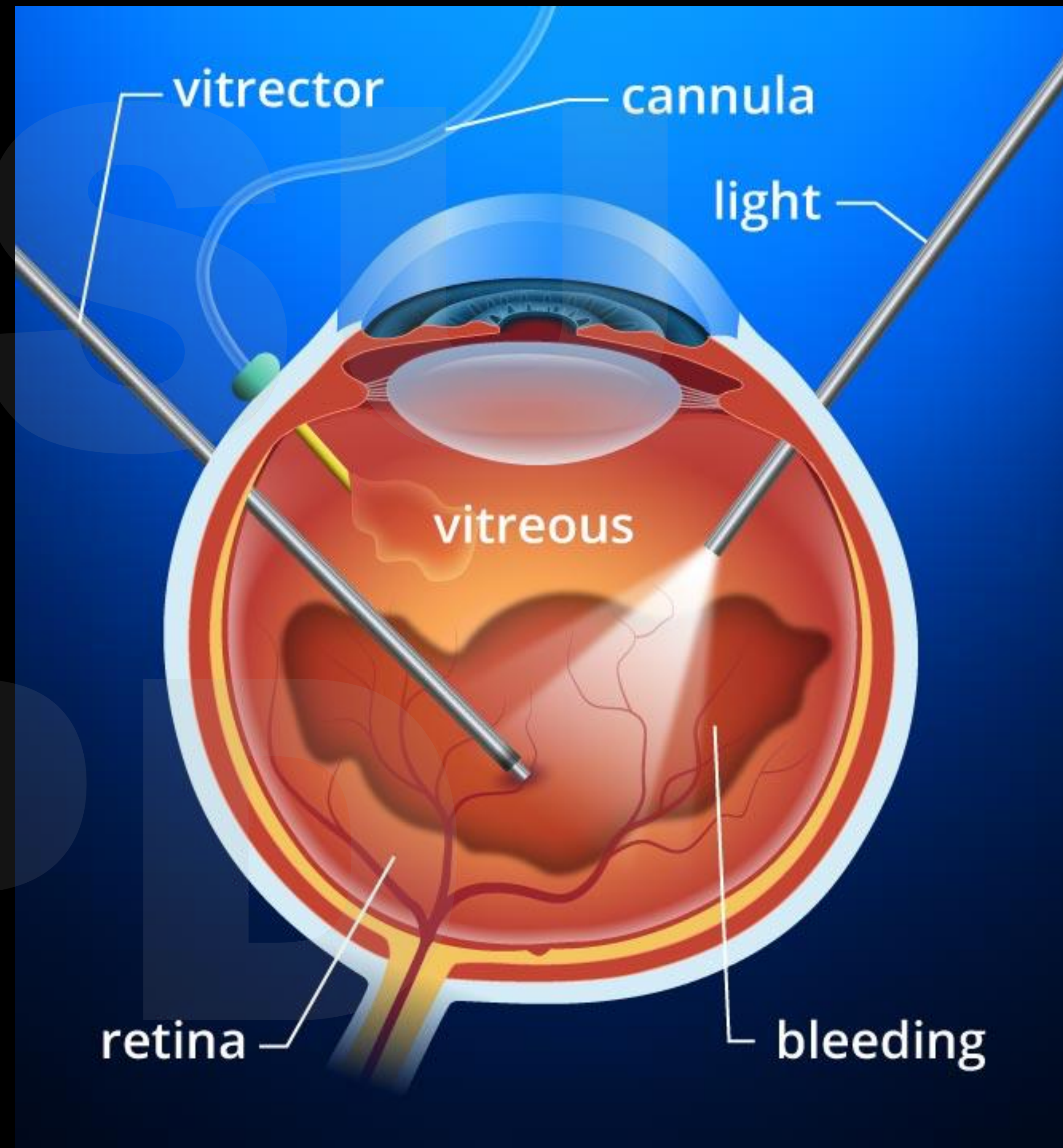
# Management

- Blood sugar control
- Blood pressure control
- Cholesterol control
- Anti-VEGF injections
- Laser photocoagulation
- Vitrectomy (for severe cases)
- Regular f/u exam



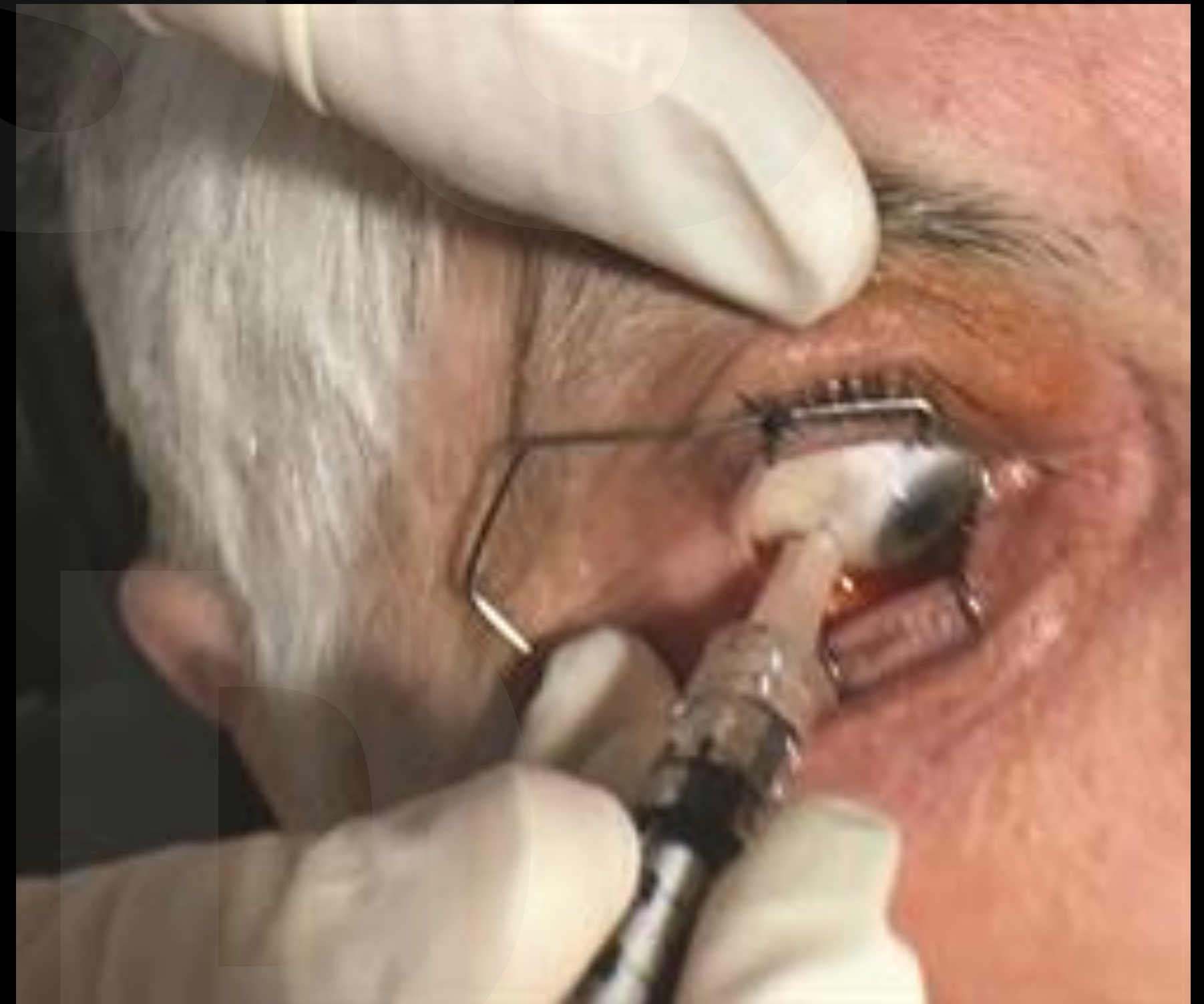# Vitrectomy

- Small instruments (23-27 gauge) can remove hemorrhage, cut and peel scar tissue, and apply laser.



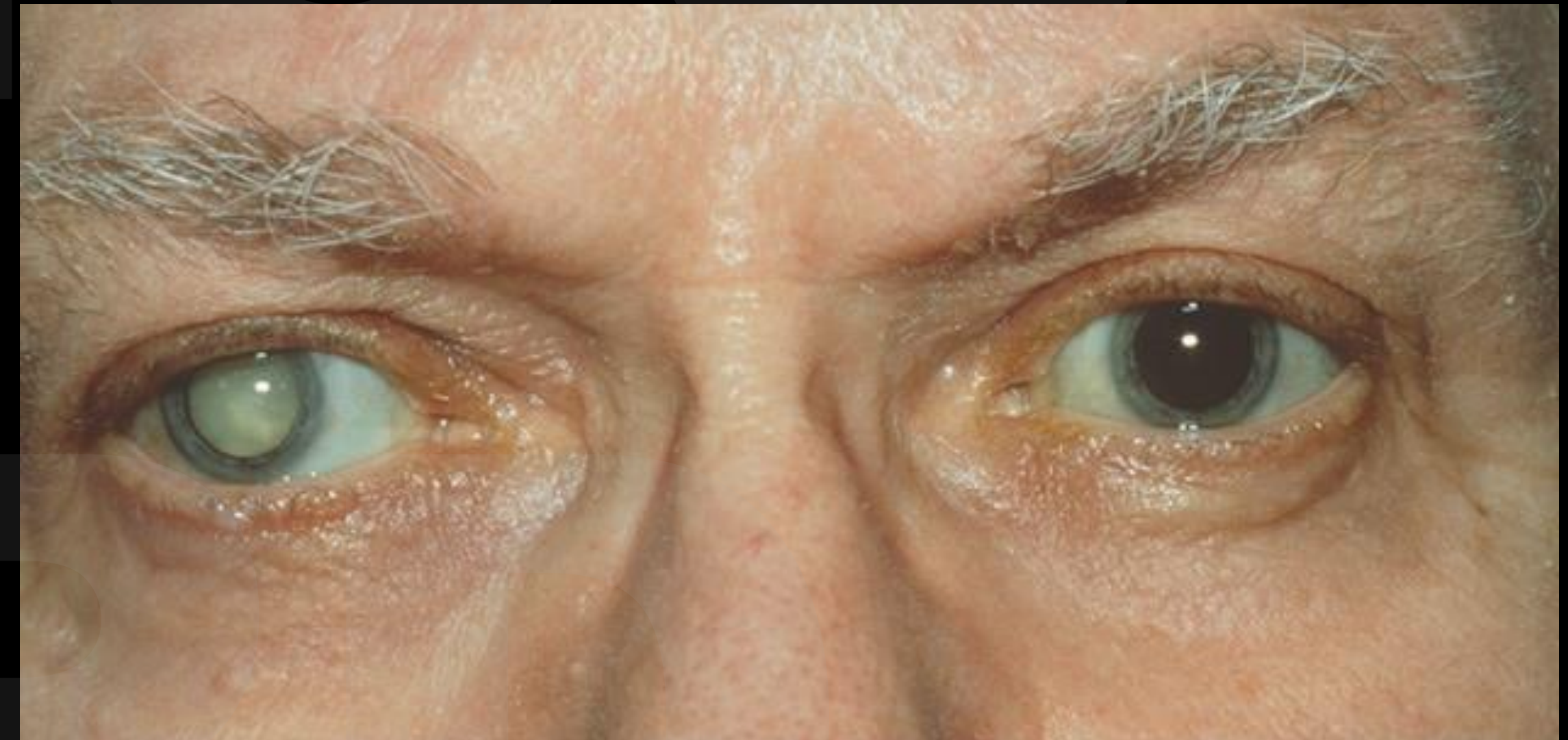# Anti-VEGF

- Generally do not hurt



# Cataract

- large waterfall or rapids



© MAYO FOUNDATION FOR MEDICAL EDUCATION AND RESEARCH. ALL RIGHTS RESERVED.

# Presentation of cataracts

- **Asymptomatic until certain threshold is reached**
- **Gradual loss of vision**
- **Blurred or double vision**
- **Sensitivity to light and glare**
- **Fading or yellowing of colors**

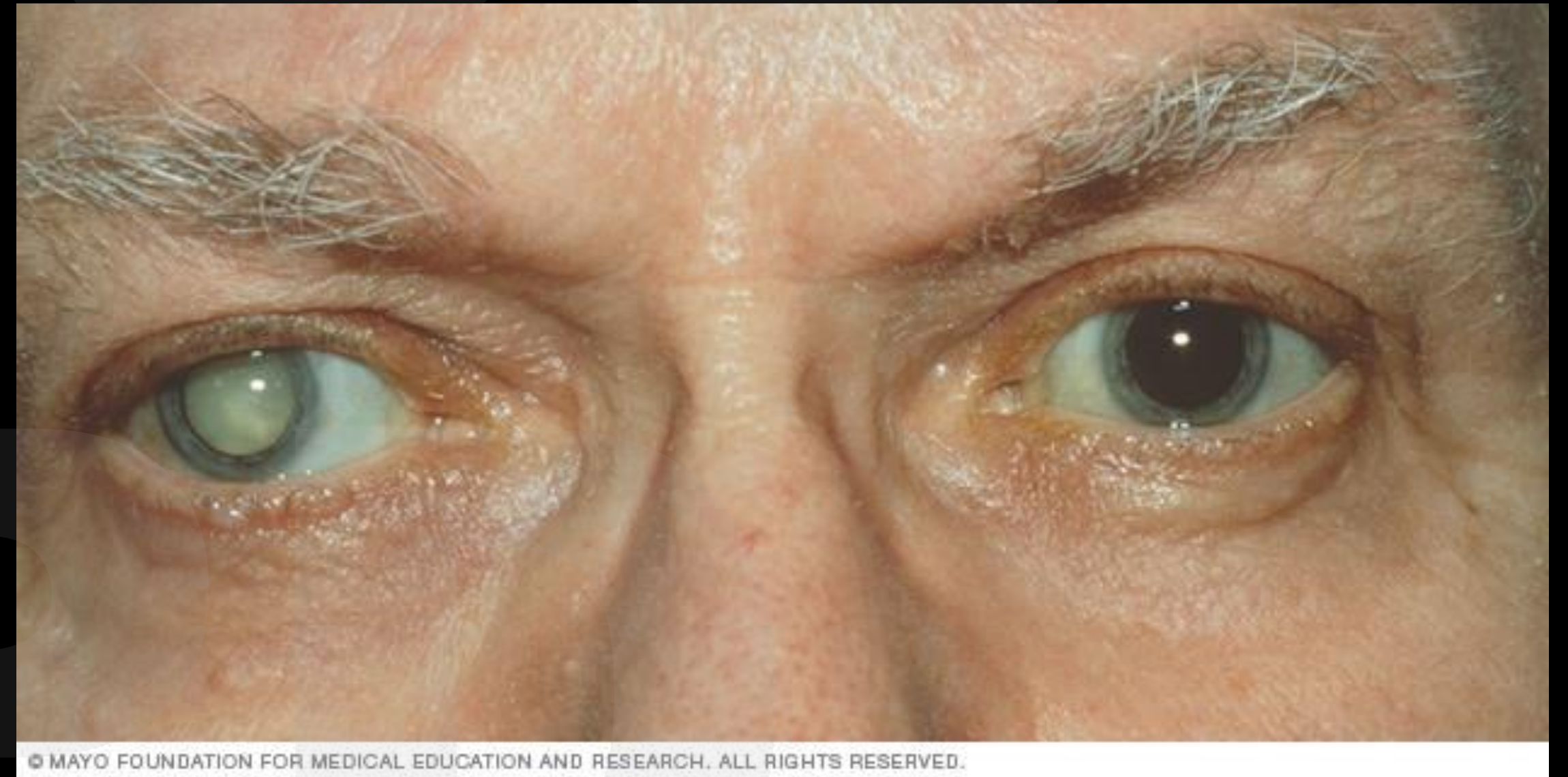

# Risk Factors for Cataracts

- Age
- Diabetes
- Excessive exposure to sunlight
- Smoking
- Hypertension
- Obesity
- Alcohol consumption
- Previous eye injury or inflammation
- Prolonged use of corticosteroid medications

# Clinical Diagnosis of Cataracts

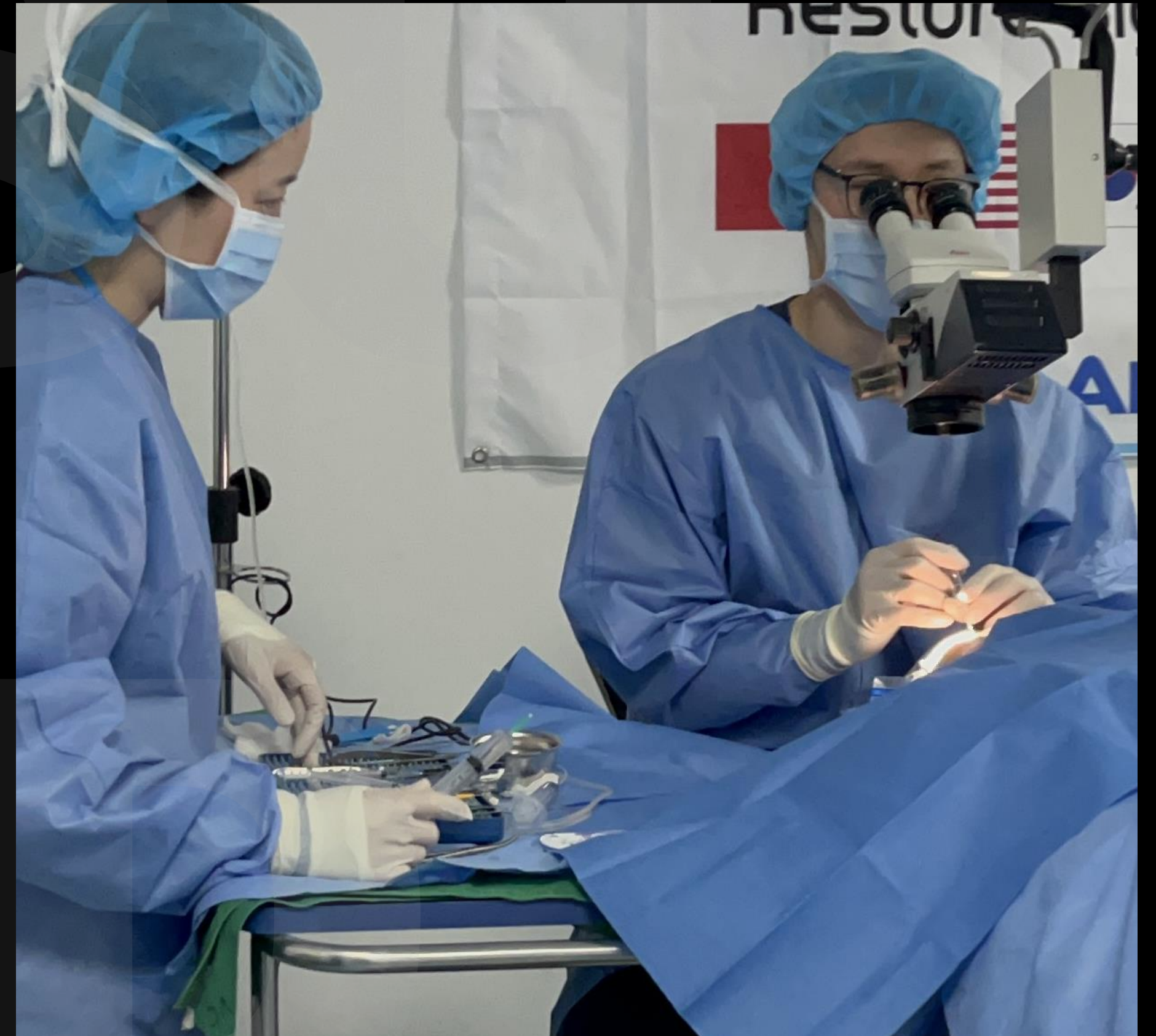- Comprehensive Eye Examination w/ dilation
- **Visual Acuity Test**



© MAYO FOUNDATION FOR MEDICAL EDUCATION AND RESEARCH. ALL RIGHTS RESERVED.

# Management of Cataracts

- Early-stage: stronger lighting, magnifying glasses, new eyeglasses or contacts
- Advanced-stage: cataract surgery
- Regular f/u exam



Han, X., Zhang, J., Liu, Z., Tan, X., Jin, G., He, M., & Luo, L. (2022). **Real-world visual outcomes of cataract surgery based on population-based studies: a systematic review.** *British Journal of Ophthalmology*, 107(8), 1056.

OHSU

**Glaucoma**

CPD

# Presentation of Glaucoma

- **Asymptomatic until certain threshold is reached**
- **Gradual loss of vision peripheral vision in most cases**
  - Can present with central vision loss
- **Pain in case of acute angle closure glaucoma**

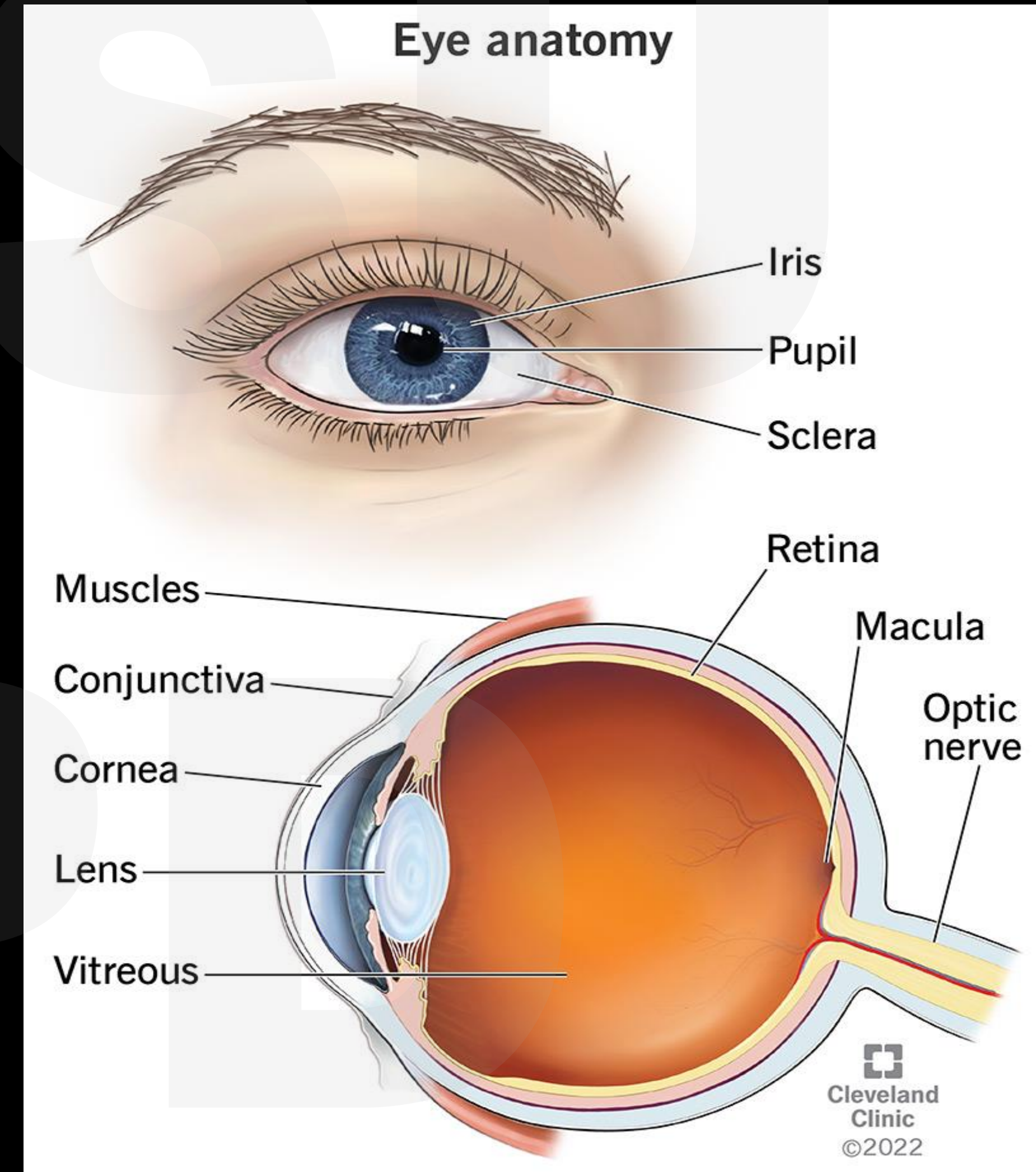
# Risk Factors for Glaucoma

- **Age**
- Genes (including family history)
- Intraocular Pressure
- Hypertension
- Diabetes
- Eye Injuries
- Corticosteroid Use
- Corneal Thickness



# Risk Factors for Glaucoma

- Age
- Genes (including family history)
- Intraocular Pressure
- Hypertension
- Diabetes
- Eye Injuries
- Corticosteroid Use
- Corneal Thickness



# Clinical Diagnosis of Glaucoma

- Comprehensive Eye Examination
- Tonometry
- Visual Field Test
- Optic Nerve Imaging – OCT & nerve photo
- Gonioscopy

# Management of Glaucoma

- Eye drops to reduce intraocular pressure
- Laser Therapy
- Surgery
- Medications (rare)
- Trabeculectomy
- Regular f/u exam

OHSSU

# Refractive Error

Including presbyopia

CPD

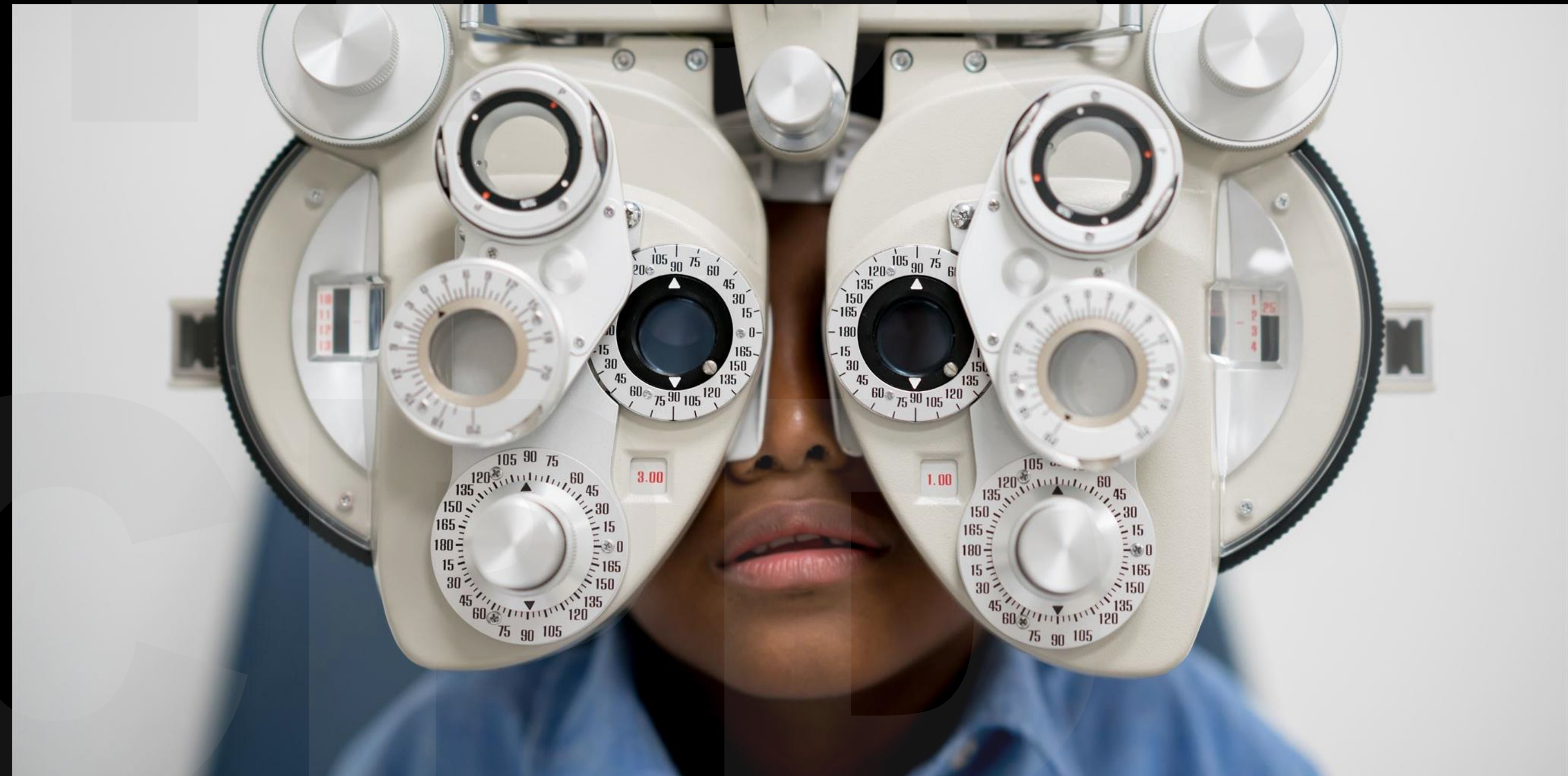# Risk Factors for Refractive Error

- Genes
- Age - Presbyopia commonly occurs in older adults
- Environmental Factors
- Prolonged near work
- Diabetes



# Clinical Diagnosis of Refractive Error

- Comprehensive eye examination
- Refraction test



# Management Options

- Eyeglasses
- Contact lenses
- Refractive surgery
- LASIK
- Orthokeratology



# Presbyopia

- Common in adults over 40
- Reading glasses
- Bifocal or progressive lenses
- Contact lenses (multifocal or monovision)
- Refractive surgery
- Intraocular lens insertion

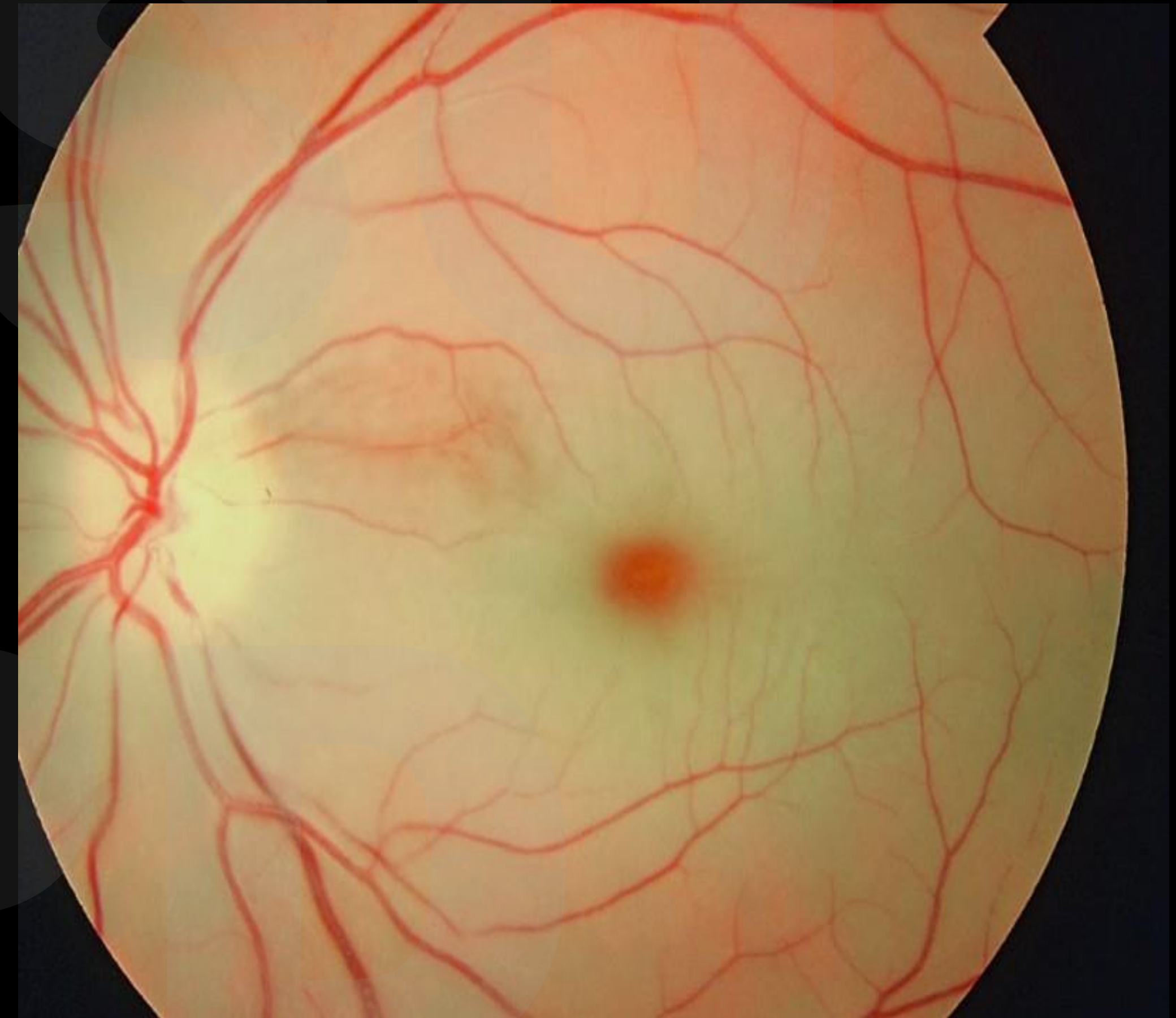

# Ocular emergencies

- Giant Cell Arteritis (GCA)
  - Can present with CRAO or amaurosis fugax
- Acute angle closure glaucoma – severely painful sudden loss of vision
- Retinal detachments – painless vision loss a/w floater, flashes and/or curtain
- Central retinal artery occlusion
- Hypertensive retinopathy – check BP
- Trauma

# Central retinal artery occlusion

- Sudden painless loss of vision
  - Age (more common in older adults)
  - Hypertension
  - Diabetes
  - Atherosclerosis
  - Smoking
  - Hyperlipidemia
- Send to ED for stroke work up



**OHHSU**

**Thank you for your attention!**

**Special thanks to Dr Thomas Hwang for  
contribution to the slides**

**CPD**