



Mucosal Dermatology

Erin Foster, MD PhD

Associate Professor

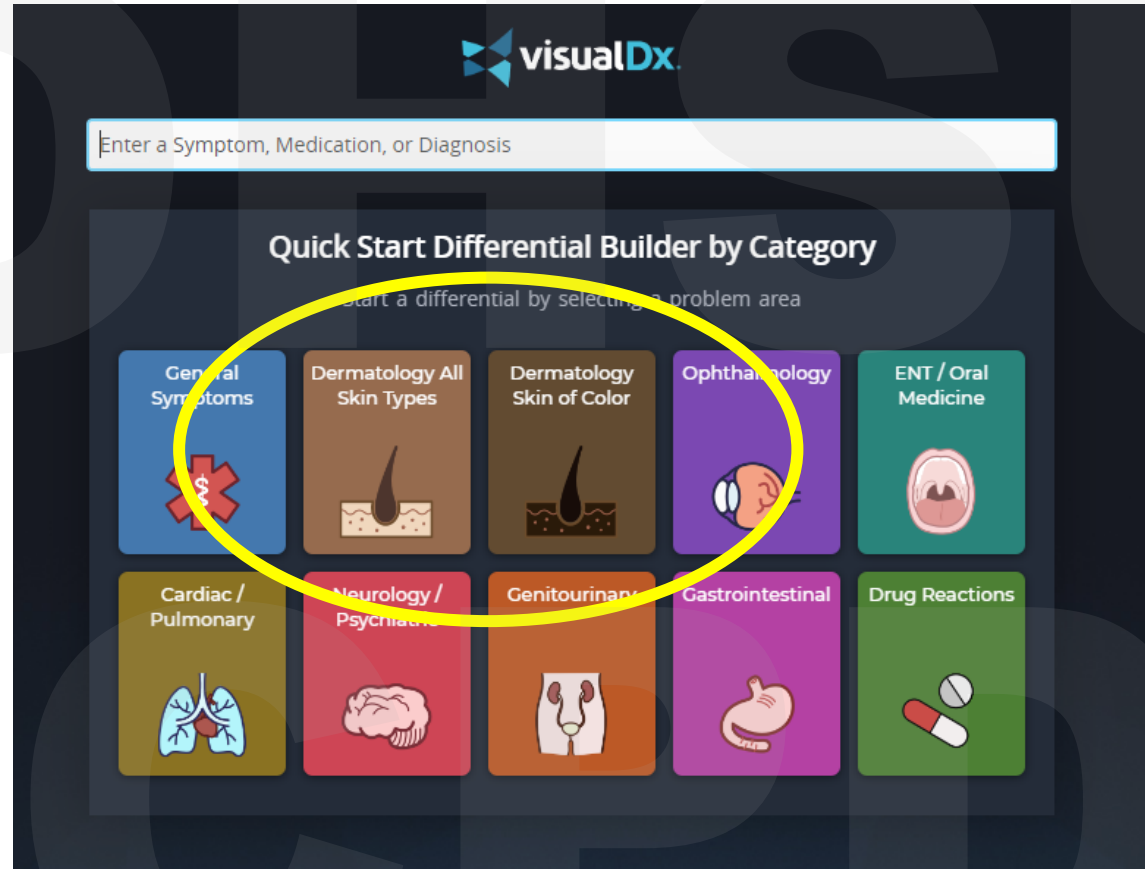
OHSU Dermatology

57th Annual Primary Care Review

Portland, Oregon

February 10, 2026

Please use VisualDx to help with derm!



Clinical photos are from patients who have given their consent.

I have used VisualDx or DermNetNZ photos as needed for completeness and increased representation of skin of color.



Goals for today's talk:

1. Learn practical tips to diagnose and treat mucosal disorders
2. Understand when to look for systemic signs or causes of mucosal disease



Outline

Pre-Test

Part 1- Introduction

1. Why mucosal dermatology?
2. Why should clinicians care?
3. When, where, and how to biopsy mucosa

Part 2 – Cases: Beyond the basics

1. Canker sores
2. Gingivitis
3. Balanitis
4. Vulvovaginitis

Post-Test



Pre-Test

- What is the most important step for patient comfort in mucosal biopsies?
- What are 2 safe options for topical steroids on mucosa?
- What are 3 possible underlying causes of recurrent canker sores?
- What workup is helpful for complex aphthosis?
- What features of gingivitis point toward an autoimmune cause?
- What is the differential diagnosis for balanitis?
- What are major causes of contact dermatitis?
- What are safe alternatives to prevent vulvar contact dermatitis?

Lichen Planus

Lichen Sclerosus

“My skin just bleeds and peels away.”

“I wish my husband had a girlfriend.”

Mucous membrane pemphigoid

Pemphigus vulgaris

“I can’t concentrate on work.”

“I’ve choked so many times I don’t eat alone anymore.”

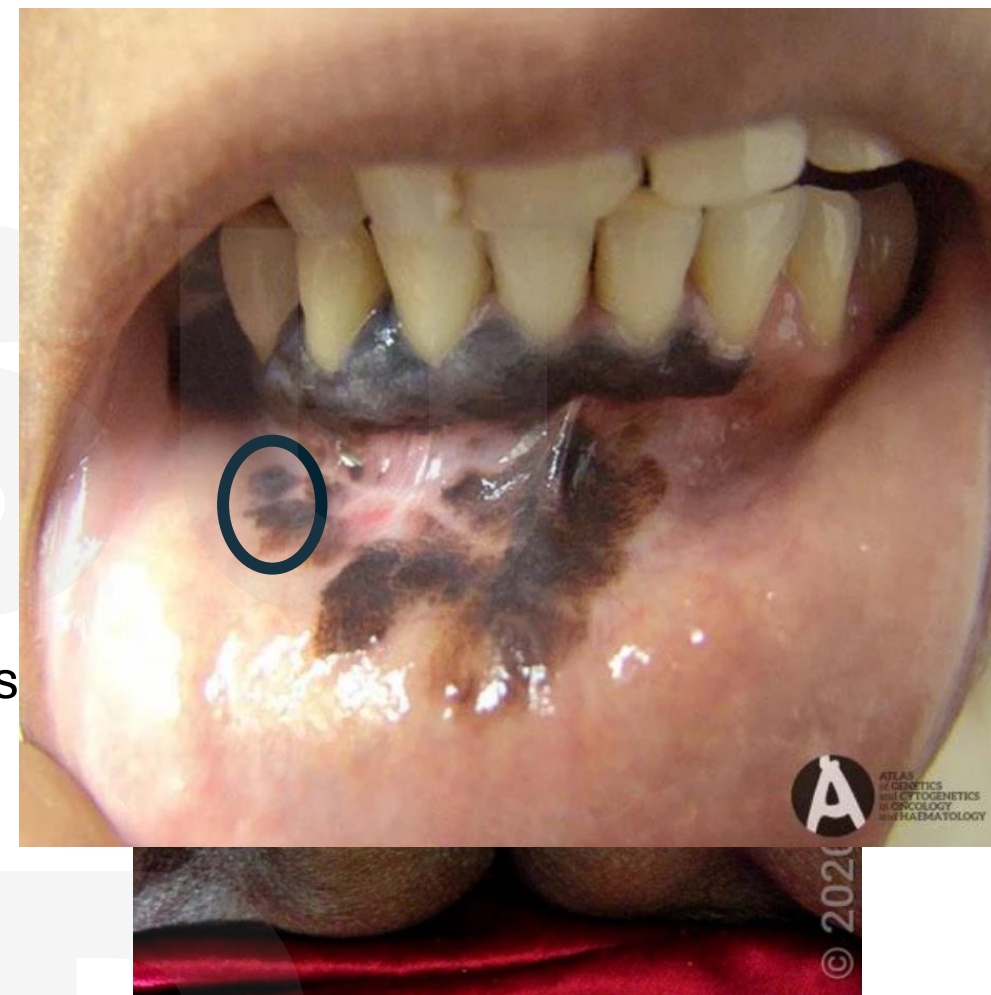

Why should clinicians care?

- Underserved diseases and patient population
- Frequent delays in diagnosis
 - Dentists do not receive significant training in oral mucosal disease
 - Many OB/Gyn practitioners aren't comfortable diagnosing vulvar skin disease
 - Examination of genital skin in dermatology training only 40% of the time
 - 50% did not think the vulvar exam was part of the dermatologists' responsibility
- Significant amount of shame in these patients
- Therapeutic alliance, clinician-patient trust, shared decision making
- Motivated patients = increased compliance
- It's just skin (and you can make a real difference 😊)

Tips for Mucosal Biopsies

- Pick a good site
 - Minimal tension
 - Avoid midline on genitals
- Representative lesions
 - **Non-ulcerated, perilesional** for blistering diseases
 - **Newest** for rashes
 - **Darkest** for pigmented spots
- **Use plenty of anesthetic****
 - Start with **topical lidocaine 4-5% cream** and WAIT 5-10 minutes
 - Then inject **lidocaine with epinephrine** and WAIT 5-10 minutes
 - 4mm punch biopsy sufficient for most
 - Close with 5-0 FastGut, 4-0 Polysorb or use aluminum chloride or cautery
- Wound care: Vaseline, Vaseline, topical lidocaine, Vaseline





Which topicals are safe and helpful?

- Lidocaine 4% aqueous gel, cream, or 5% ointment*
- Triamcinolone dental paste
- Dexamethasone oral solution
- Nystatin swish
- Clotrimazole troche (lozenge)
- Magic Mouthwash (homemade > compounded)
 - 1:1:1 Maalox, Benadryl, Lidocaine is my favorite

Clobetasol 0.05% ointment (genitals)

Clobetasol 0.05% gel (oral cavity)

Cases

OHSU

CPD



Case 1: Canker sores

- 17 yo male with recurrent canker sores, especially when he is stressed or sick



Aphthous Stomatitis aka canker sores

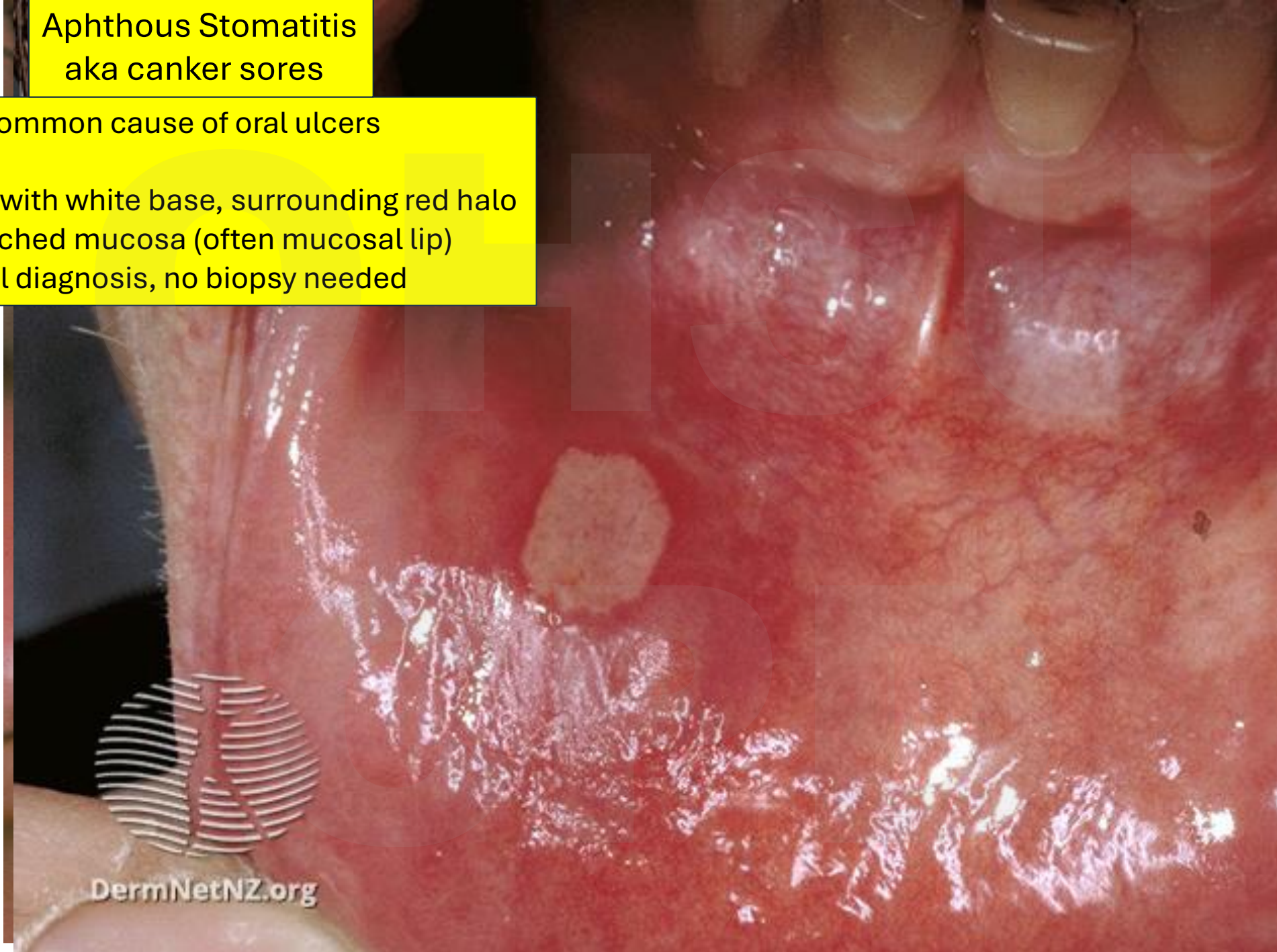
Most common cause of oral ulcers

Painful

Round with white base, surrounding red halo

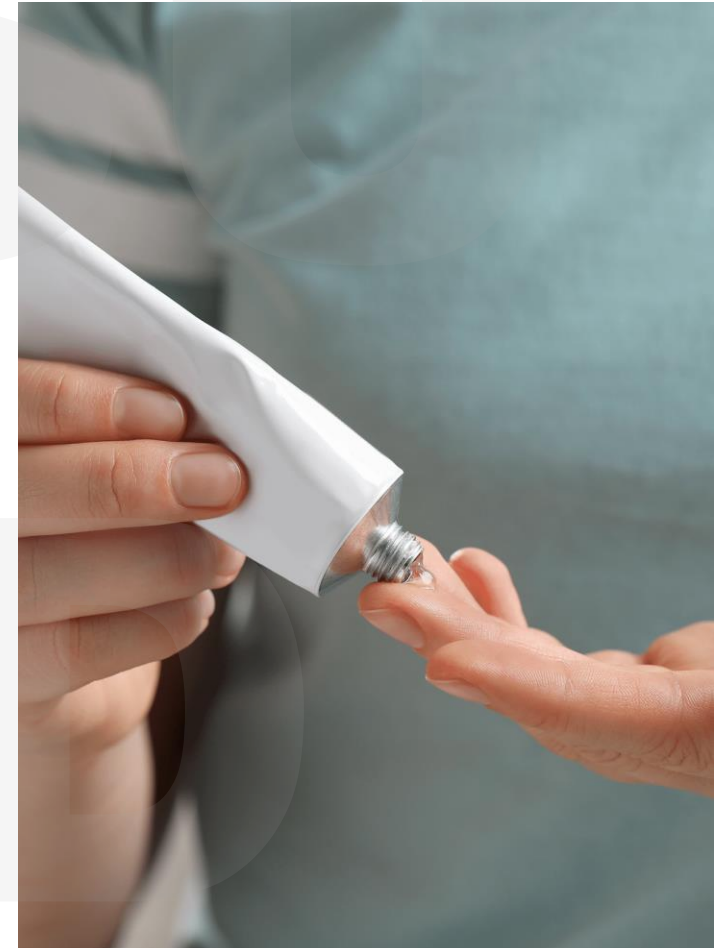Unattached mucosa (often mucosal lip)

Clinical diagnosis, no biopsy needed



Treatment of simple recurrent oral aphthae

- Oral dexamethasone elixir
 - Swish and spit for prevention
- Clobetasol gel PRN to sores
- Viscous xylocaine, orabase
- SLS-free toothpaste
- Soft toothbrush, avoid trauma
- Stop medications causing dry mouth





Garden variety aphthous stomatitis

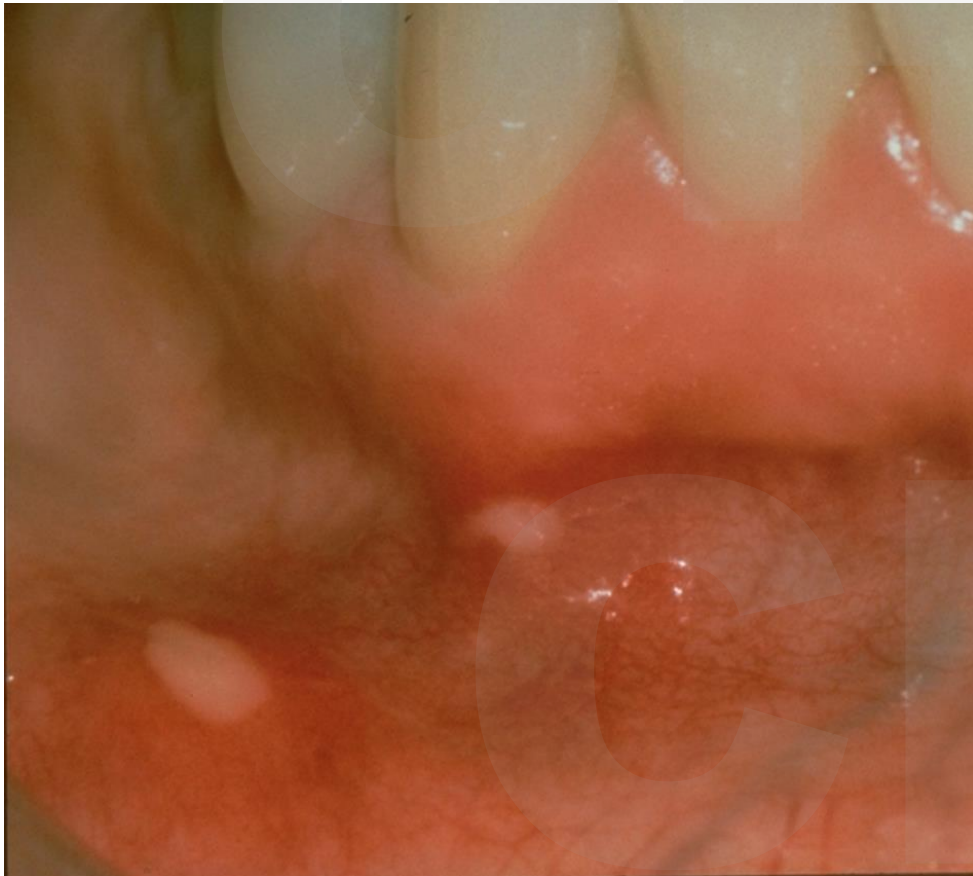- 1-2 sores at a time, lasting <7-10 days
- Acute onset
- +/- prodrome
- Can be recurrent, 3-6 times per year
- Multiple causes and comorbidities:
 - Tobacco cessation
 - Sodium laurel sulfate
 - Dry mouth
 - Trauma
 - Viral/bacterial infections
- Biopsy is not helpful



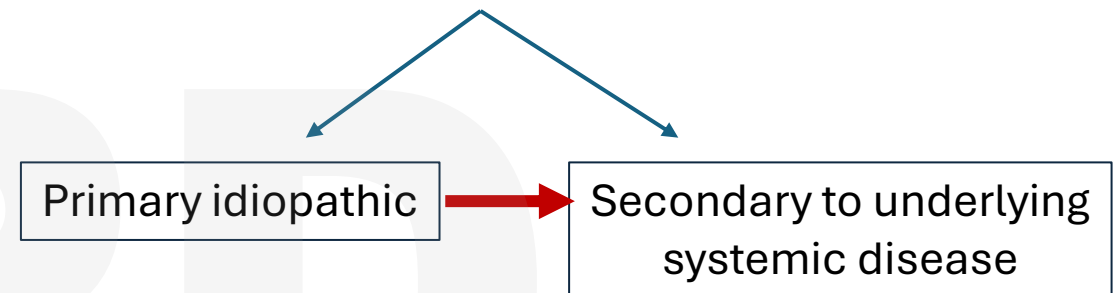
When does a canker sore need further workup?

CPD

Complex aphthosis



Recurrent oral and genital ulcers
Sometimes larger, deeper
More than 2 at a time
Longer to resolve
One heals then another appears



Back to our 17 year old:

- Nearly constant
- Has also been tired lately
- His mother thinks he looks pale

Underlying causes of complex aphthosis:

- Inflammatory bowel disease
- HIV, immune suppression
- Cyclic neutropenia
- Acute myeloid leukemia

- Rare: PFAPA syndrome, MAGIC syndrome
- Behcet's Disease (diagnosis of exclusion)



Workup:

HSV swab

Viral studies

CBC

Iron, ferritin, TIBC

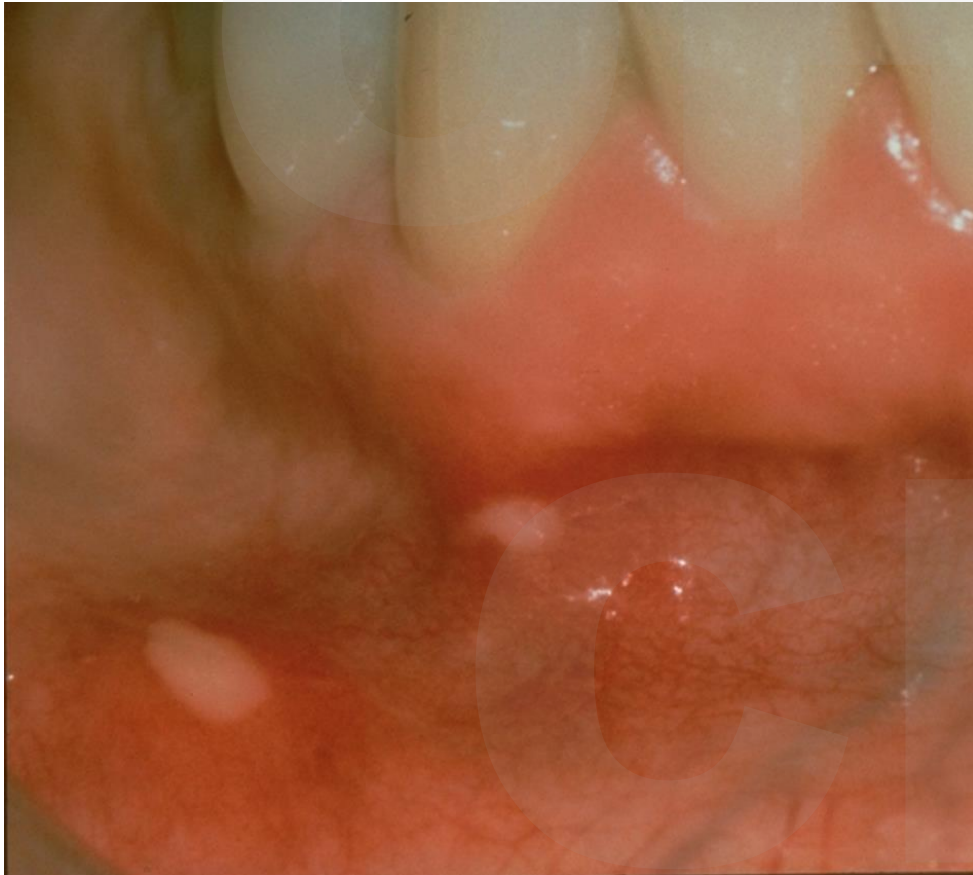Serum vitamin B, folate

HIV, syphilis

Fecal calprotectin → Colonoscopy

Crohn's Disease

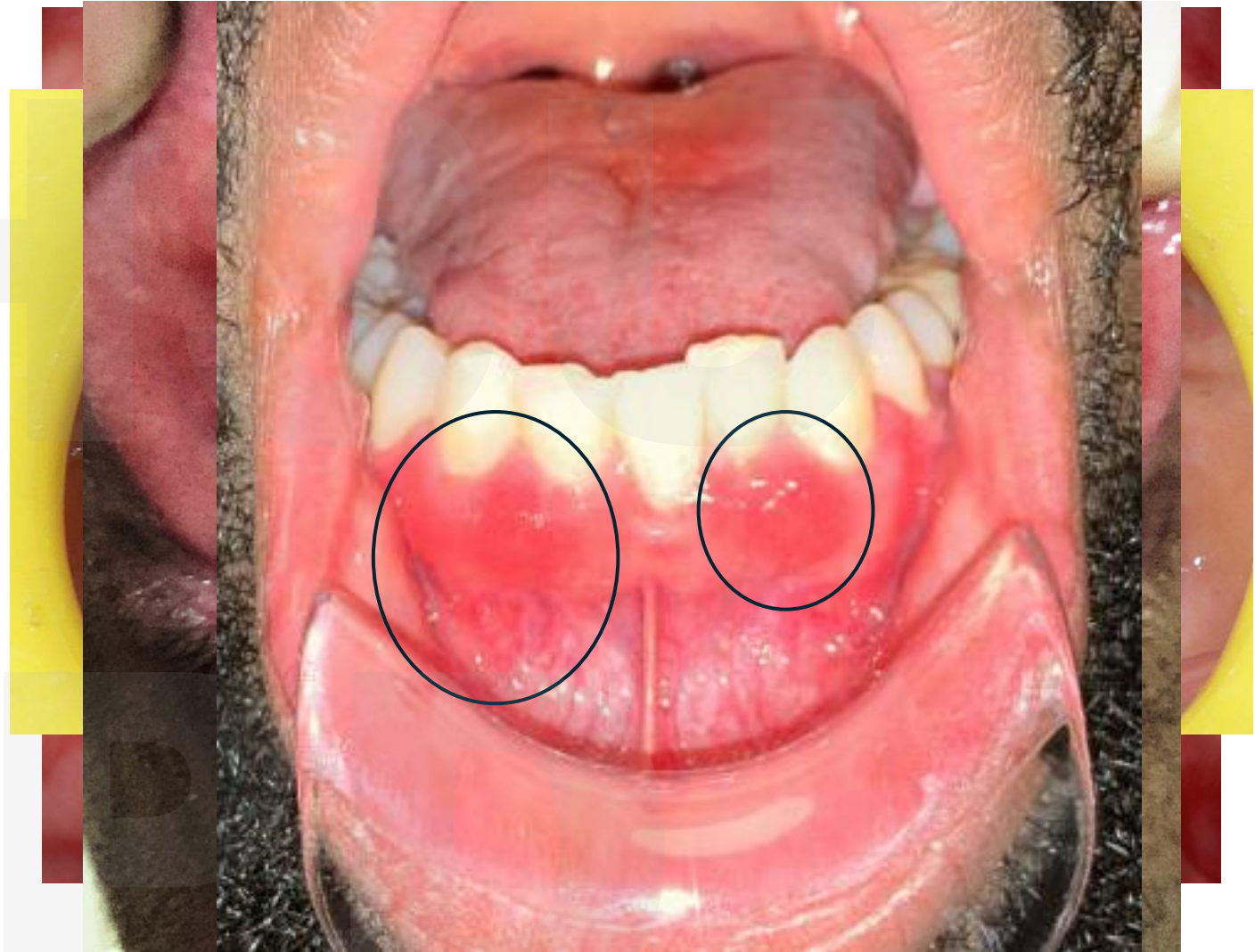
Complex aphthosis treatment options



- Oral prednisone
 - 40-60mg qAM x 3-5 days, then 20-30mg qAM x 3-7 days
- Colchicine 0.6 mg BID
- Dapsone 75-150 mg daily
- Pentoxifylline 400 mg TID
- Thalidomide 50-150 mg daily
- Apremilast, TNF inhibitors

Case 2: Gingivitis

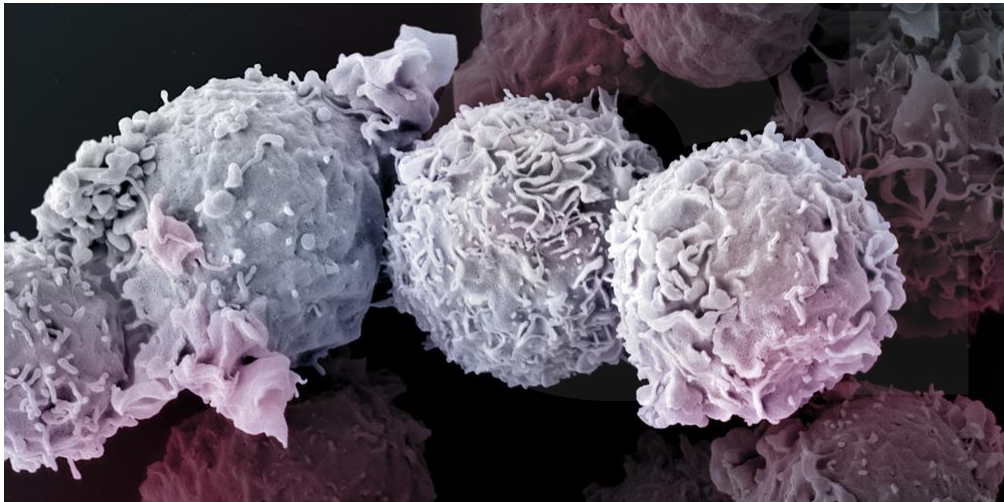
- 48 year old female with chronic gingivitis
- Bleeding when she flosses
- Peeling or sloughing skin
- Painful
- Avoiding spicy, crunchy foods



Atypical Gingivitis is a sign of autoimmune disease

Clues:

- Healthier dentition than expected
- Desquamative – peeling off mucosa
- Burning, painful
- Prominent erythema
- Other mucosal areas (tongue, hard palate, buccal mucosa) can be affected

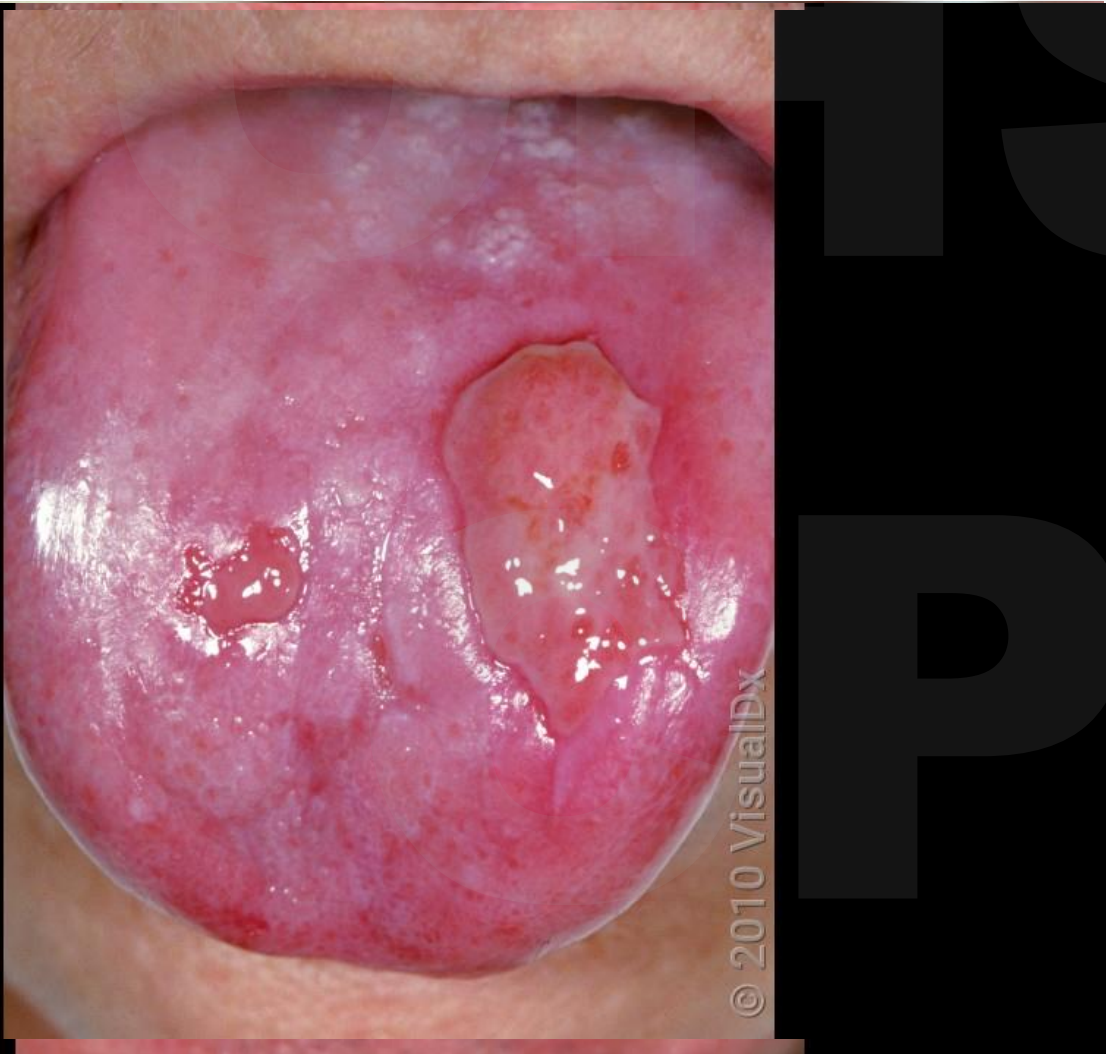

T cells, Nano Imaging Lab SNI, University of Basel

Underlying causes of atypical gingivitis:

- Oral lichen planus
- Lichenoid medication reaction
- Pemphigus vulgaris
- Paraneoplastic pemphigus
- Mucous membrane pemphigoid
- Erythema multiforme

Oral lichen planus can cause gingivitis, sloughing, ulcers, papules, atrophic glossitis



Subtypes of Oral Lichen Planus:

Reticular

Erosive, Desquamative

Papular

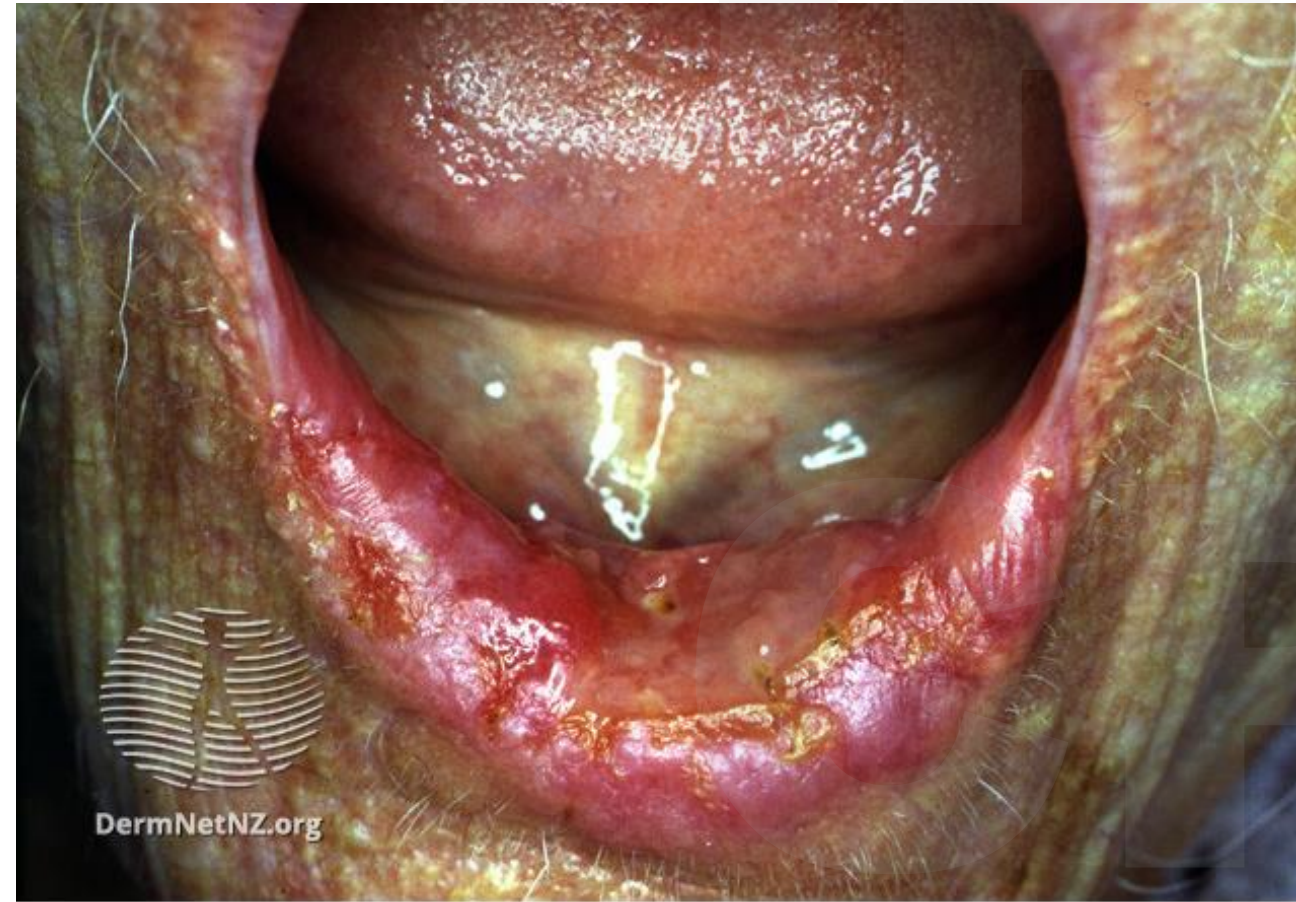Plaque-like

Atrophic

Bullous

Lichen Planus Significantly Increases the Risk of Oral Squamous Cell Carcinoma

- SCC is the most common malignancy of the oral cavity
- Occurs in 1-5% of patients with oral lichen planus
- Floor of mouth, lateral tongue, lower lip are most common sites
- Higher risk if:
 - Erosive disease
 - Located on tongue
 - Smoker, heavy alcohol use
 - HPV+



DermNetNZ.org

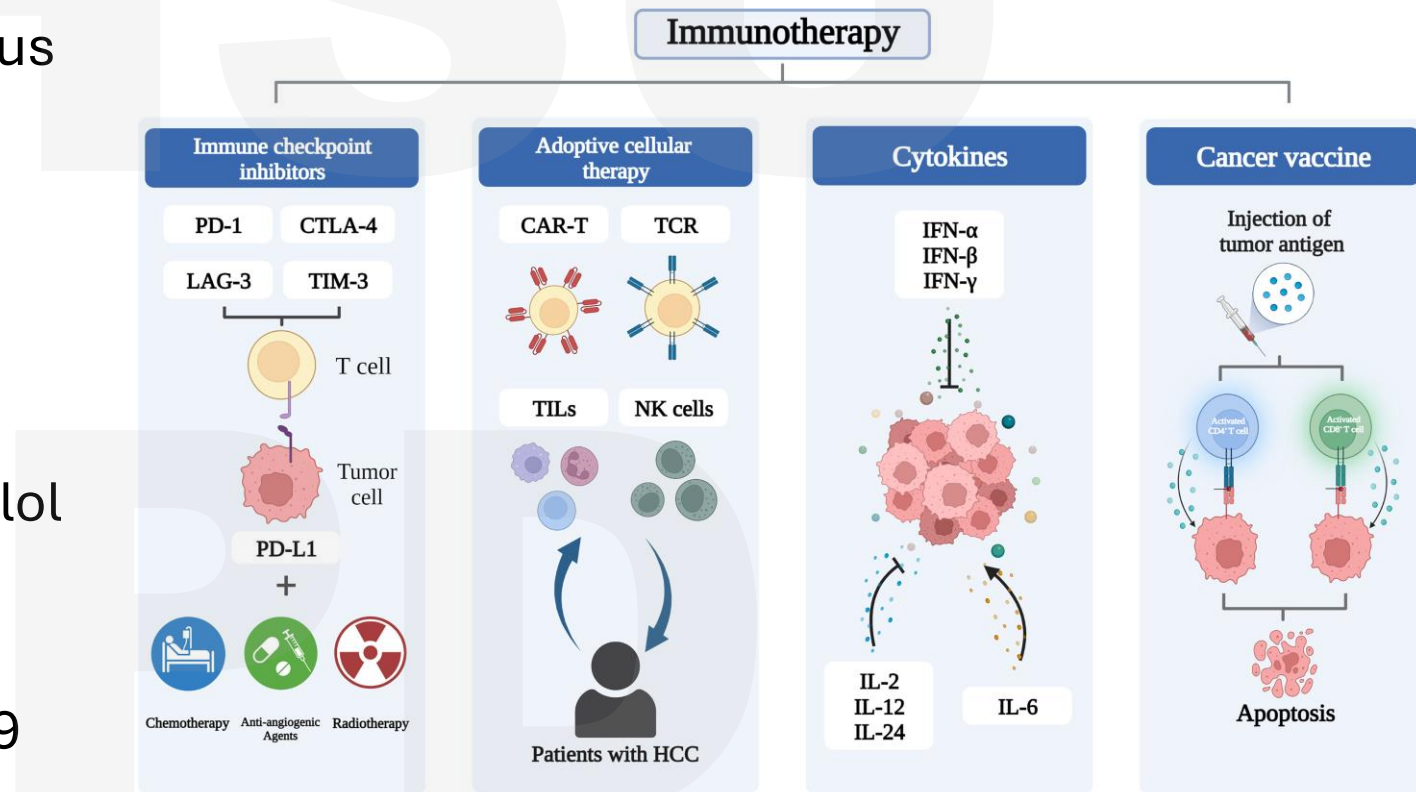
Mucosal lichen planus can occur secondary to common medications

Timing: up to 3-6 months after starting medication or dose increase

Appearance: identical to lichen planus

Common culprits:

- NSAIDs
- ACE inhibitors (esp lisinopril)
- HCTZ
- Beta-blockers, especially metoprolol
- Metformin
- TNF-alpha inhibitors
- Vaccines such as flu and COVID-19
- **Immune checkpoint inhibitors**





Oral lichen planus treatment options

- Remove offending medication if possible
- SLS-free toothpaste
- Avoid mint, cinnamon, citrus, spicy foods
- Dexamethasone 0.5mg/5ml oral solution BID, swish and spit
- Prednisolone 15mg/5ml oral solution BID, swish and spit
- Clobetasol 0.05% gel to painful spots PRN

Please biopsy or refer if not responding to topical treatment!

Oral prednisone 0.5 mg/kg daily – rebounds when stopped

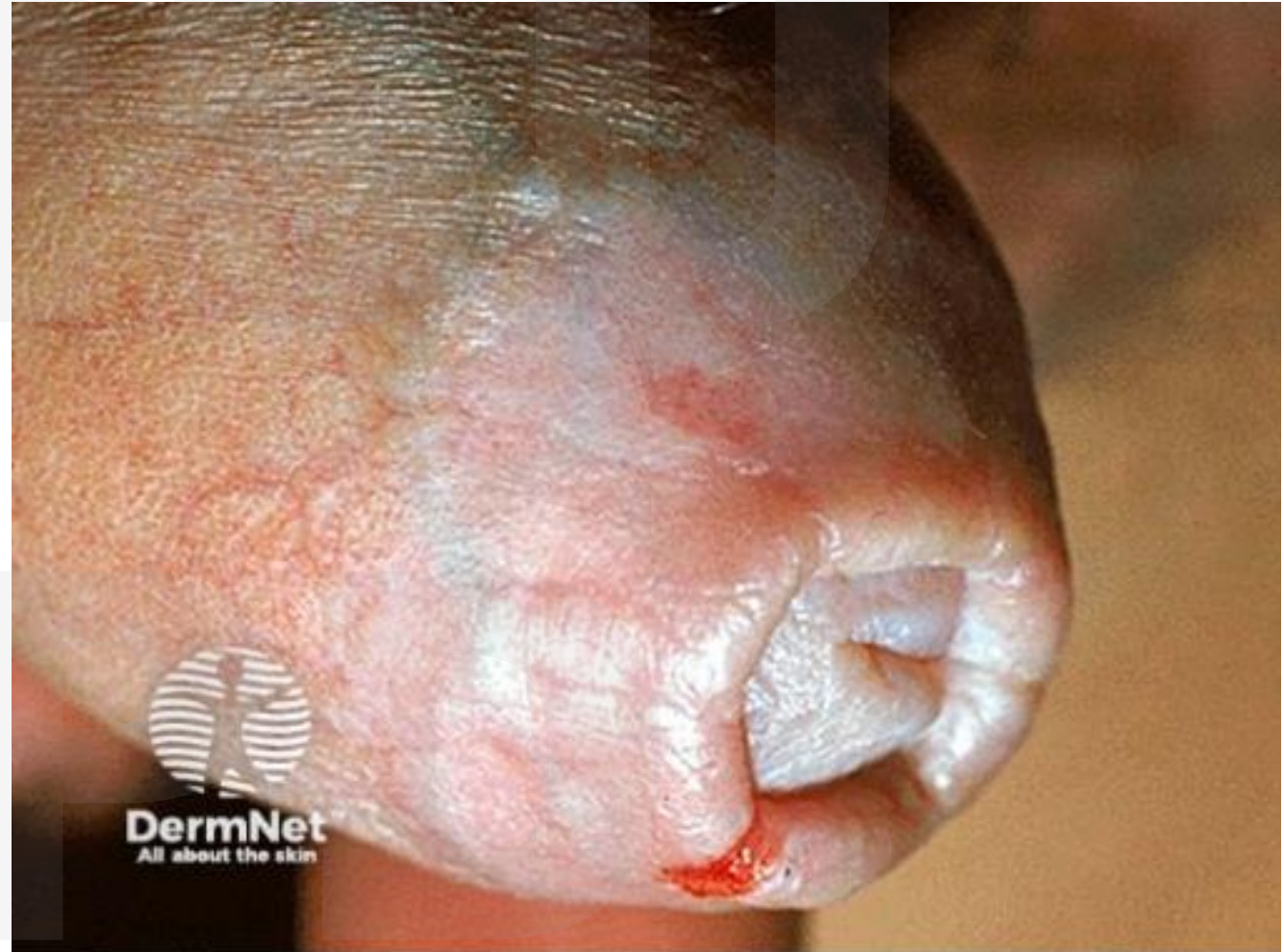Hydroxychloroquine 200-400mg daily

Methotrexate 15-25 mg/week

JAK inhibitors (upadacitinib, deucravacitinib)

Case 3: Balanitis

- 55 year old male with itchy penile rash x 3 years
- Pain with sex
- More difficulty w/urination lately
- Tried and failed:
 - Nystatin
 - Hydrocortisone
 - Mupirocin
 - Keflex, doxycycline
 - Fluconazole



Causes of Genital Rashes?

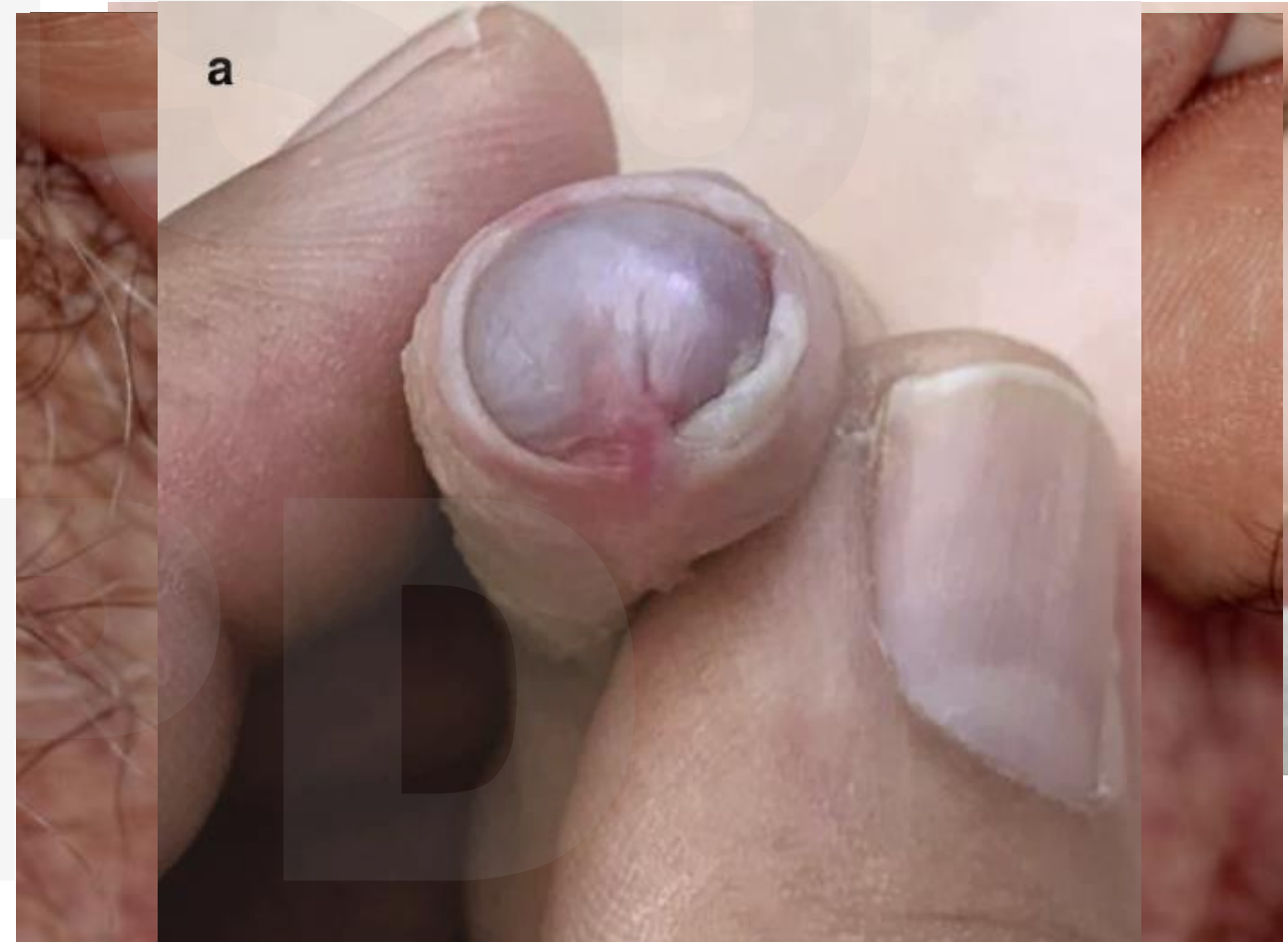- ~~Atopic dermatitis/eczema~~
- ~~Contact Dermatitis~~
- ~~Tinea Cruris~~
- ~~Psoriasis~~
- Lichen sclerosus
- ~~Lichen simplex chronicus~~
- ~~Mucous membrane pemphigoid~~
- ~~Lichen planus~~

+ Scarring?

+Itch > Pain?

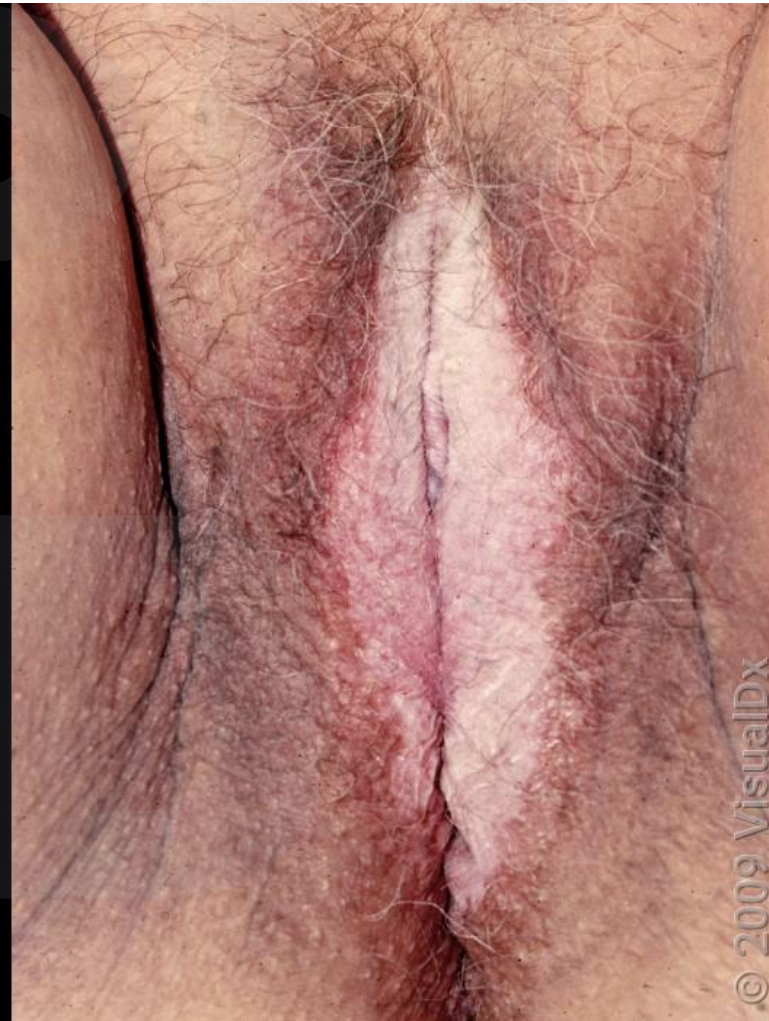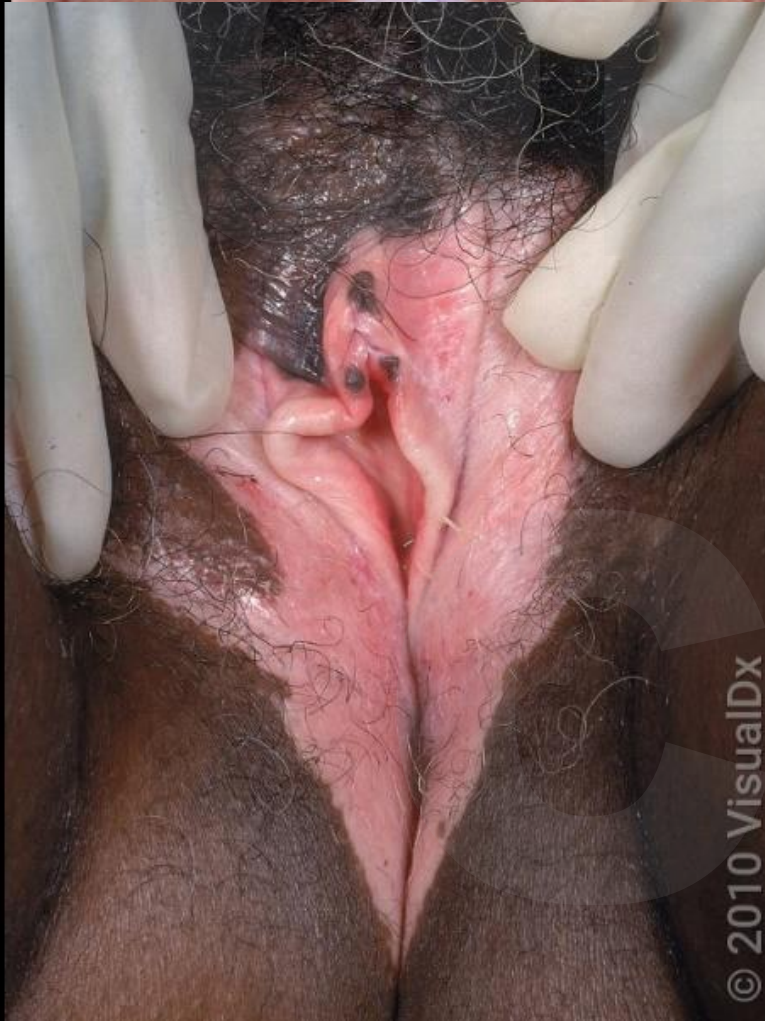Penile lichen sclerosus can be asymptomatic and mild or severe and scarring

- AKA balanitis xerotica obliterans
- Loss of pigment = white skin
- Wrinkly, “cigarette paper” skin
- Sclerotic, thickened
- Thinning, purpura
- Prominent vessels

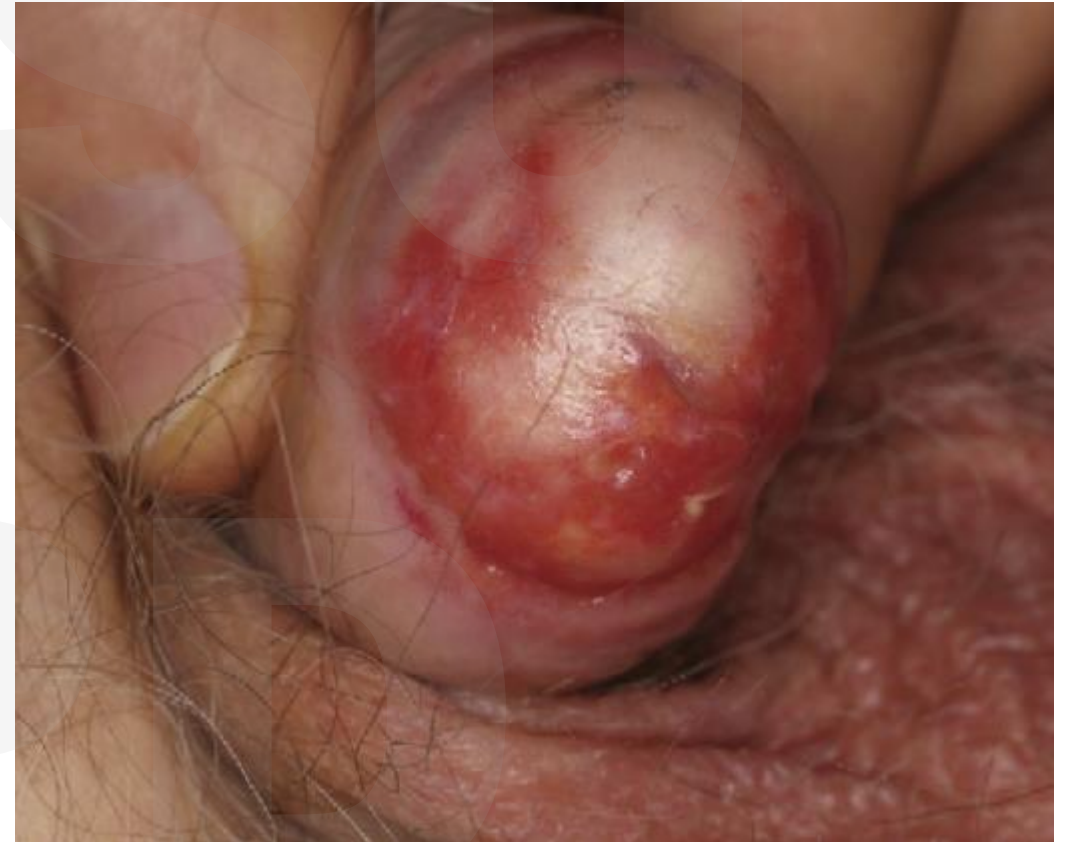
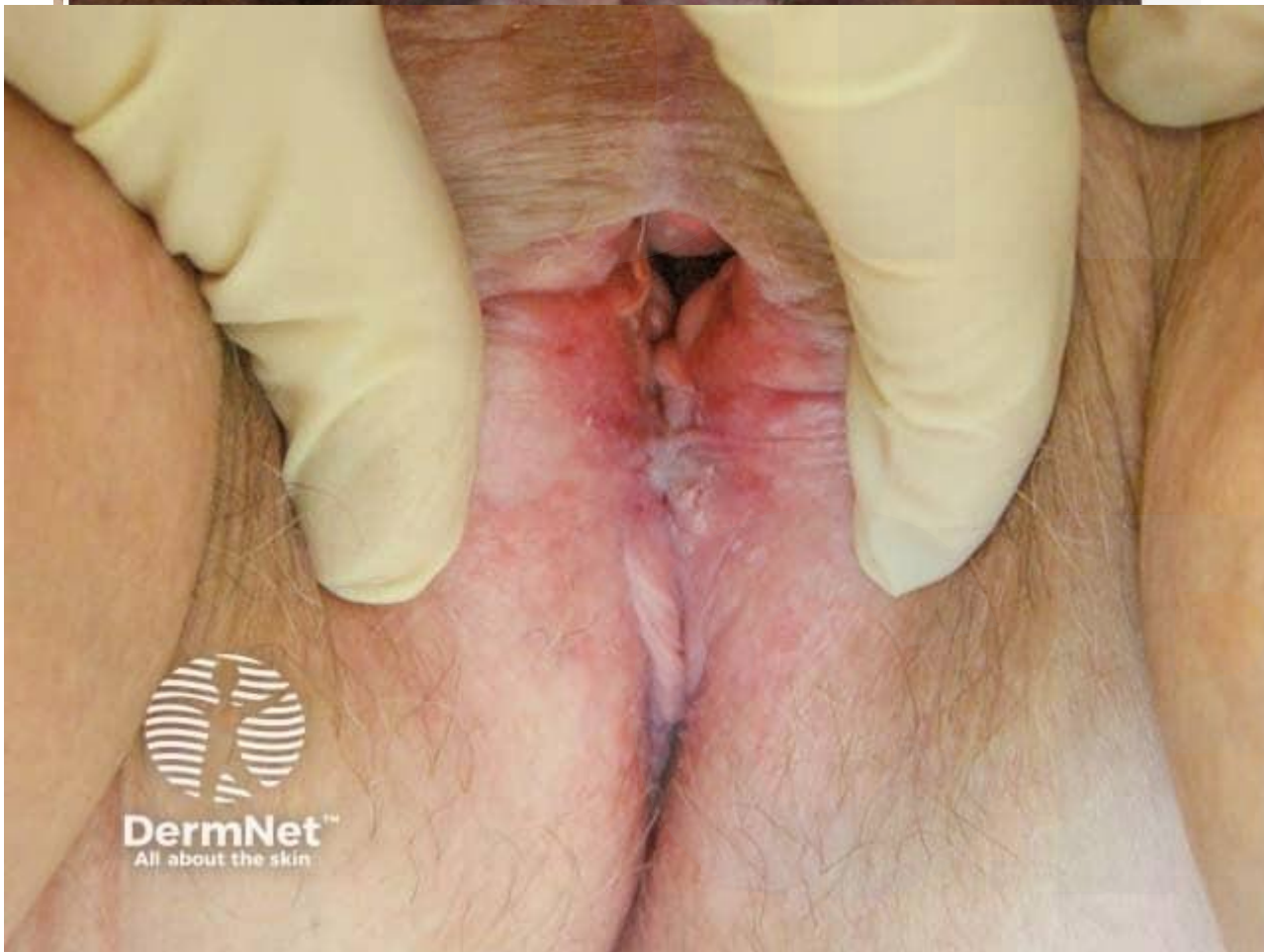
Vulvar Lichen Sclerosus

- Ivory lesions, atrophic skin
- Figure of 8 distribution
- Clitoral hood fuses
- Purpura, ecchymosis
- Perianal hyperkeratosis



Untreated lichen sclerosus can lead to squamous cell carcinoma



M Gutierrez-Pascual, Actas Dermo-Sifilio 2012
Goldsmith LA, Fitzpatrick's Dermatology, 8th Edition
Kacerovska D, JAADCR 2015; DermNetNZ.org



Genital lichen sclerosis treatment options

Flares:

- Clobetasol propionate 0.05% ointment twice daily x 2 weeks, then daily x 2 weeks
- Mometasone furoate 0.1% ointment twice daily x 2 weeks, then daily x 2 weeks

Maintenance:

- Clobetasol propionate 0.05% ointment two days per week
- Mometasone furoate 0.1% ointment two days per week
- Triamcinolone acetonide 0.1% ointment every other day**
- Hydrocortisone 2.5% ointment daily**

Please biopsy or refer if not responding to topical treatment!

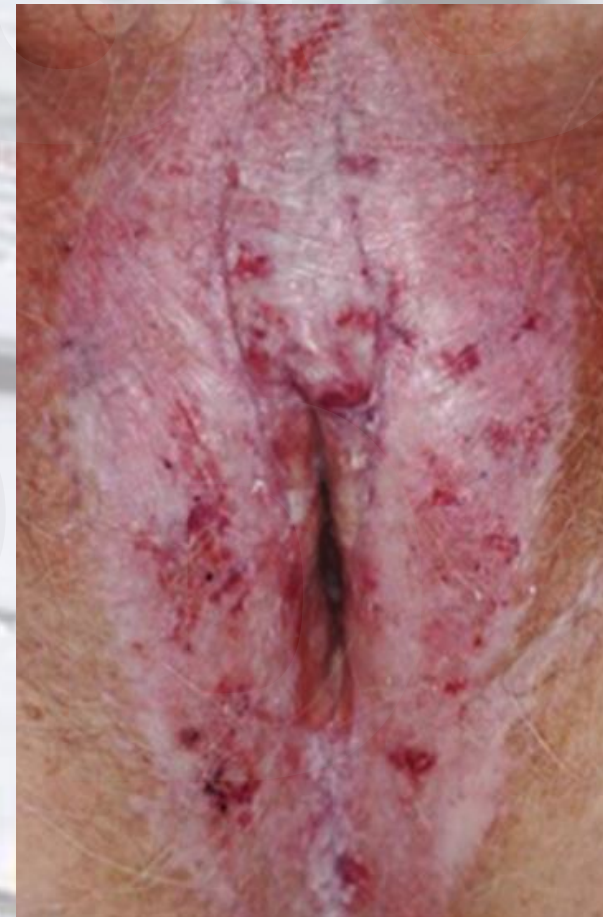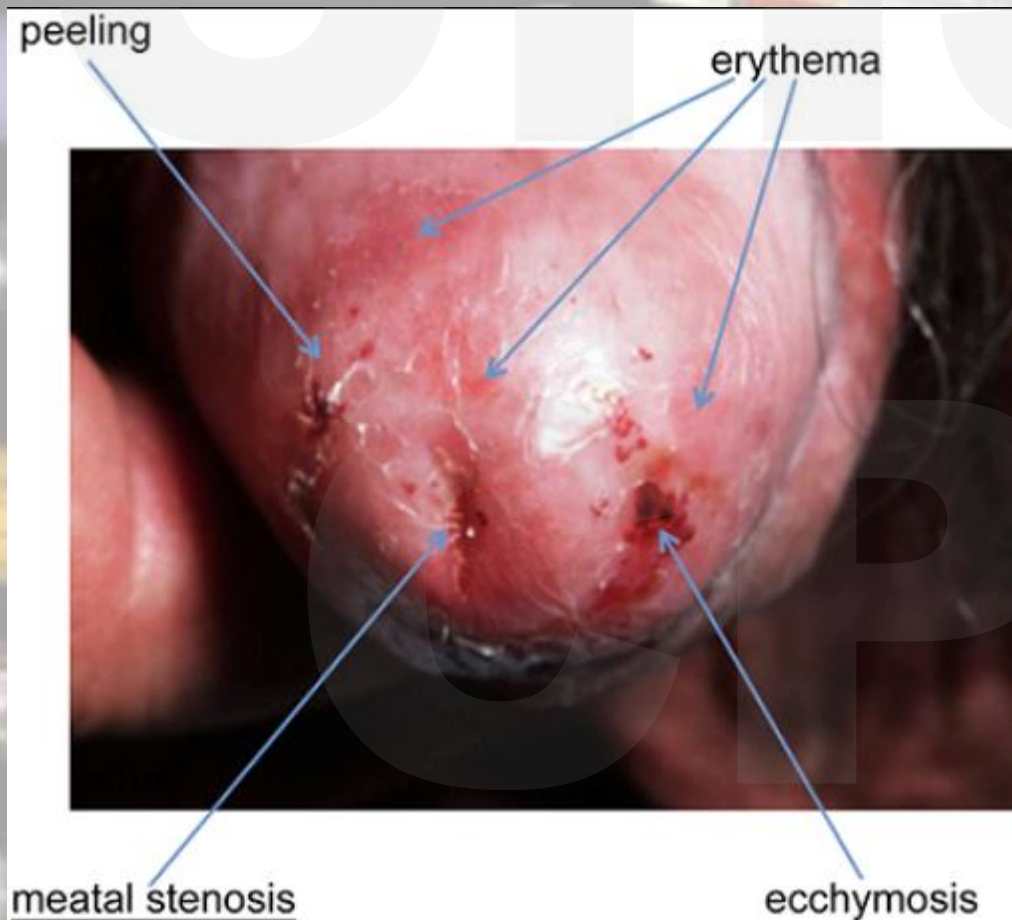
Oral prednisone 0.5 mg/kg daily

Methotrexate 15-25 mg/week

JAK inhibitors (upadacitinib, deucravacitinib)

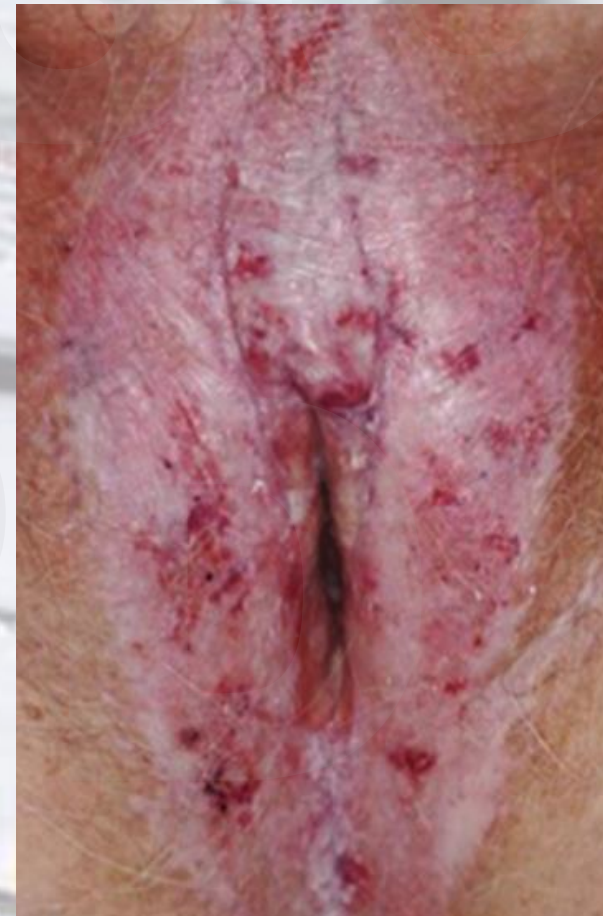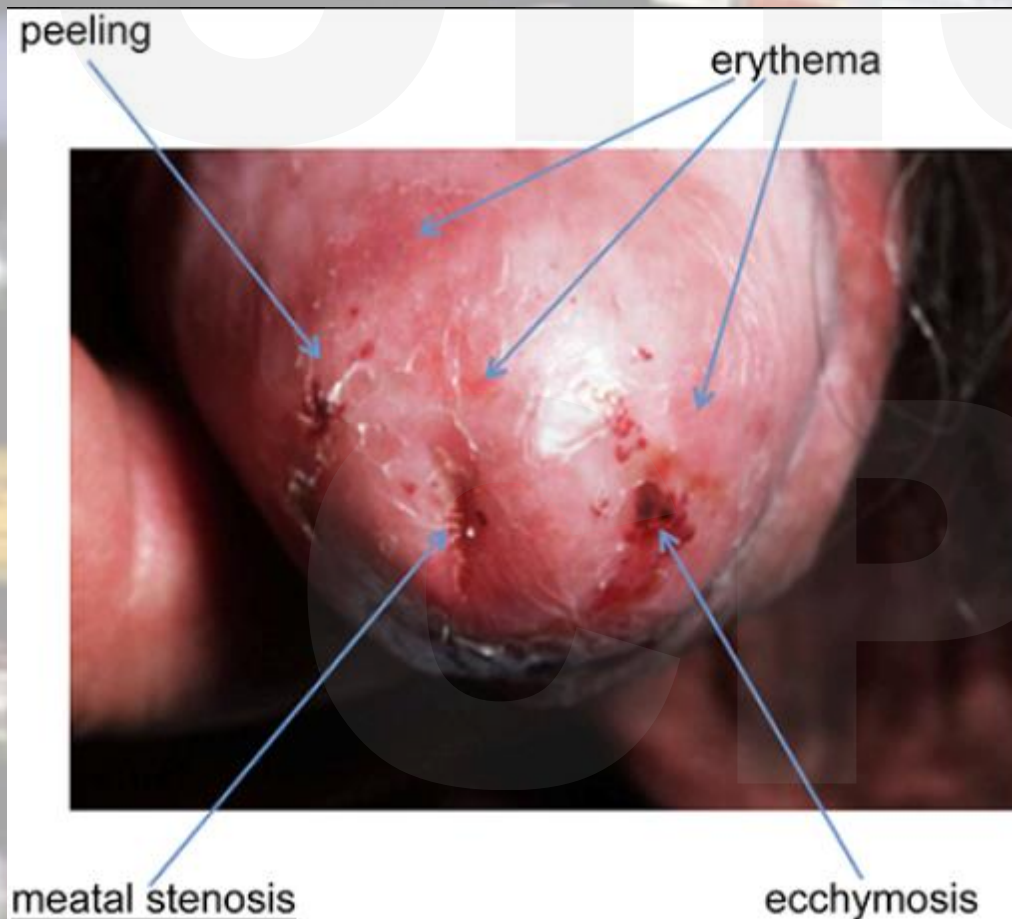
But what about steroid overuse?

1. Untreated (not overtreated) lichen sclerosus results in skin thinning



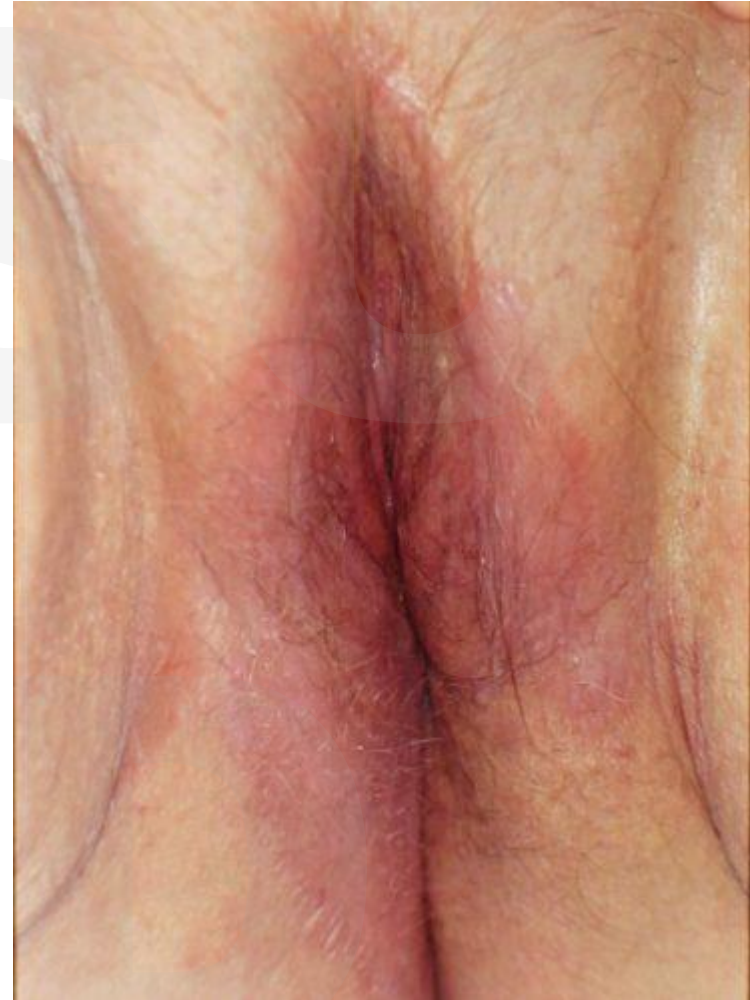But what about steroid overuse?

1. Untreated (not overtreated) lichen sclerosus results in skin thinning
2. Patients rarely overuse their topical steroids!

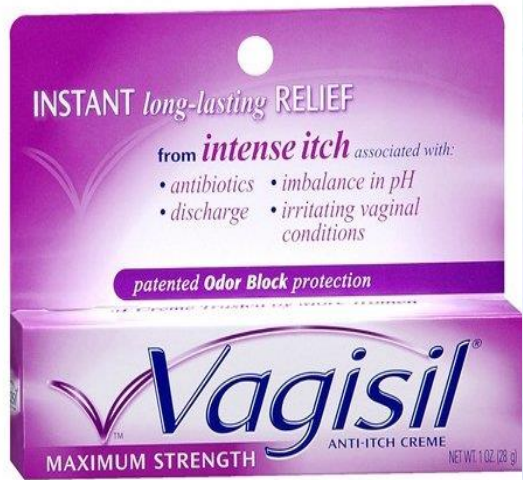

Case 4. Vulvovaginitis

- 35 yo G3P2 with pruritus, pain, blistering of vulva and vagina x months
- Well-demarcated erythema
- Ulcers, erosions
- Scaly rash



Contact dermatitis: Common Culprits



Drug
Active
Benzoc
Resorc

Use
■ temp

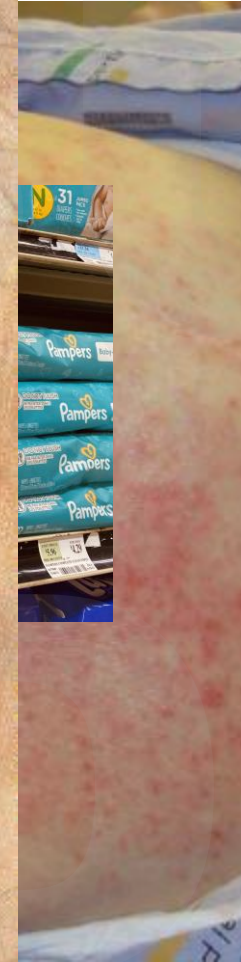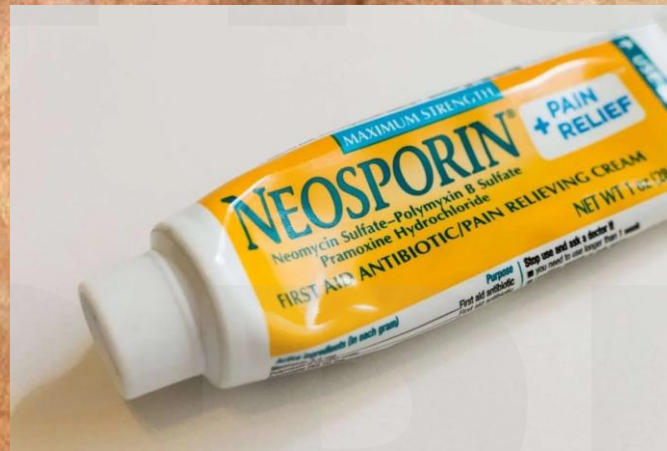Warn
For ex
Avoid

Stop u
sympt
occur

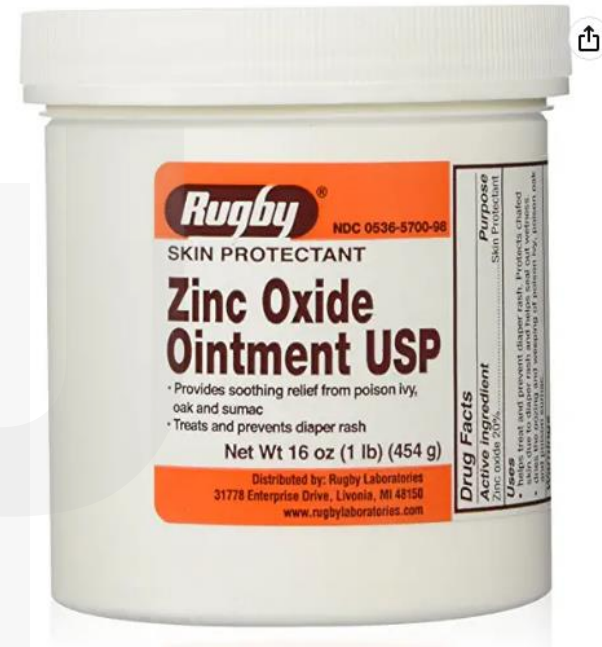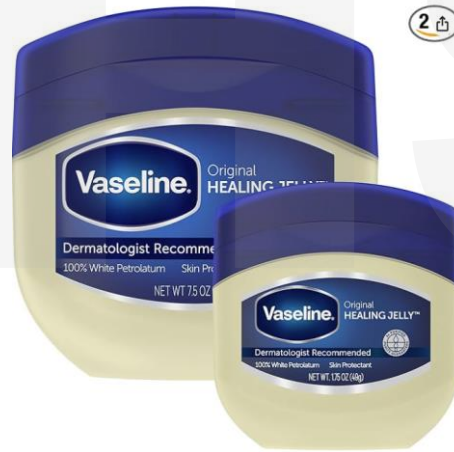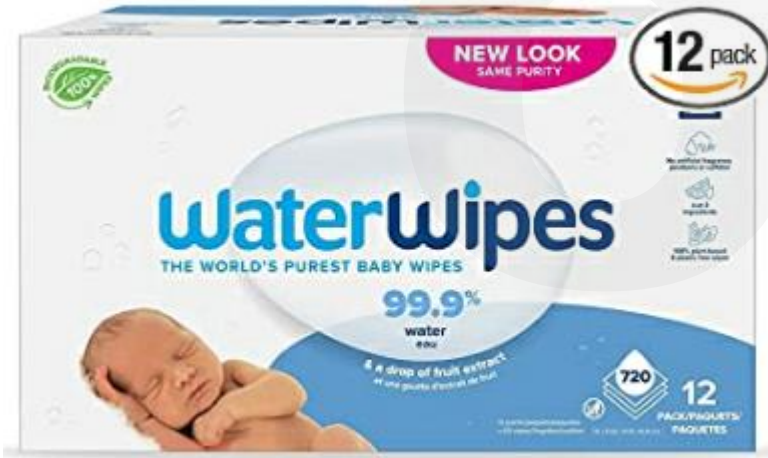Do no

Keep
help o

Direc
adults
years a



SAFE PRODUCTS to substitute



Bidet Attachments & Bidet Toilet Seats



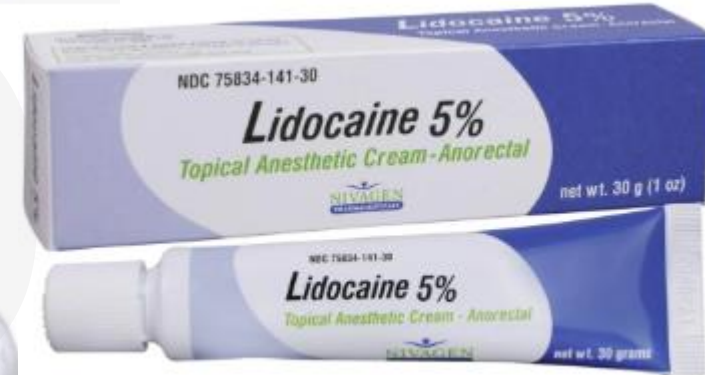TUSHY CLASSIC 3.0
★★★★★ (15,642)



TUSHY SPA 3.0
★★★★★ (7,429)



TUSHY ACE ELECTRIC
BIDET SEAT
★★★★★



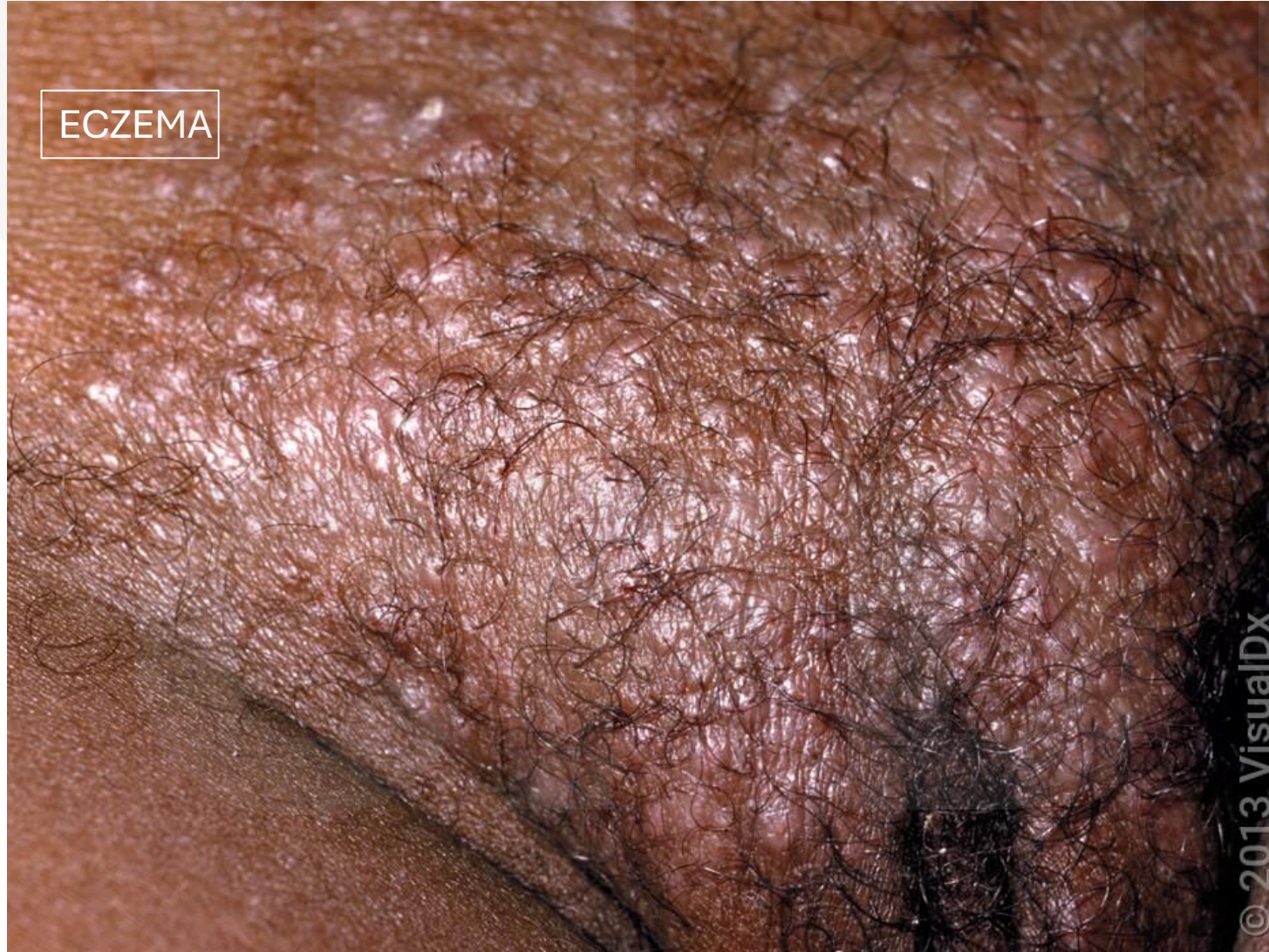Post-Test

- What is the most important step for patient comfort in mucosal biopsies?
 - Use plenty of topical and injected anesthetics and WAIT
- What are 2 safe options for topical steroids on mucosa?
 - Clobetasol ointment or gel, dexamethasone solution, triamcinolone paste
- What are 3 possible underlying causes of recurrent canker sores?
 - Behcet's, Crohns/Ulcerative Colitis, cyclic neutropenia, HIV, AML, nutritional deficiency
- What workup is helpful for complex aphthosis?
 - HIV, RPR, CBC, iron/TIBC, serum vitamin B, zinc, fecal calprotectin
- What features of gingivitis point toward an autoimmune cause?
 - Desquamation, erythema, other oral sites, good dentition
- What is the differential diagnosis for balanitis?
 - Atopic dermatitis, psoriasis, tinea cruris, lichen sclerosus
- What are major causes of contact dermatitis?
 - Personal care wipes, Neosporin, Vagisil, incontinence pads
- What are safe alternatives to prevent vulvar contact dermatitis?
 - Vaseline, mineral oil, coconut oil, Water Wipes, zinc oxide, LIDOCAINE

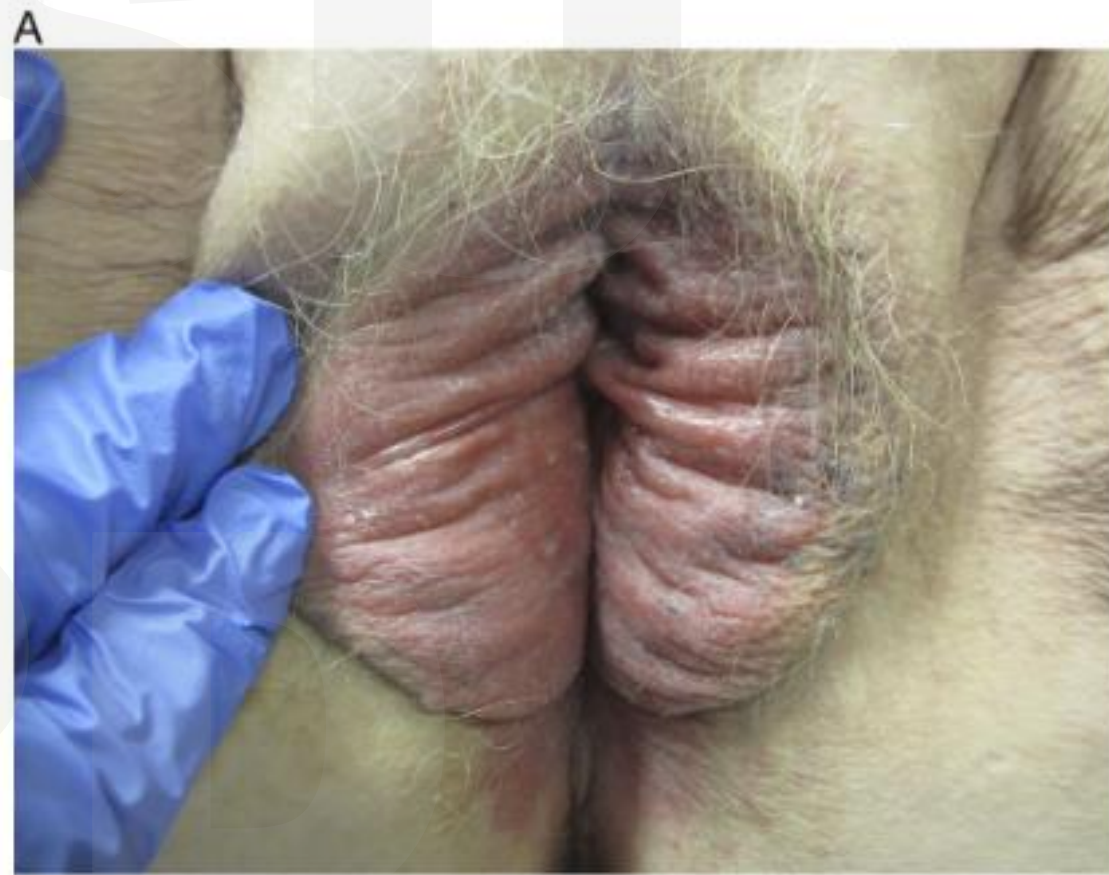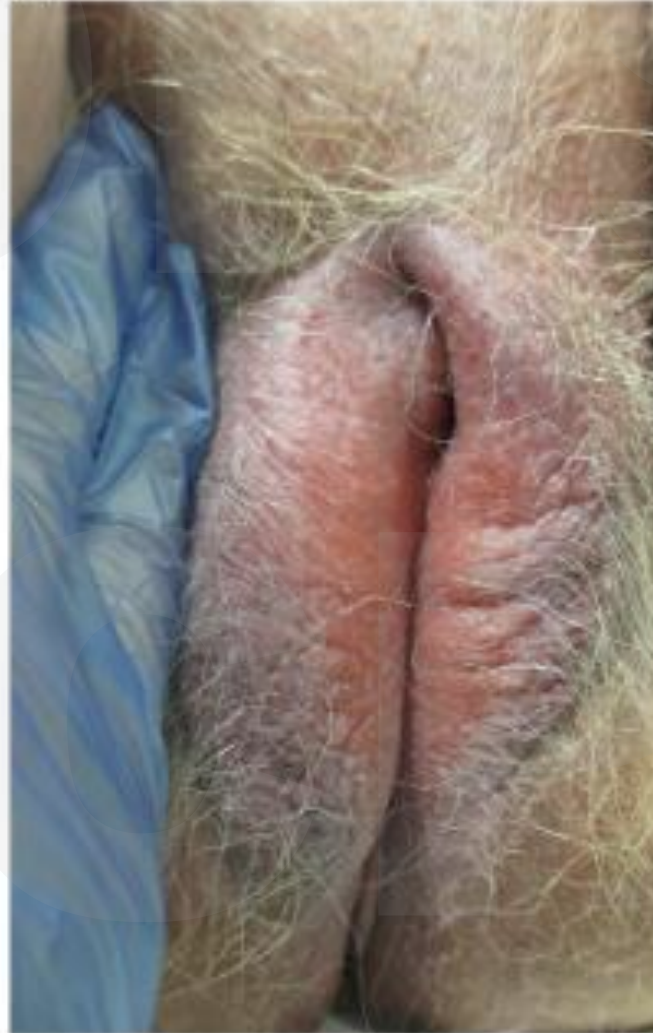Please ask questions during the panel!



Lichen Simplex Chronicus Pruritus Ani, Pruritus Scroti

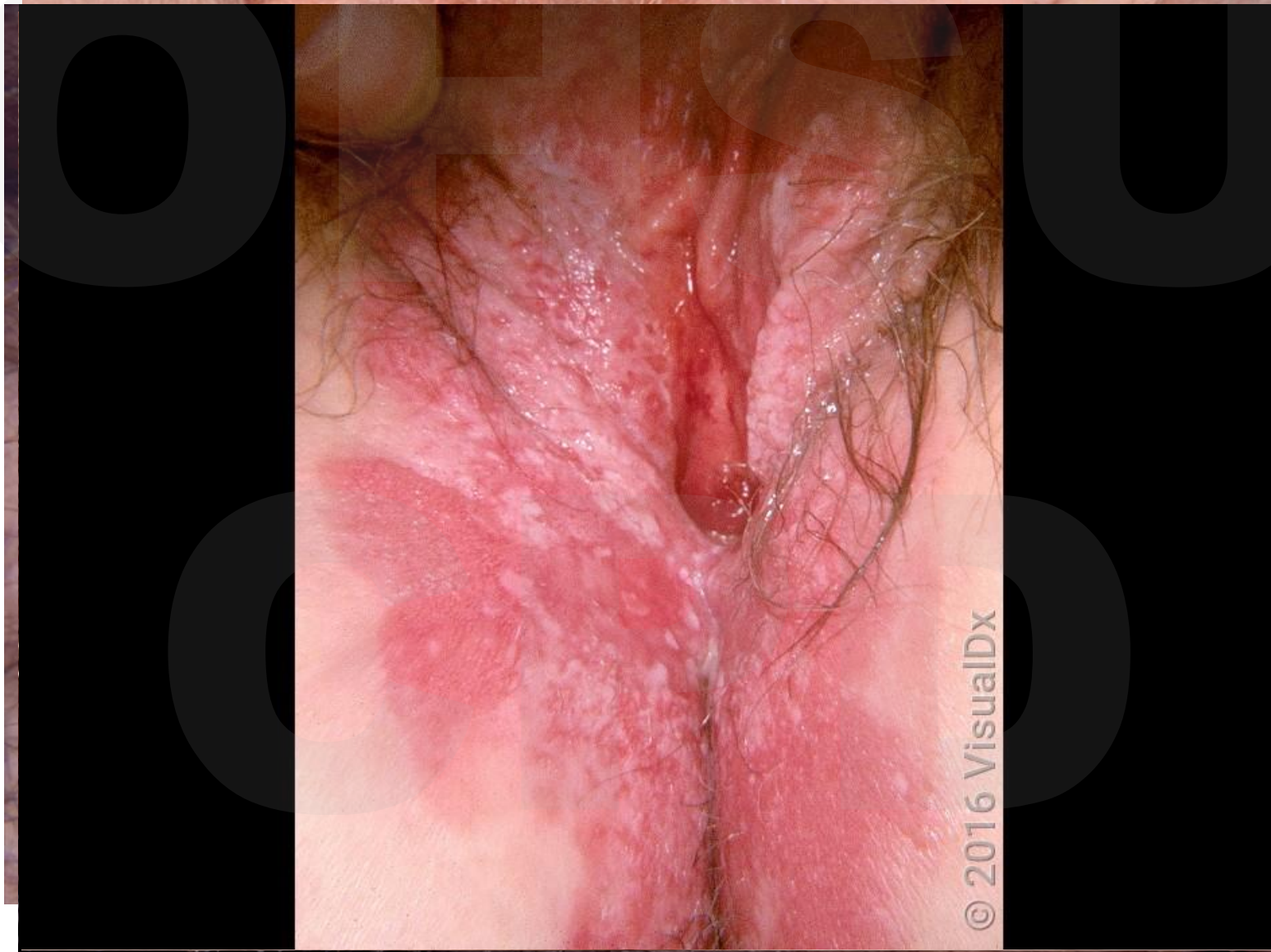

Vulvar Lichen Planus- Hypertrophic

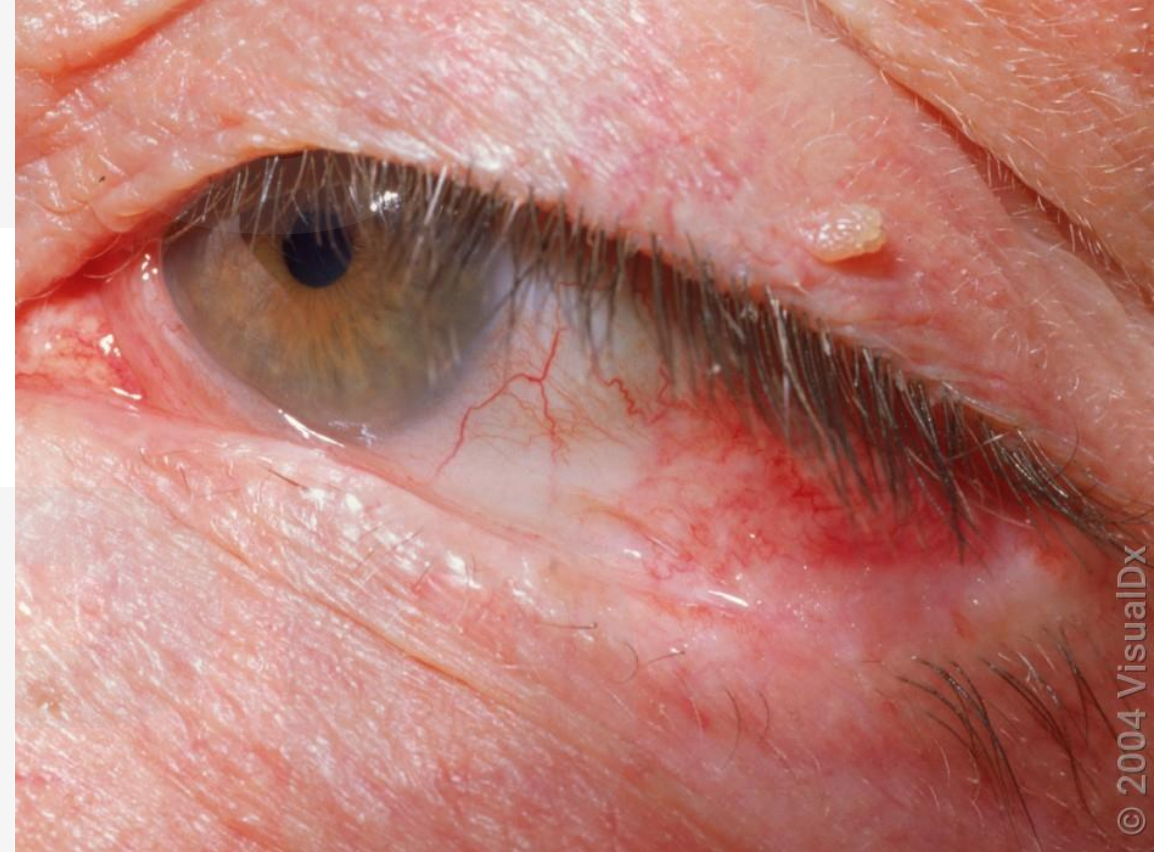
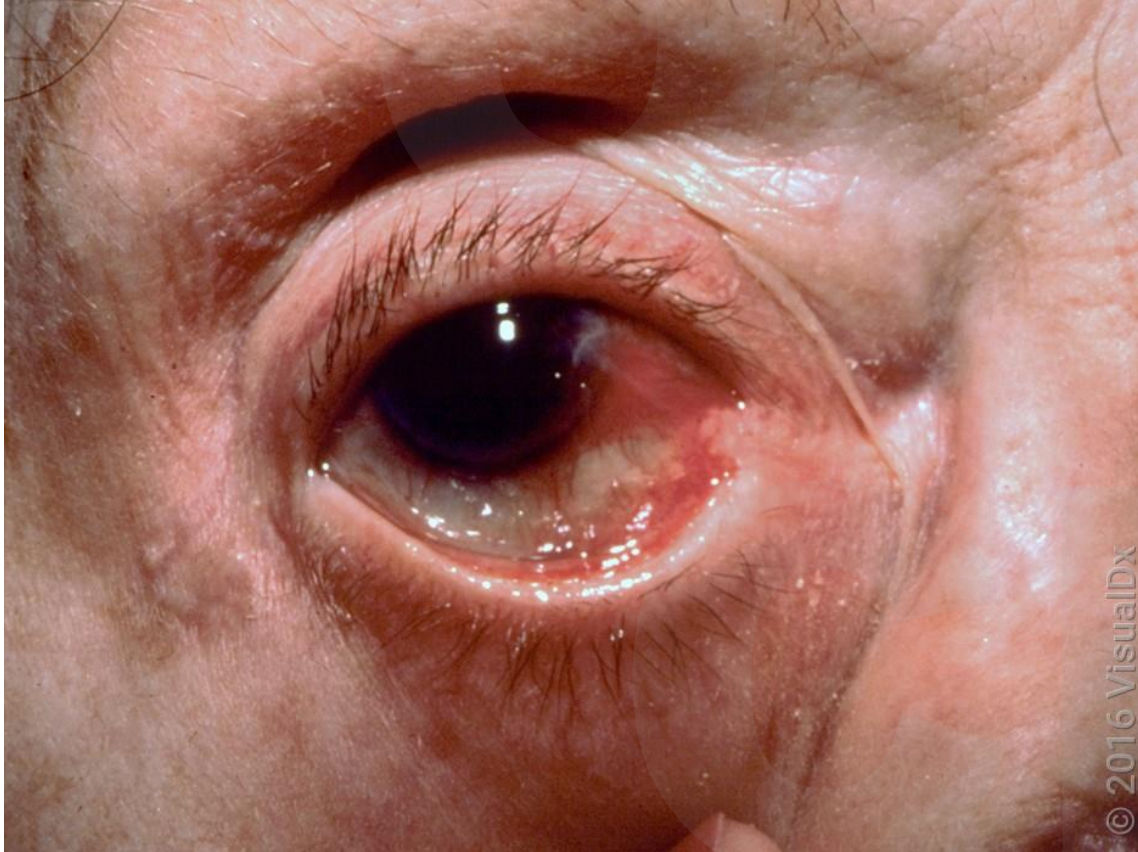

Extramammary Paget's Disease

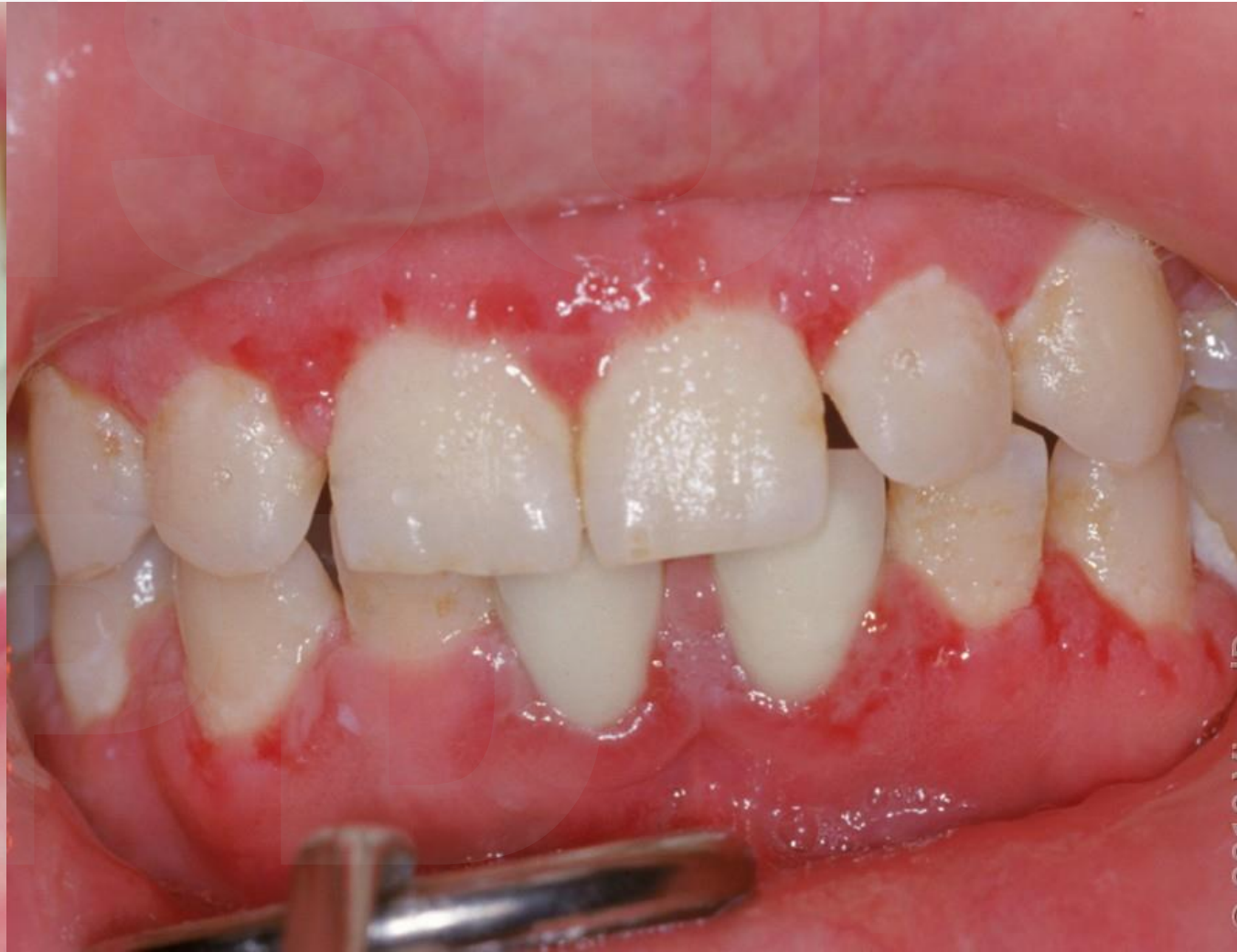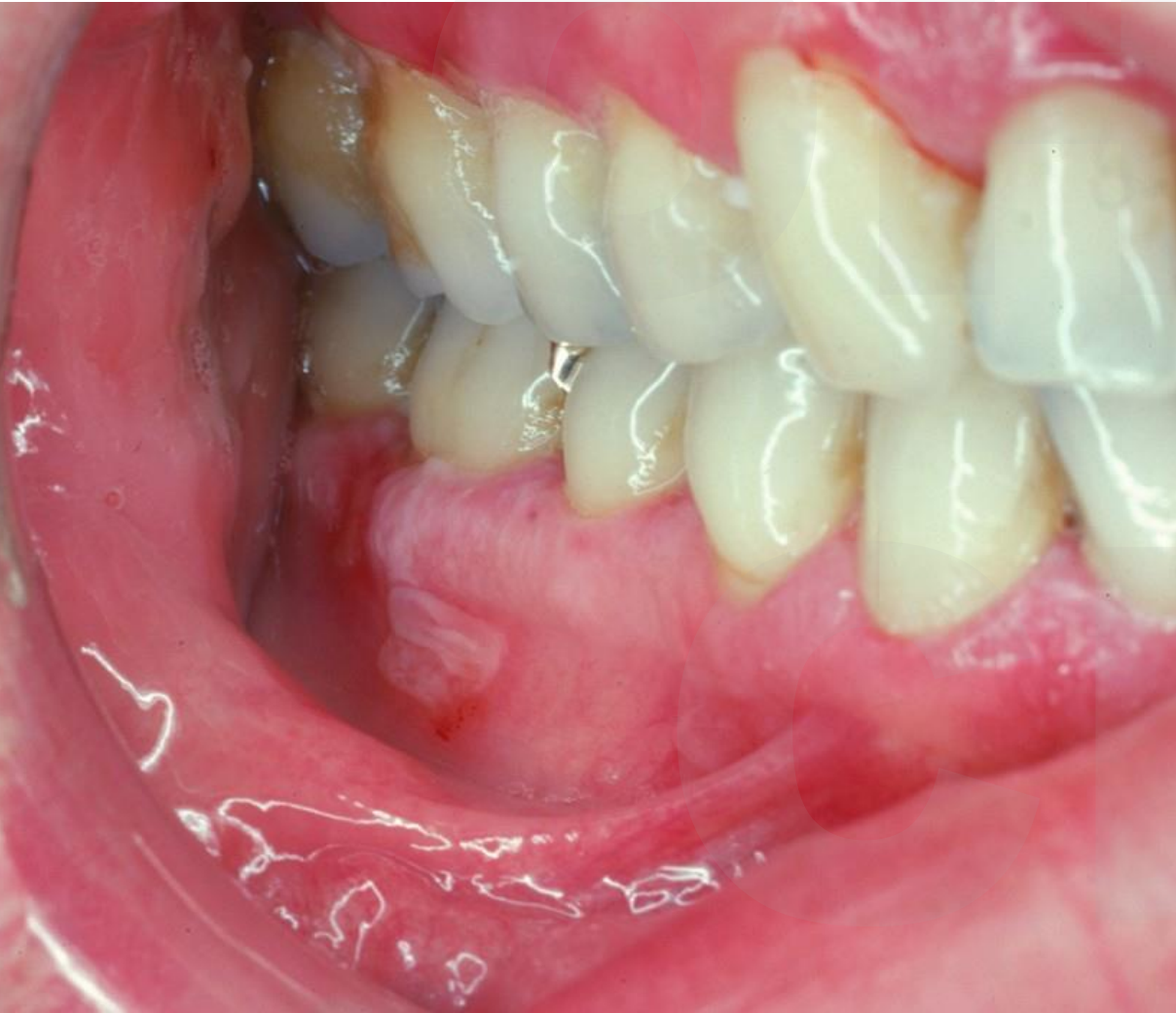Please biopsy this!



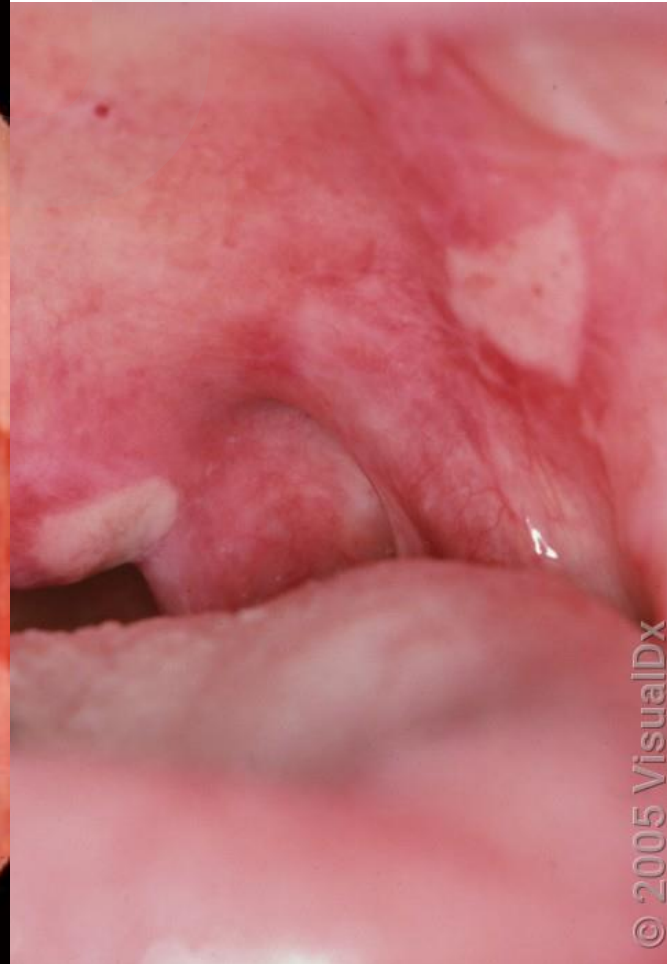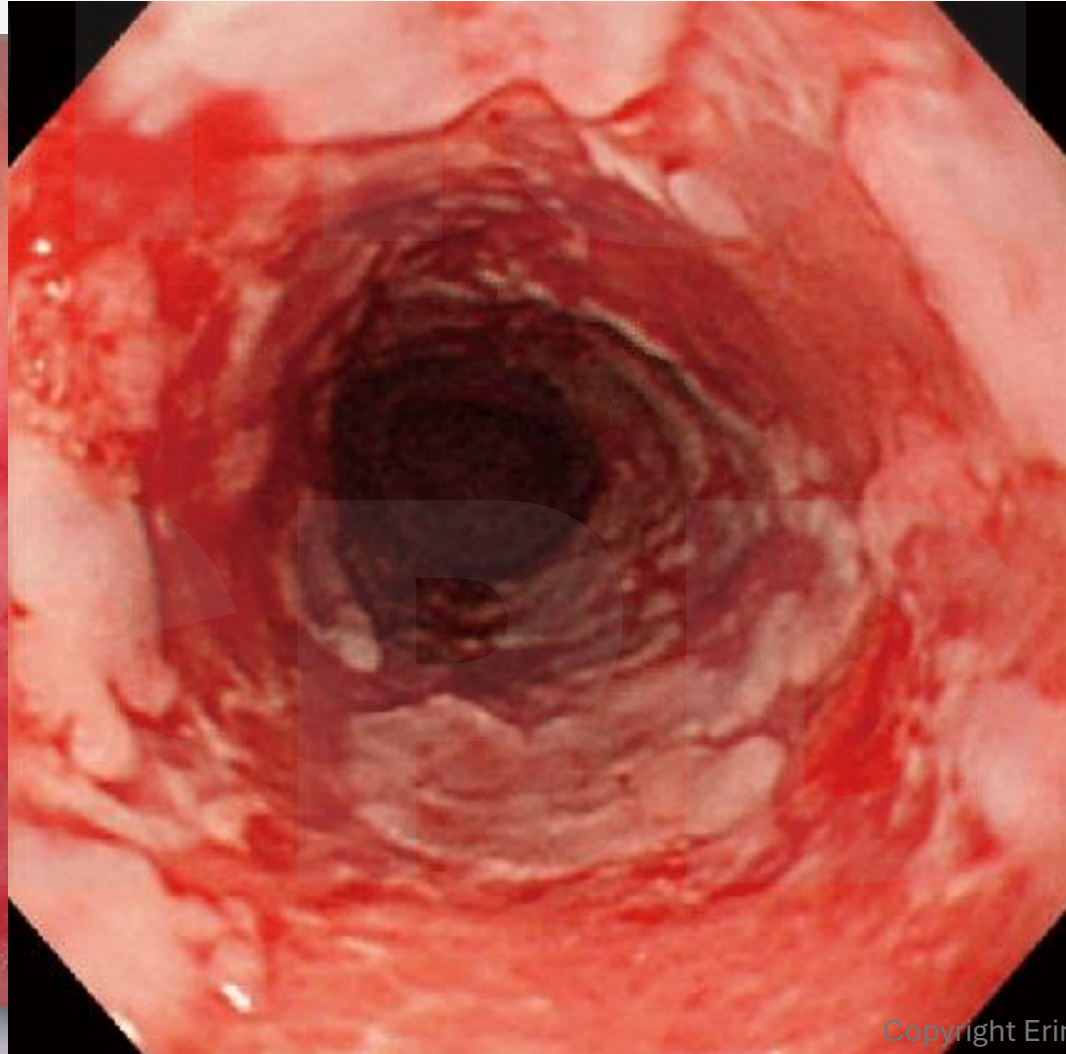
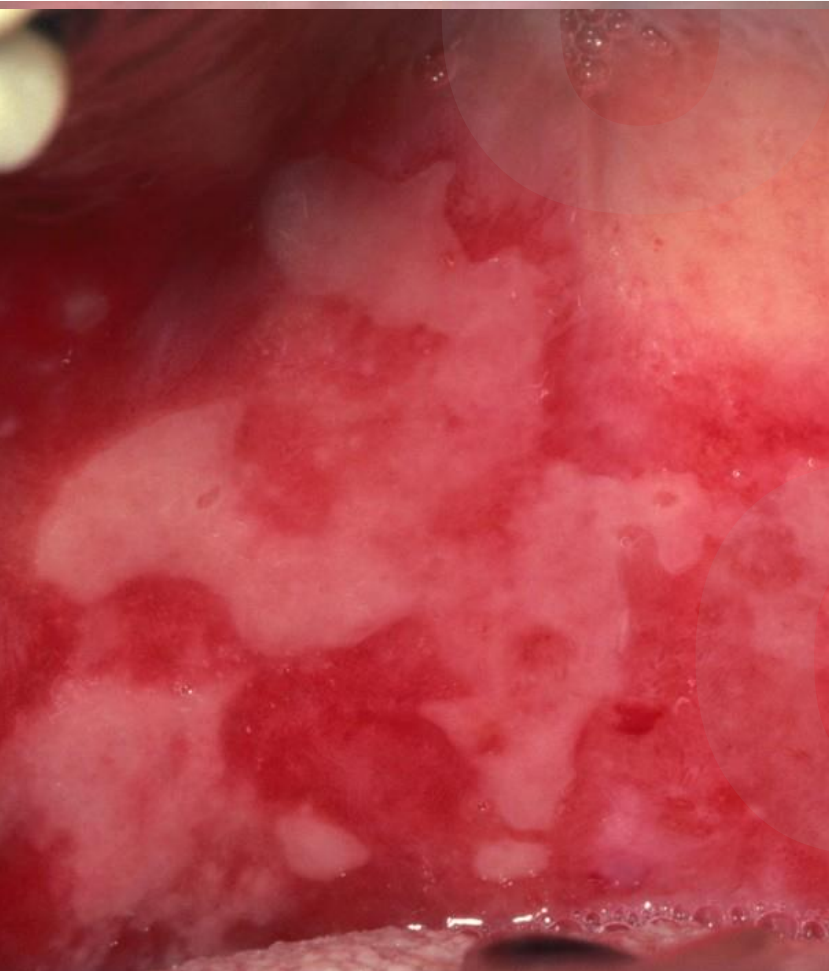
Mucous Membrane Pemphigoid: ocular



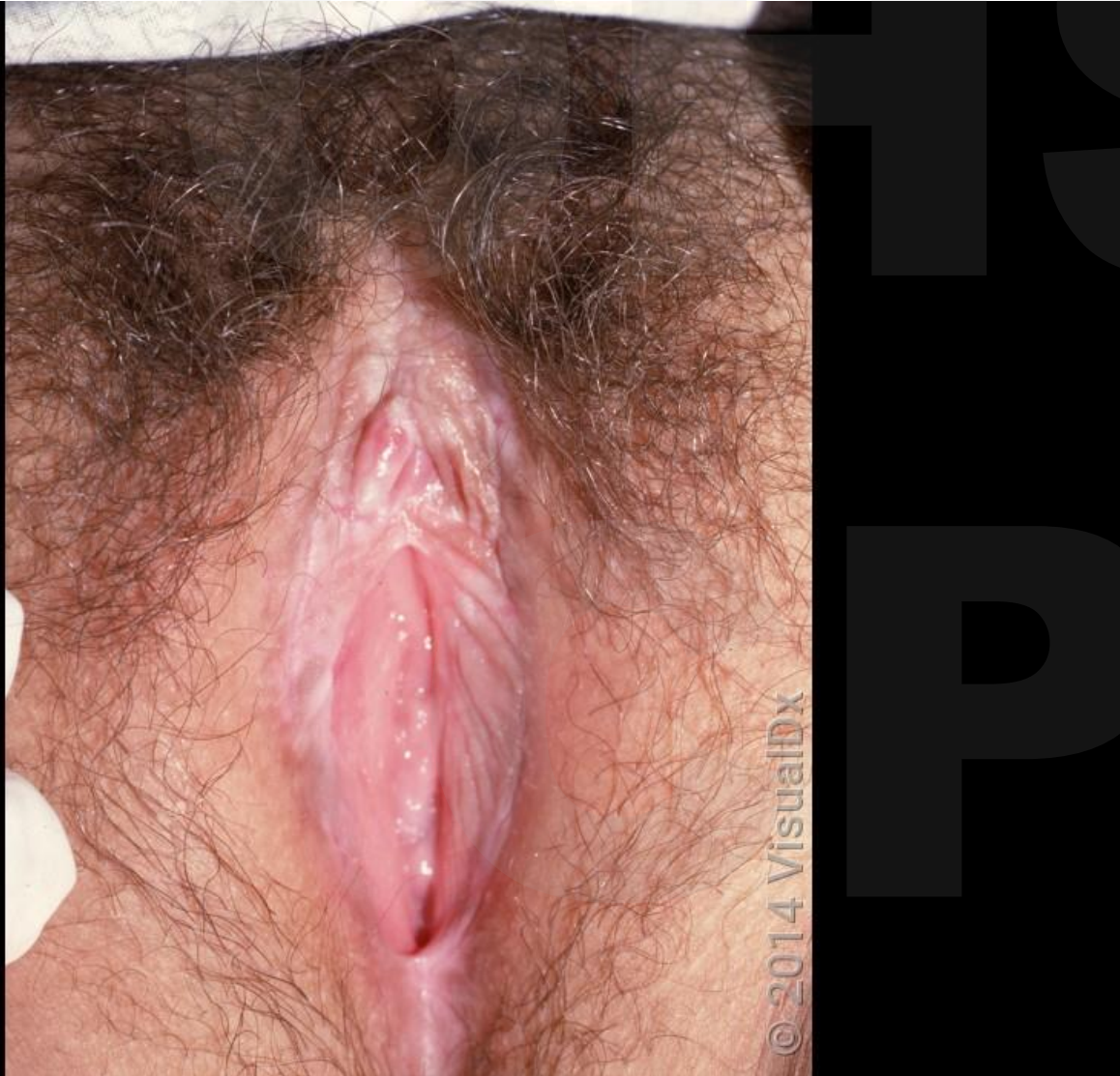Mucous Membrane Pemphigoid: oral



Mucous Membrane Pemphigoid: oropharyngeal, esophageal



Mucous Membrane Pemphigoid: anogenital



Symptoms and signs:

Bleeding

Pain

Incontinence

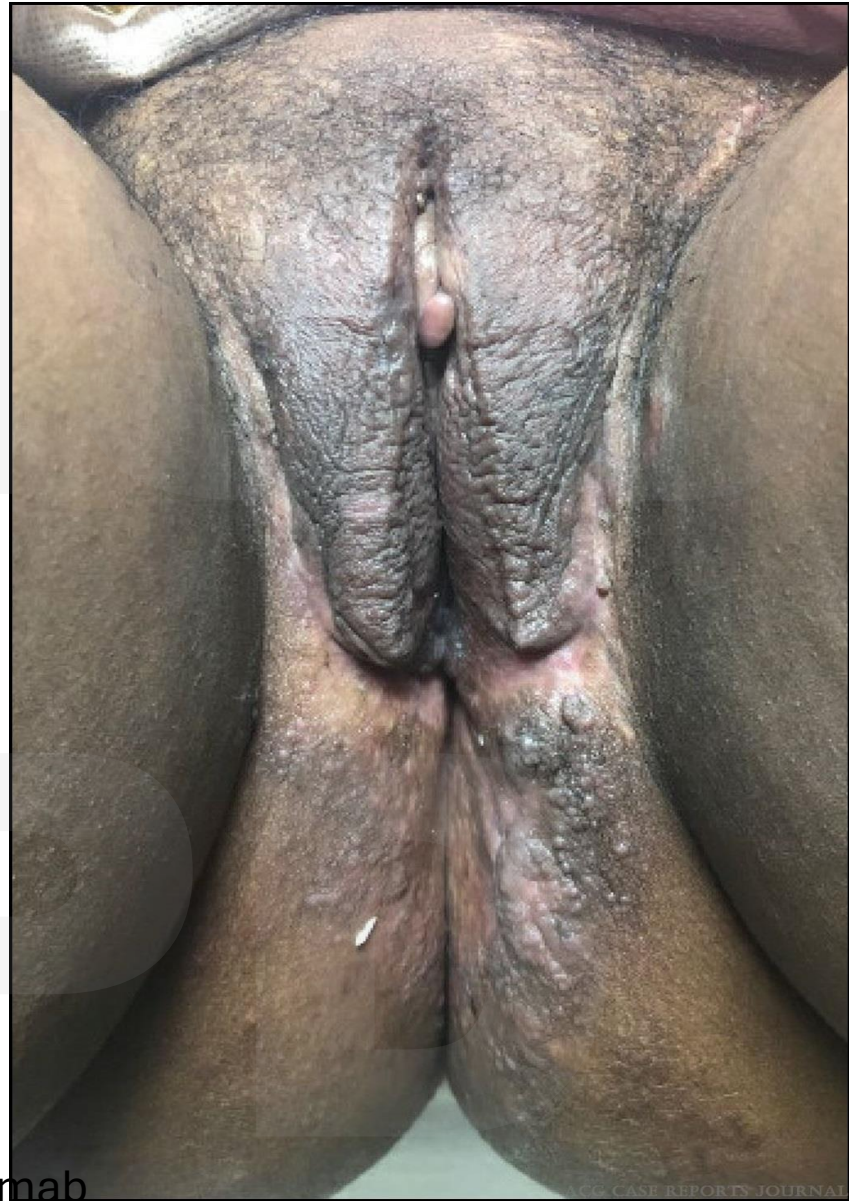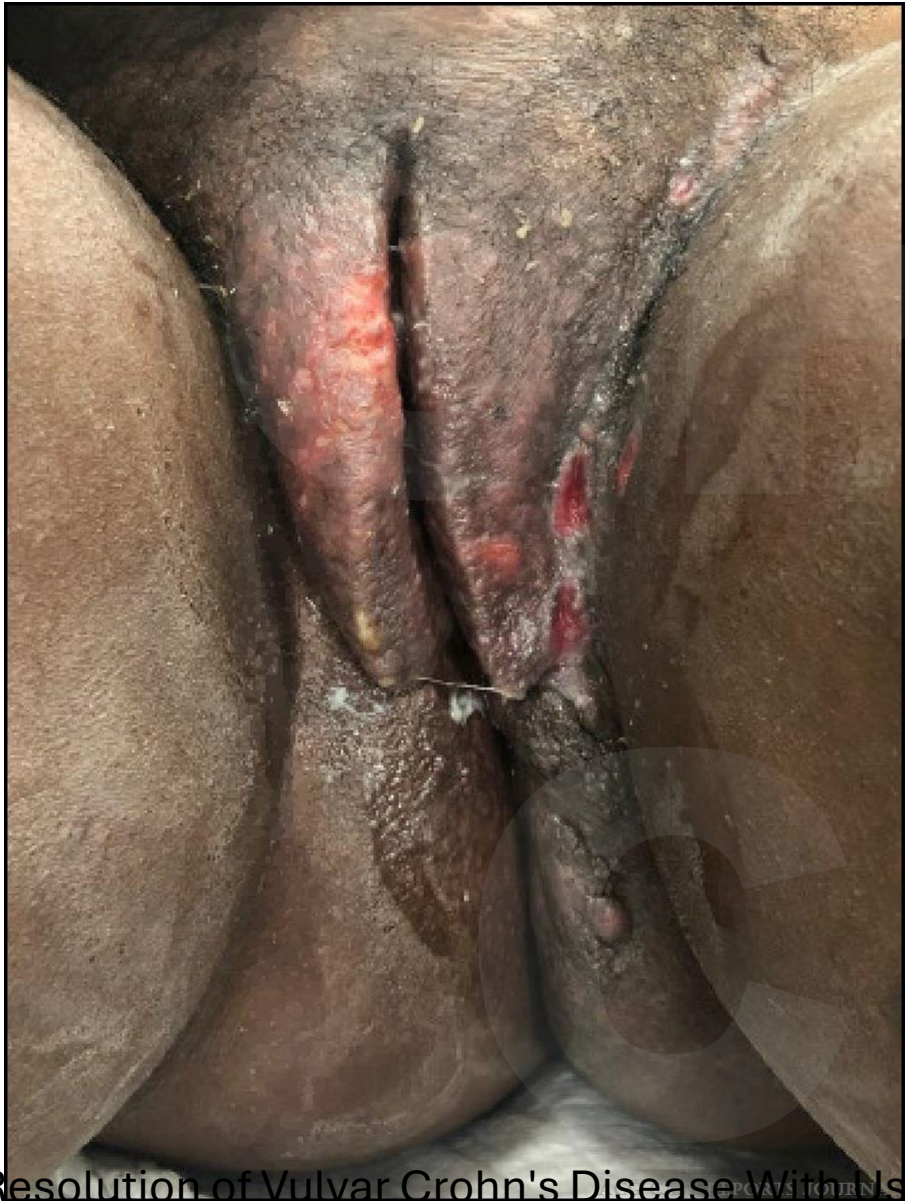Dysuria

Erosions

Ulcers

Scarring

Rare intact blisters



Rapid Resolution of Vulvar Crohn's Disease With Ustekinumab

Stoleru, Gianna MD¹; Robbins, Gordon MD²; Papadimitriou, John C. MD, PhD³; Wong, Uni MD²

Author Information ACG Case Reports Journal: August 2020 - Volume 7 - Issue 8 - p e00452

Copyright Erin Foster 2026 Do Not Copy Without Permission

Topical Steroid Potency



Class 1
superpotent

Clobetasol 0.05%
Fluocinonide 0.1%

Class 2
potent

Betamethasone
Desoximetasone,
Fluocinonide

Class 3
upper mid

Triamcinolone 0.5%

Class 4
mid-strength

Triamcinolone 0.1%
Mometasone furoate
0.1%

Class 5
lower mid

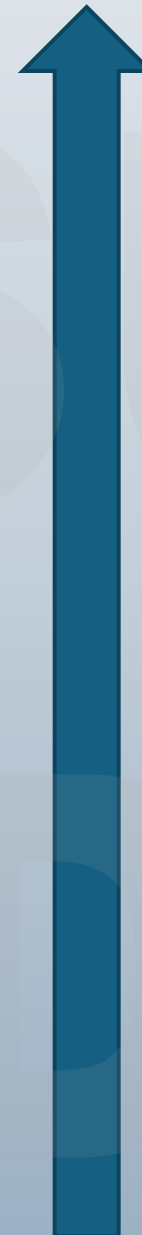Triamcinolone 0.025%

Class 6
mild

Desonide 0.05%
Fluocinolone 0.01%

Class 7
least potent
Clobetasol propionate

Hydrocortisone 1%
Hydrocortisone 2.5%



Let's talk about sex...

Women with genital disease abstain from sex or have painful sex

"I feel bad for my husband"

"If I drink alcohol it's not as painful"

"I've never enjoyed sex"

"I wish he had a girlfriend just for sex"

"I love her but I don't think she knows that"

"I grit my teeth until it's over"

"I just do it because I have to"

"I just assumed I would never have a normal intimate relationship"

"We find other ways"

Regular dilator use helps keep vaginal opening patent, prevents scarring and reduces need for surgery in the future


Helgesen et al, AOGS, 201
Hopeandher.com
IntimateRose.com
Amazon.com




FULL VAGINAL DILATOR SET 8 SIZES
\$ 179.99



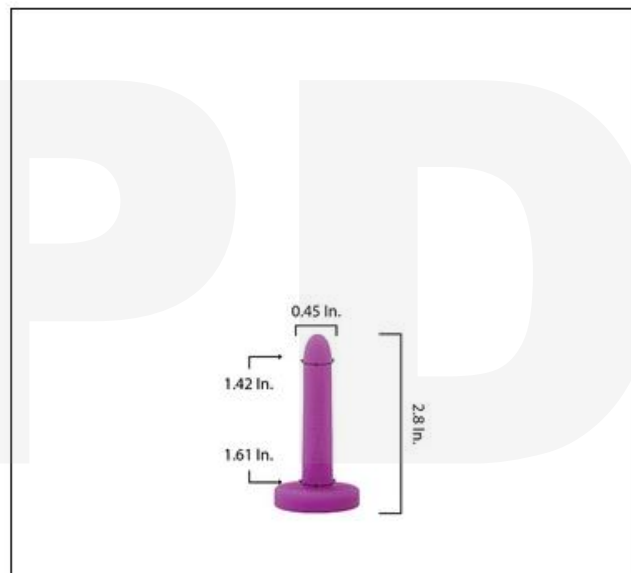
SMALL VAGINAL DILATORS SET
\$ 79.99




MEDIUM VAGINAL DILATOR SET
\$ 99.99



LARGE VAGINAL DILATOR SET

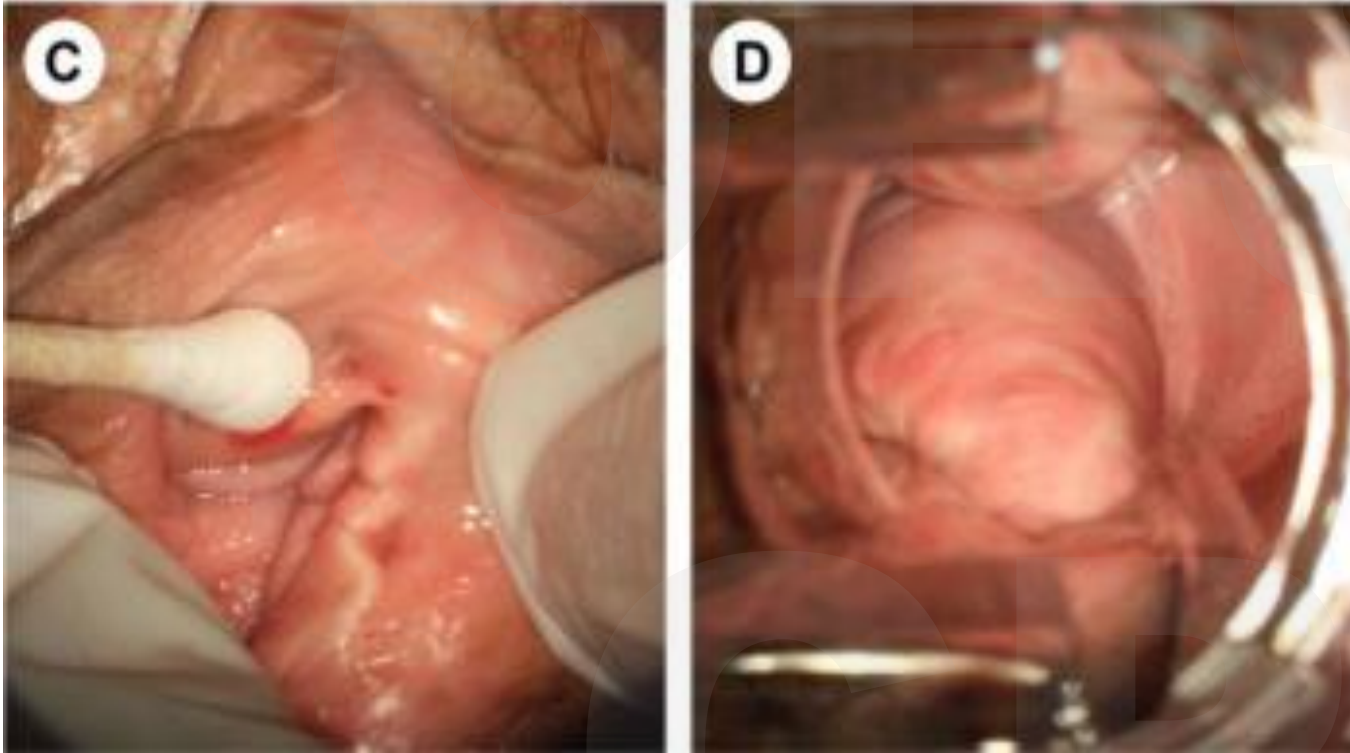


SILICONE DILATOR SIZE 1



SILICONE DILATOR SIZE 2

A quick note about estrogen...



Topical estrogens: Premarin, Estradiol, Estrace, Vagifem, Estring
Safe to use twice weekly

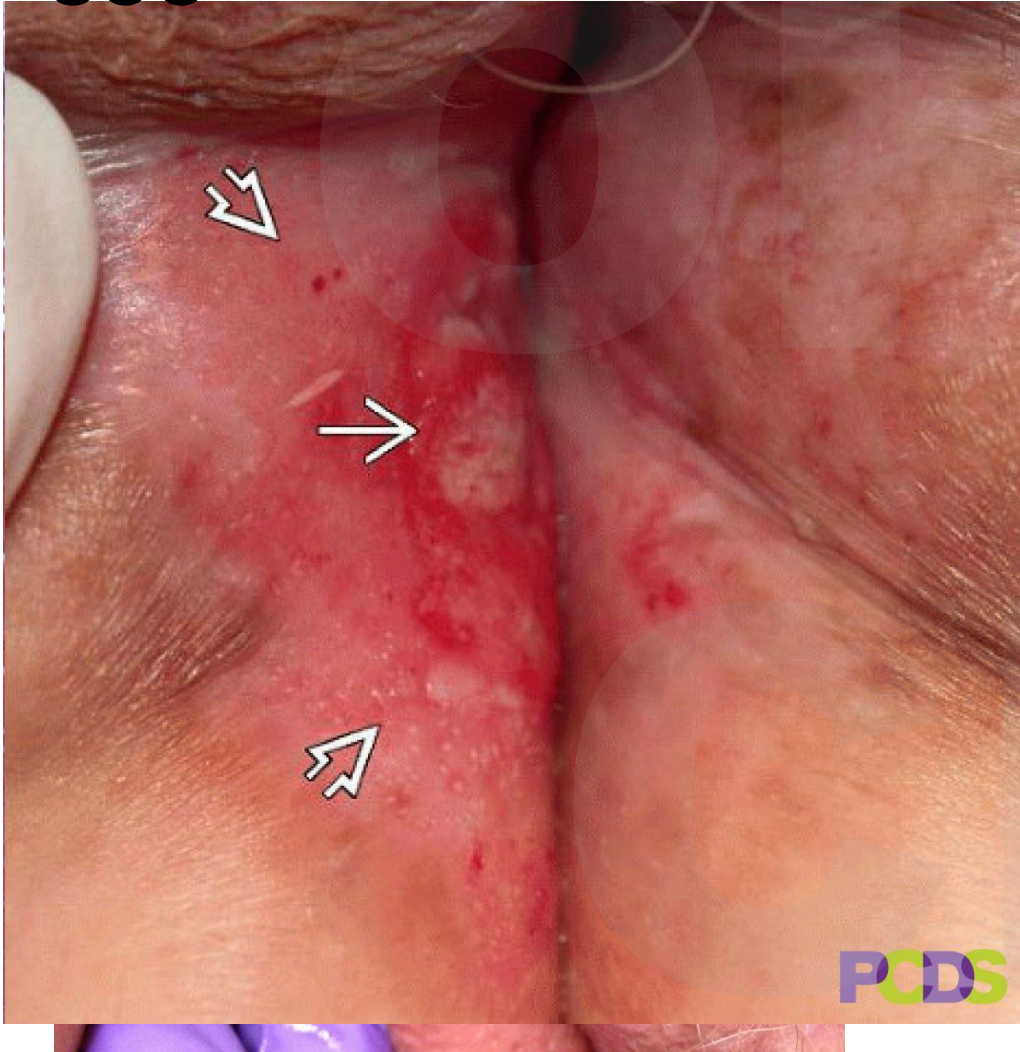
Symptoms of low estrogen

- Pain with intercourse
- Vaginal dryness, itching
- Burning
- Soreness
- Irritation
- Urinary discomfort, incontinence

Signs of low estrogen

- Pale appearance
- Thinning of vaginal tissue
- Friable
- Narrowing of introitus
- Petechiae, microfissures
- Enlarged, red ureter

Vulvar dysplasia, Vulvar Intraepithelial Neoplasia (VIN) and SCC



- Single lesions
- Unilateral disease
- Thickened lesions
- Not healing with treatment

Biopsy for dysplasia

****It is RARE for vulvar lichen planus to develop into SCC, but VIN and SCC can resemble hypertrophic or erosive LP ****

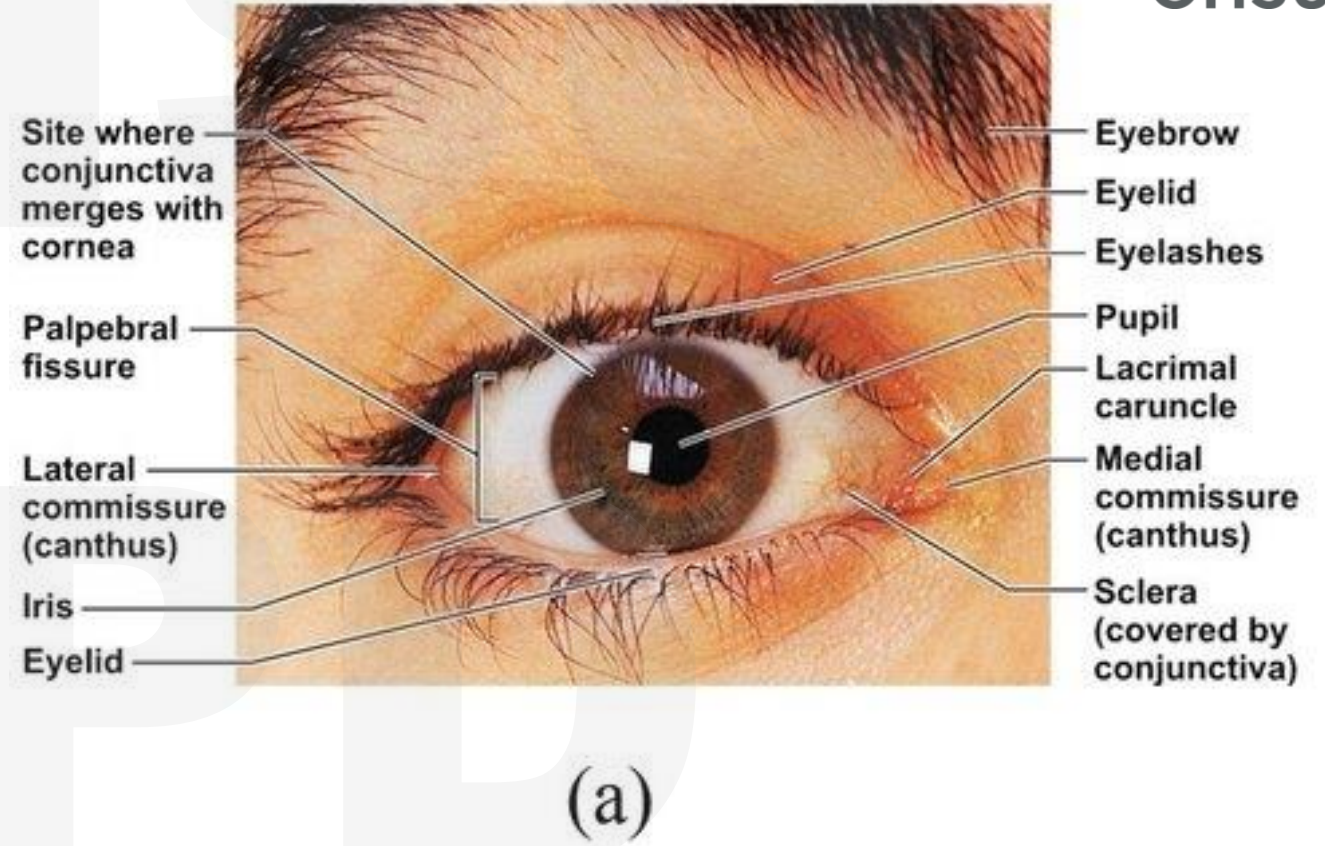
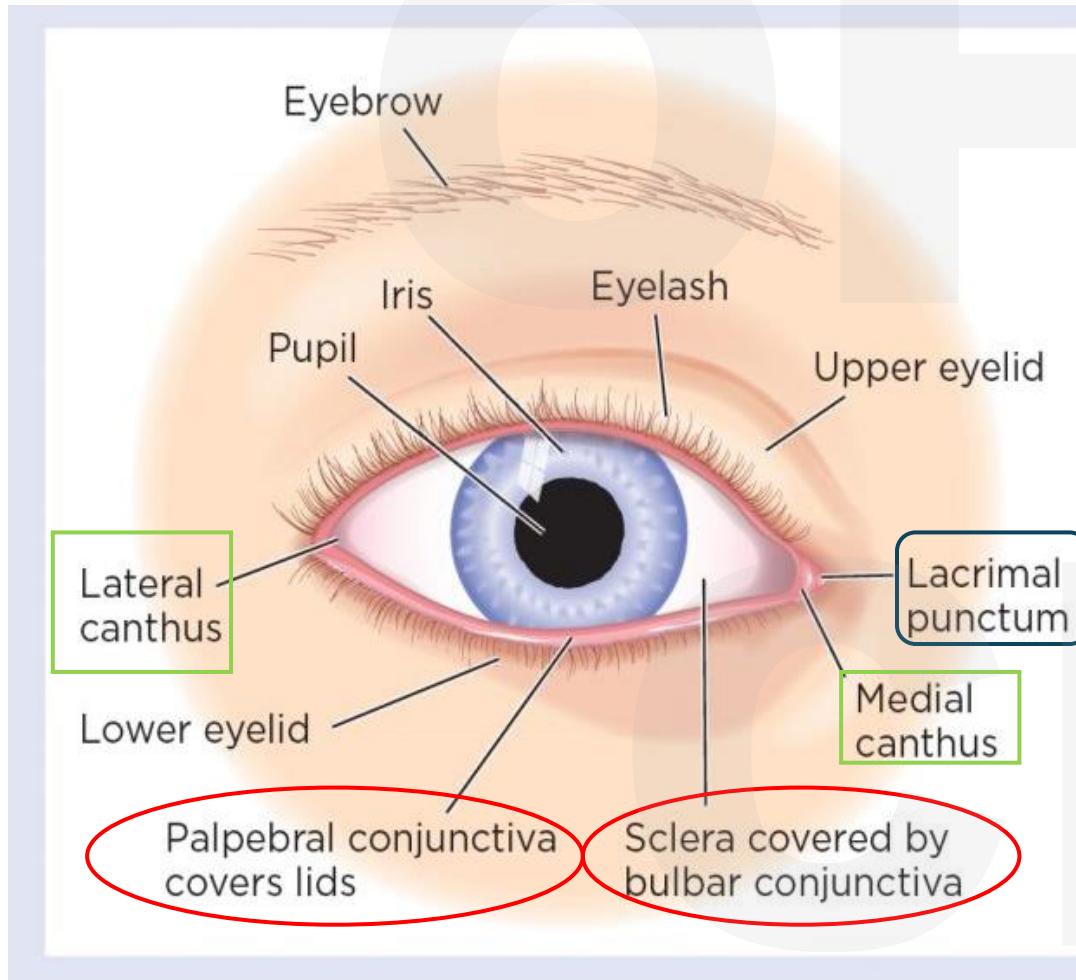
OHSU

CPD

OHSU

CPD

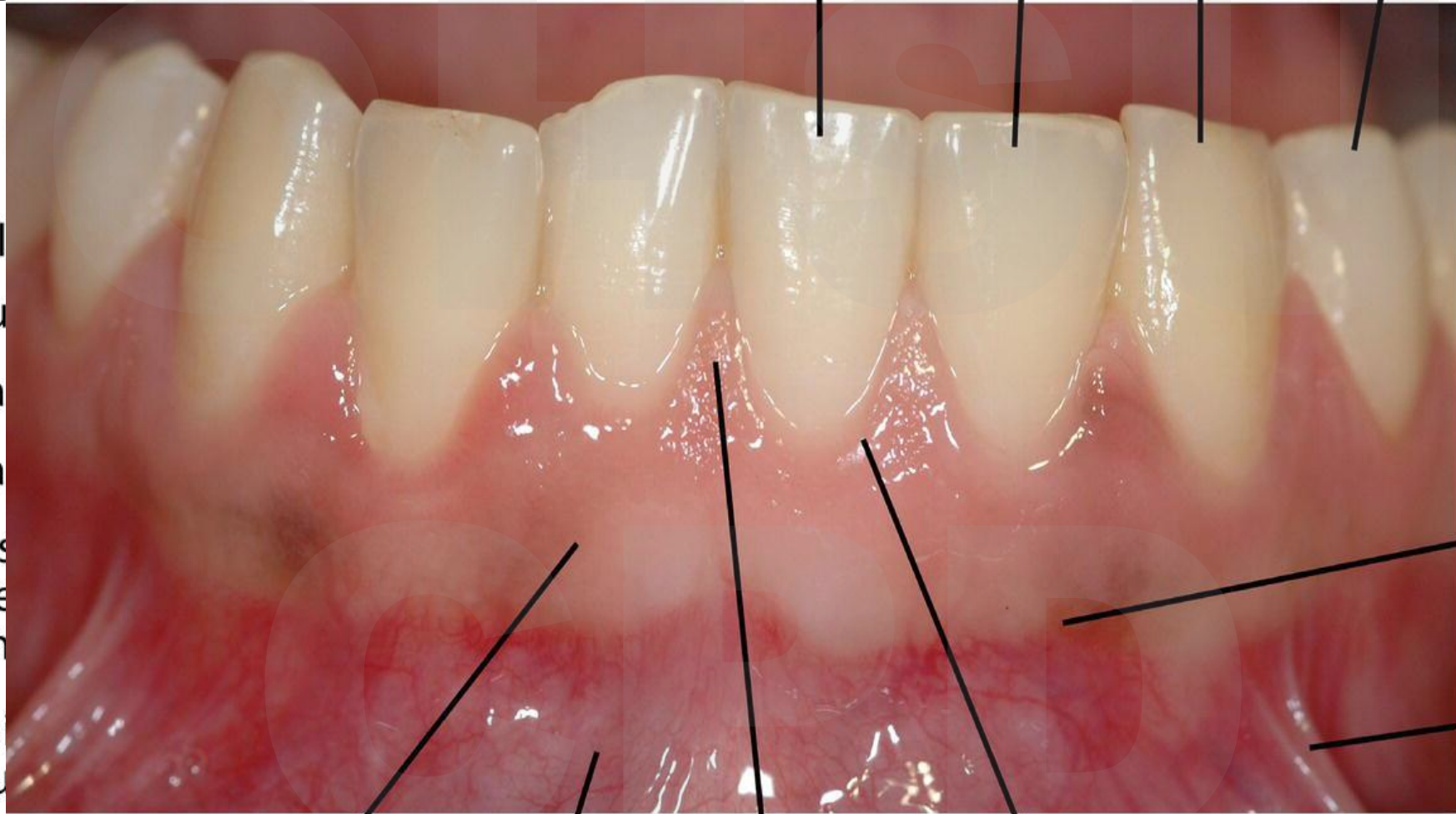
Anatomy of the External Eye



Anatc



Mandibular incisors
Central Lateral Canine 1st premolar

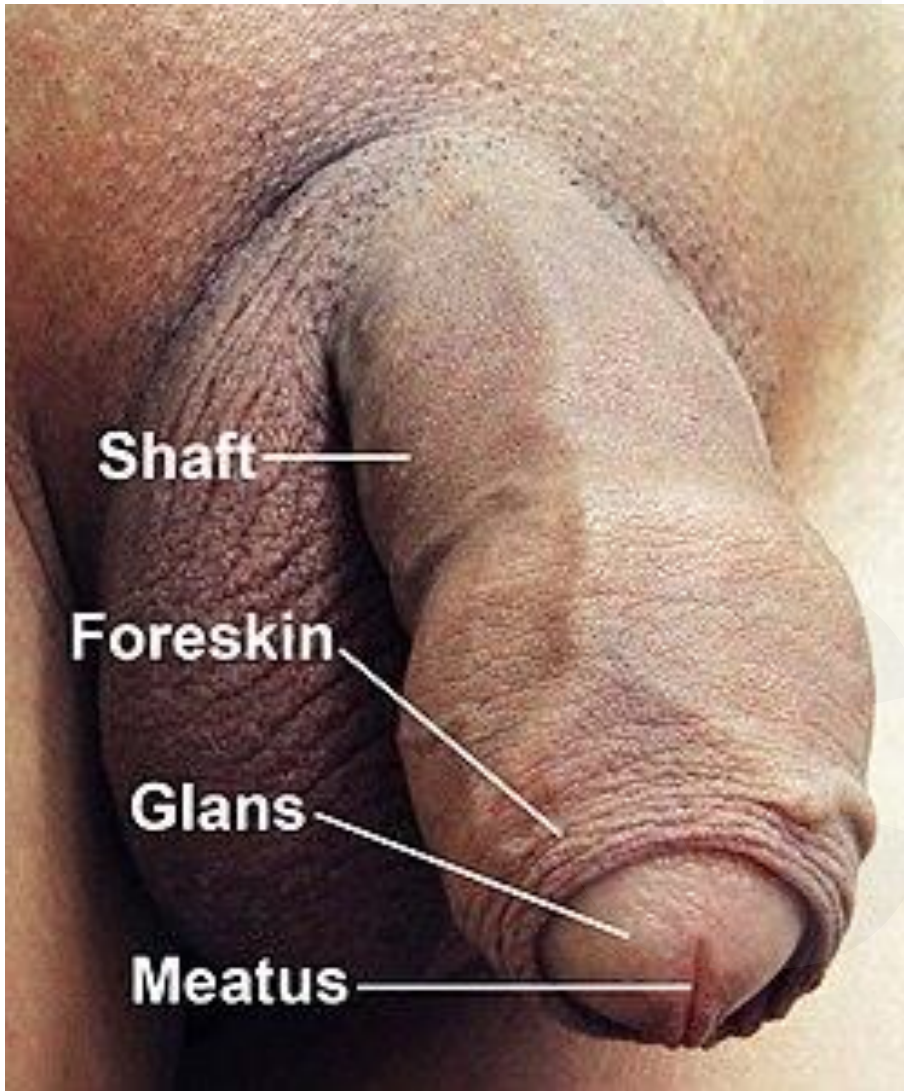


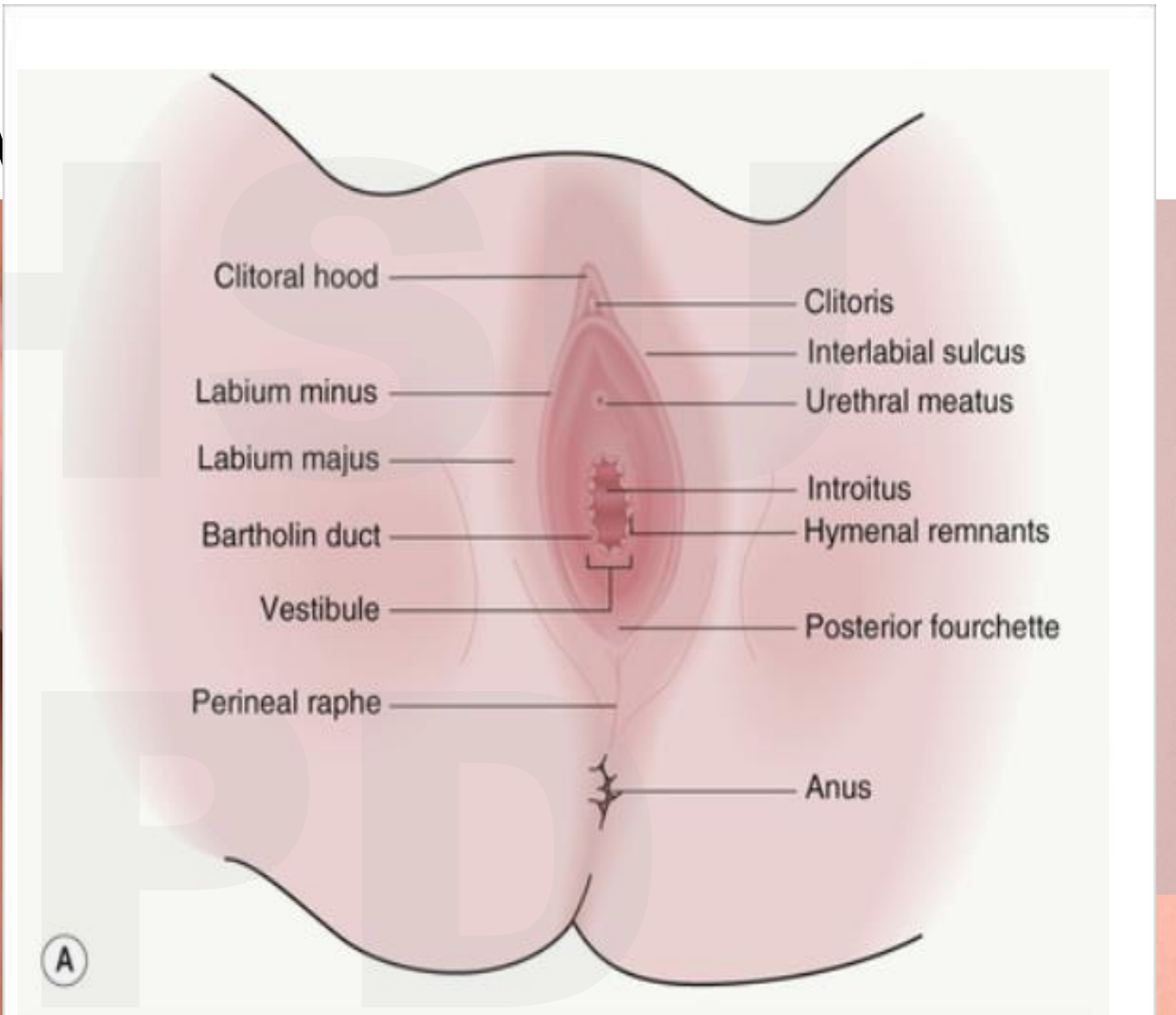
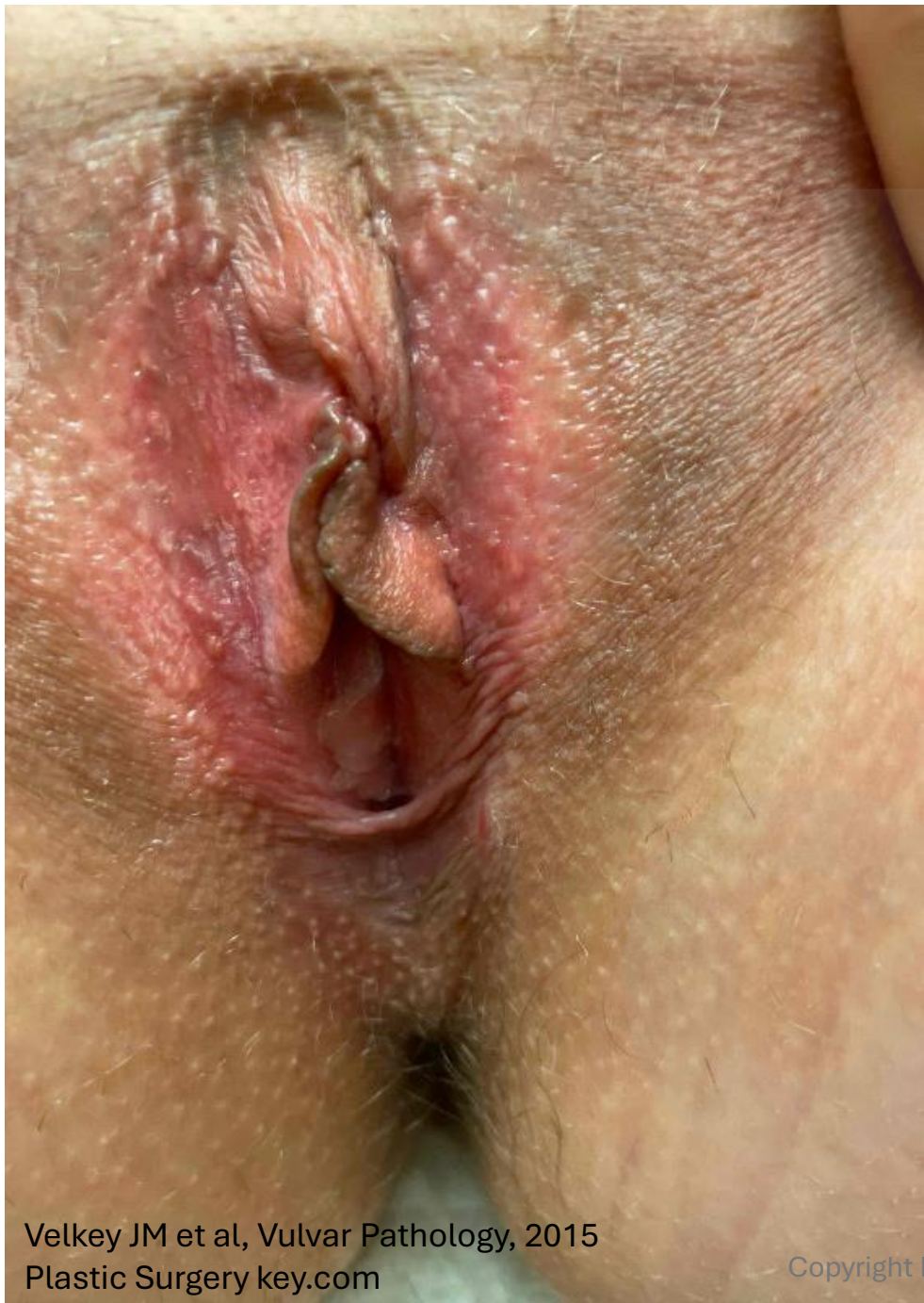Upper I
Gu
Hard pala
Soft pala
Buccal mucos
(inner chee
linin
Inferior lab
frenulu
Lower I

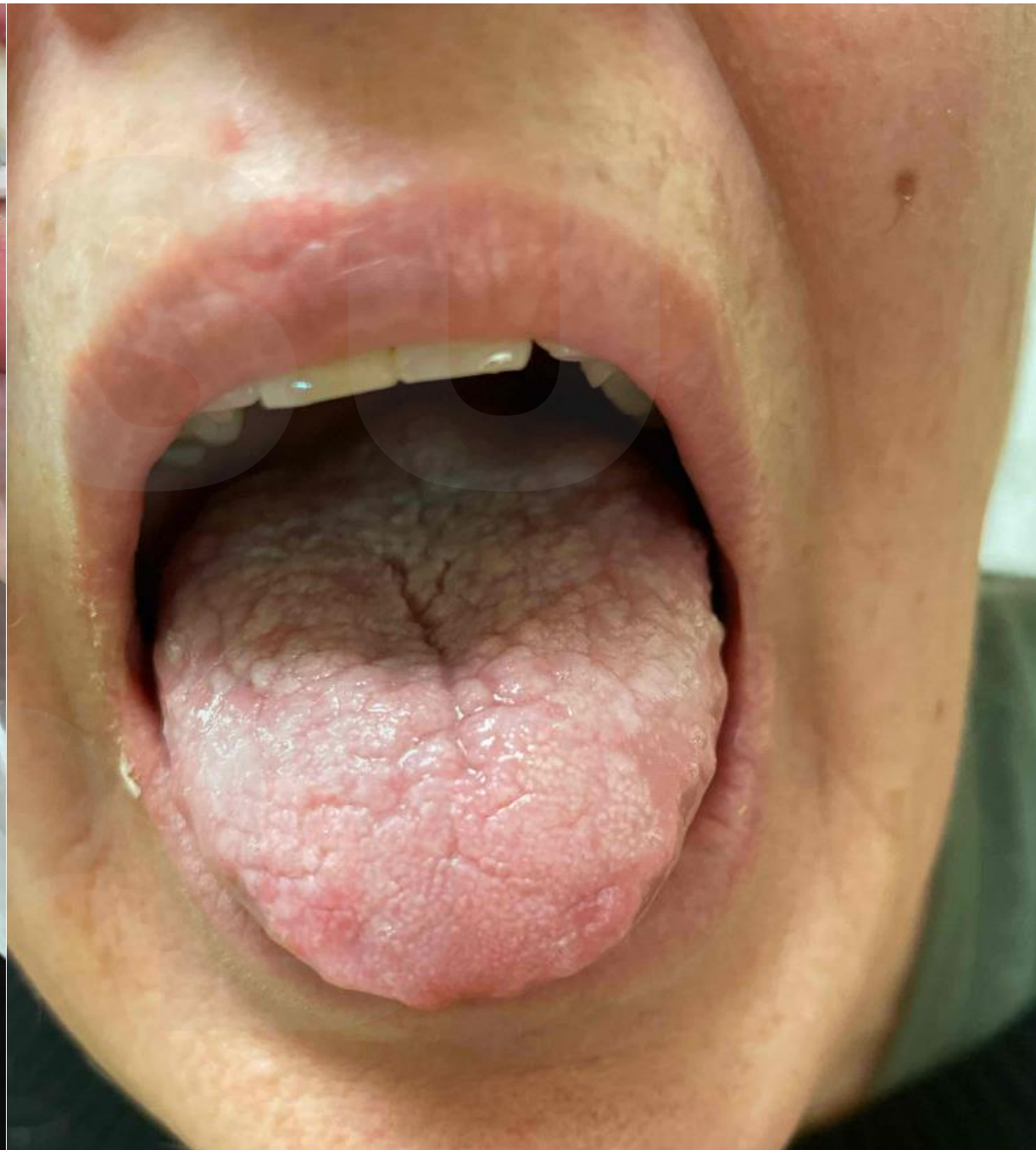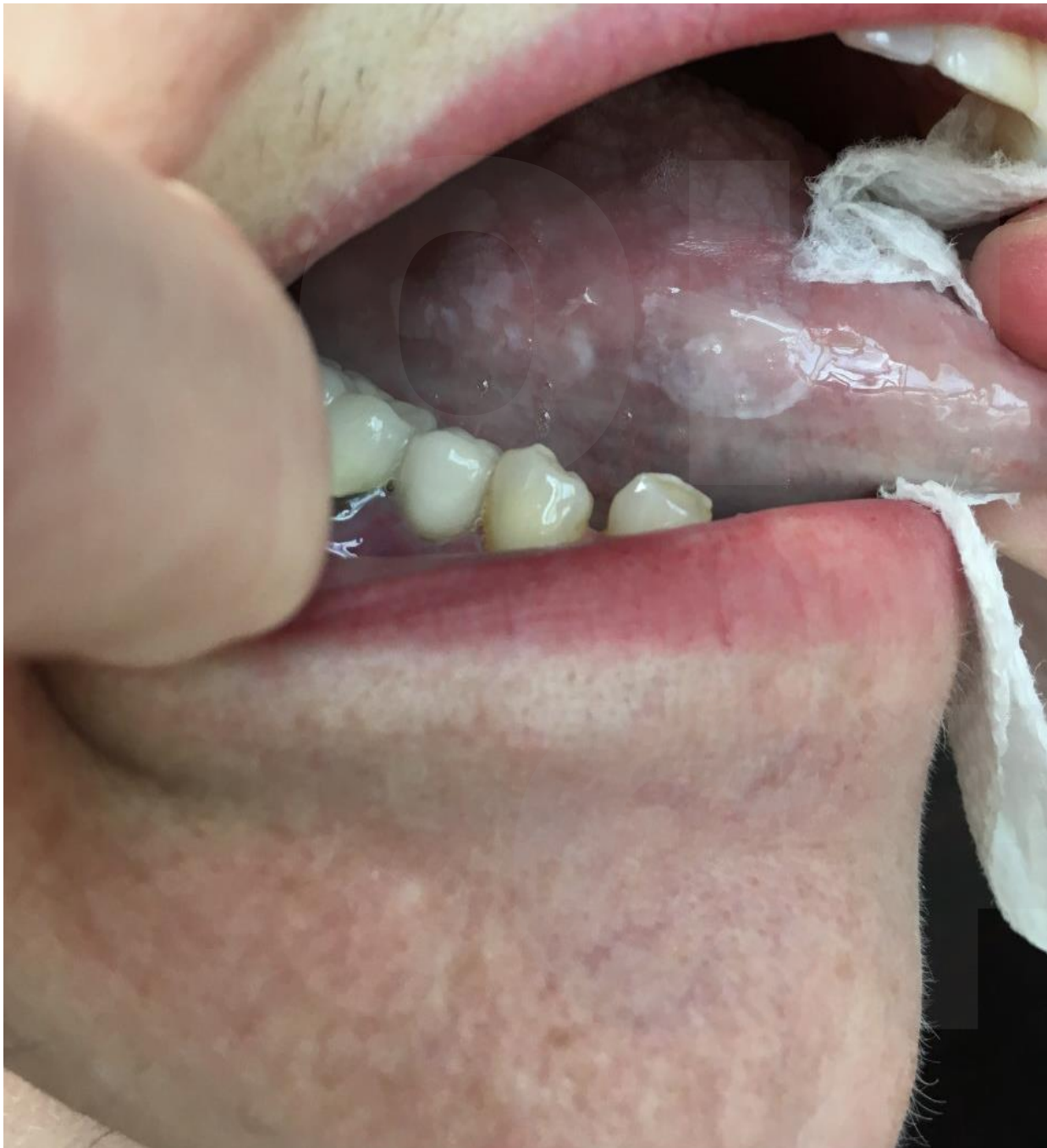Attached gingiva Alveolar mucosa Interdental papilla Free gingiva

Mucogingival junction
Labial frenum

Penile External Anatomy







Summary: Mucosal Ulcers

For genital ulcers:

- Use the Interactive ISSVD Ulcer Algorithm at www.issvd.org

For all mucosal ulcers:

- Use **TOPICAL LIDOCAINE 5% OINTMENT**
- Can use Peri bottles for pain with urination
- Swab for HSV, VZV, CMV but also give pain relief
- Biopsies are usually not helpful



Ulcer Algorithm

English

Ulcer Algorithm



ULCER_ALGORITHMv2_JAN2024.pdf (1,165.39 KB)

[Interactive Algorithm](#)

Click on any underlined word in the document to download a wealth of information on that topic.

Additional resource (also linked on the above Algorithm)

[Power Point Presentation on Ulcers](#)

Case 3: When is cheilitis not cheilitis?

OHSU

CPD