

Physical Diagnosis Potpourri



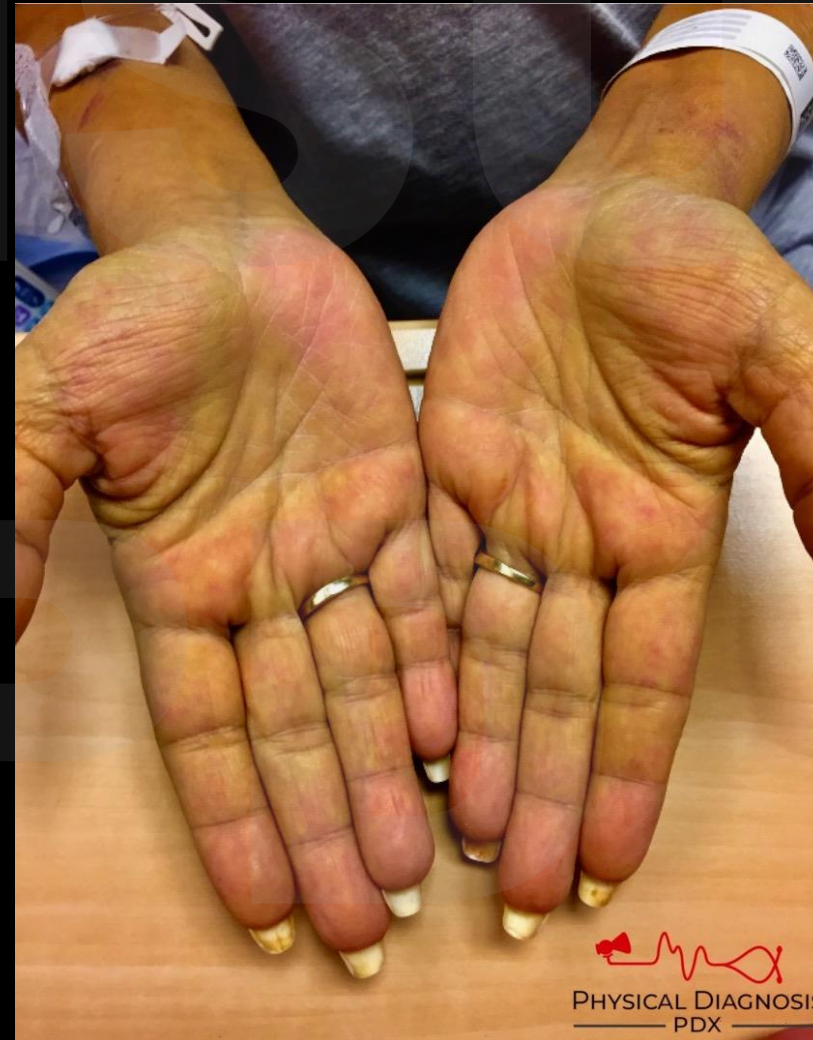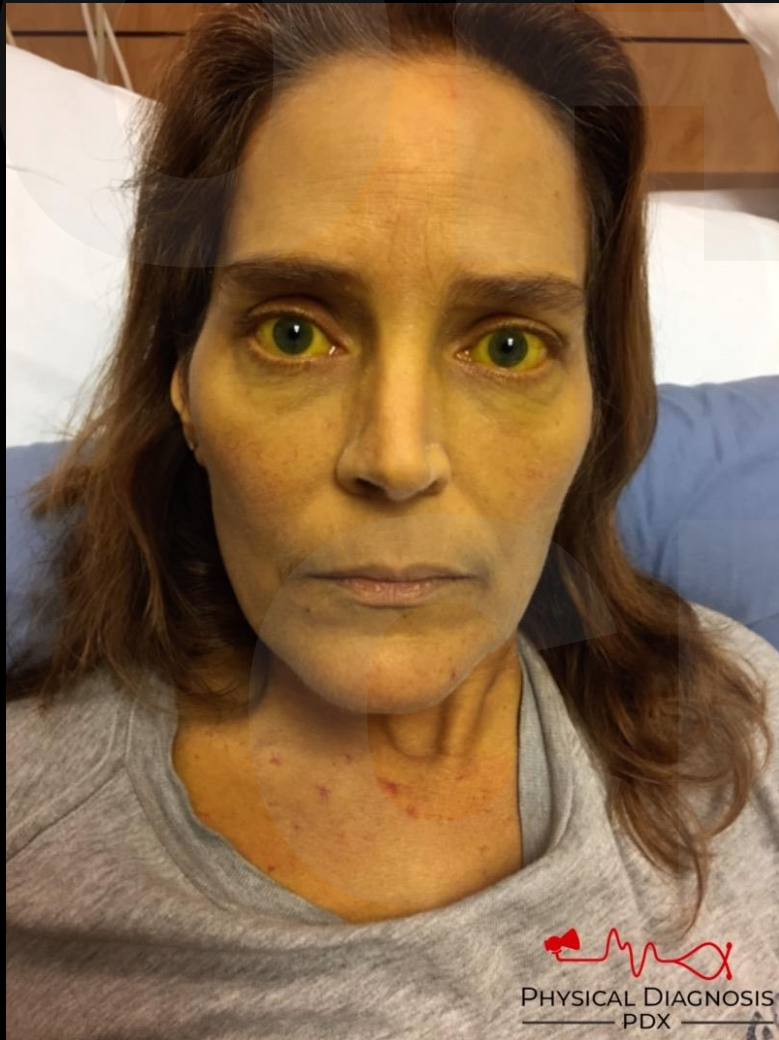André M. Mansoor

No conflicts of interest to disclose

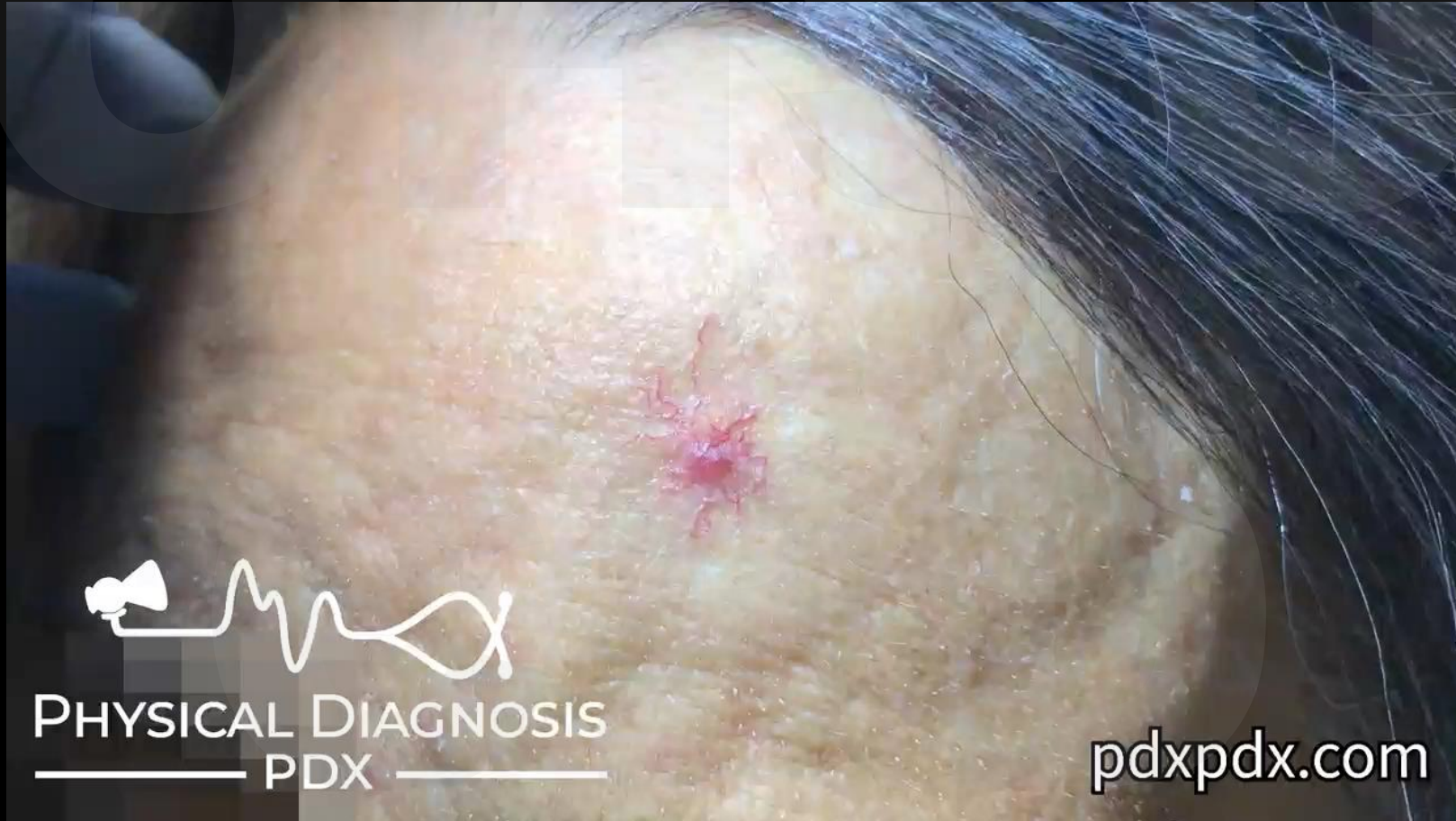Patient Consent

- All patients consented to having images taken and shared for educational purposes

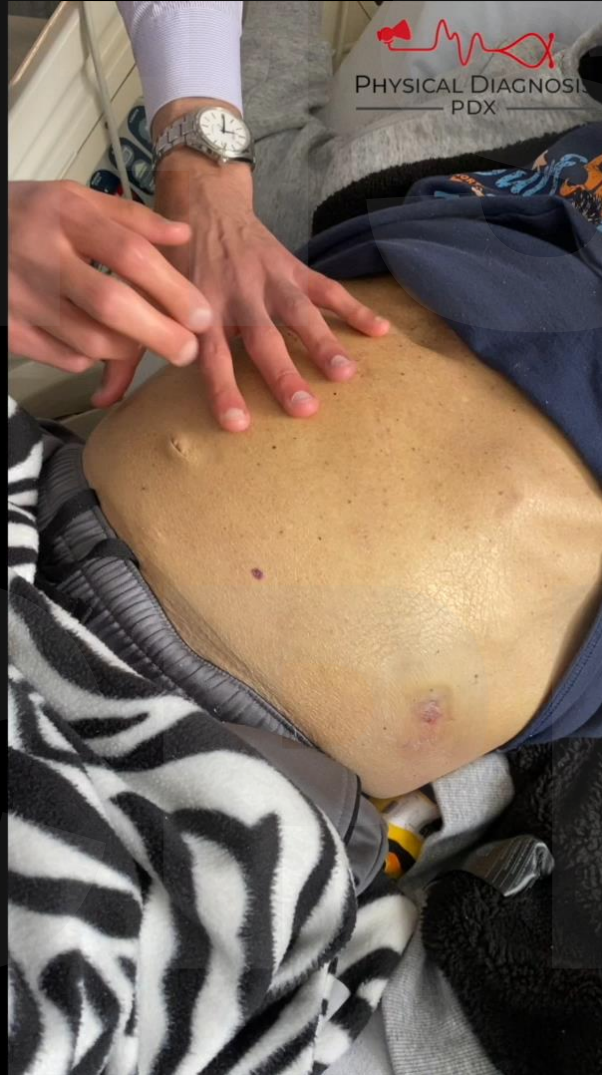Case #1: 46 y/o woman with fatigue



Case #1: 46 y/o woman with fatigue



Case #1: 46 y/o woman with fatigue



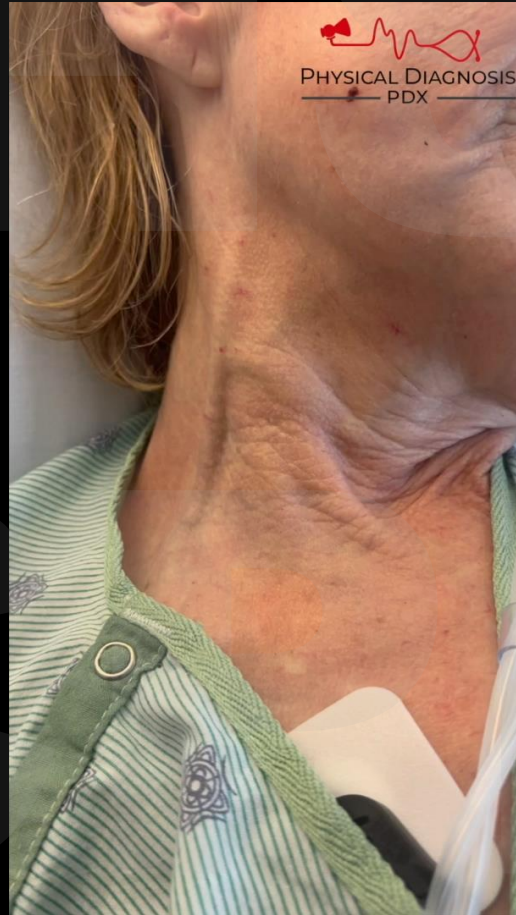Case #1: 46 y/o woman with fatigue

- Clinical findings:
 - Jaundice
 - Spider angiomas
 - Palmar erythema
 - Ascites
- Underlying diagnosis: ?

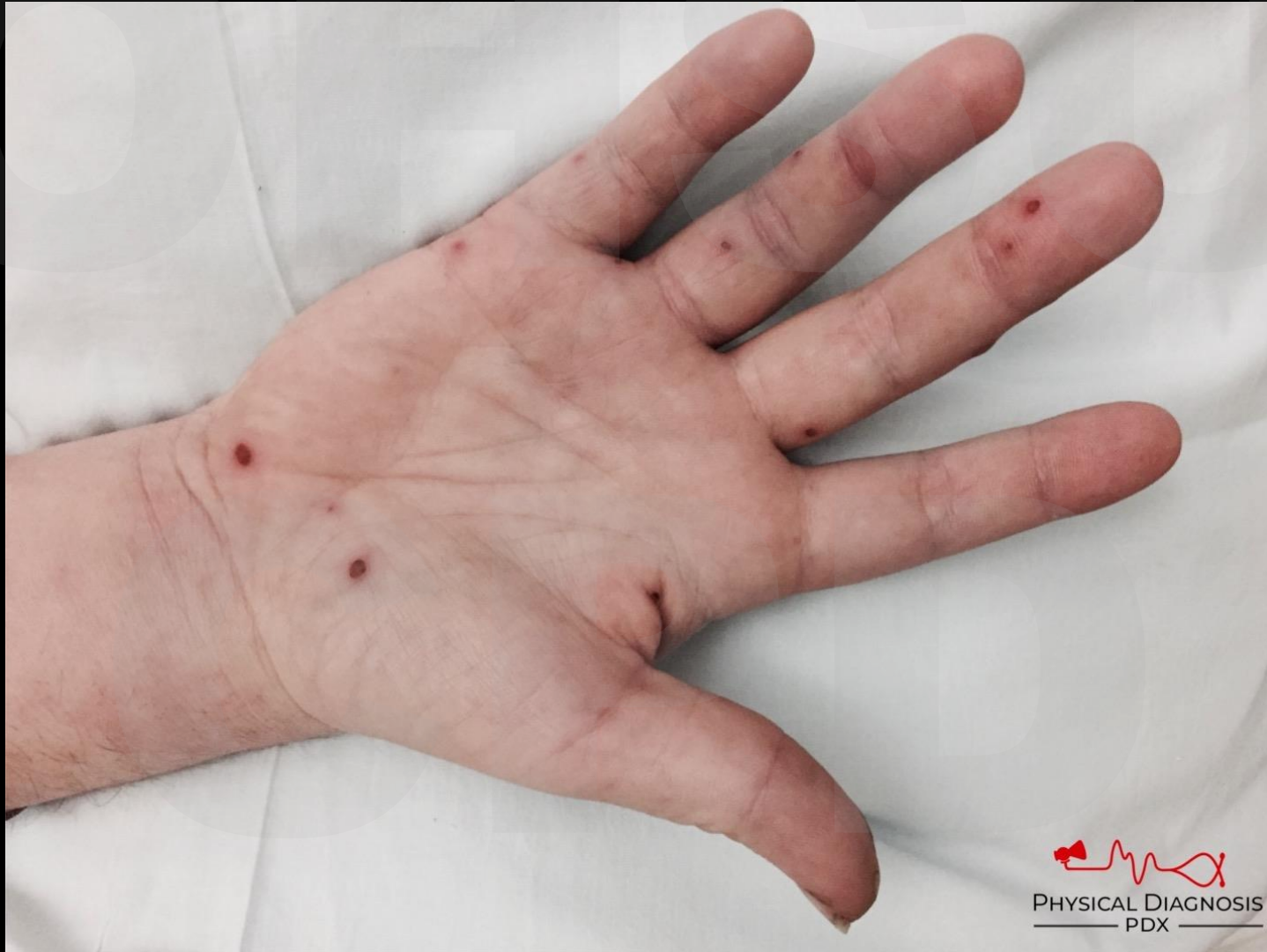Case #1: 46 y/o woman with fatigue

- Clinical findings:
 - Jaundice
 - Spider angiomas
 - Palmar erythema
 - Ascites
- Underlying diagnosis: **Cirrhosis**

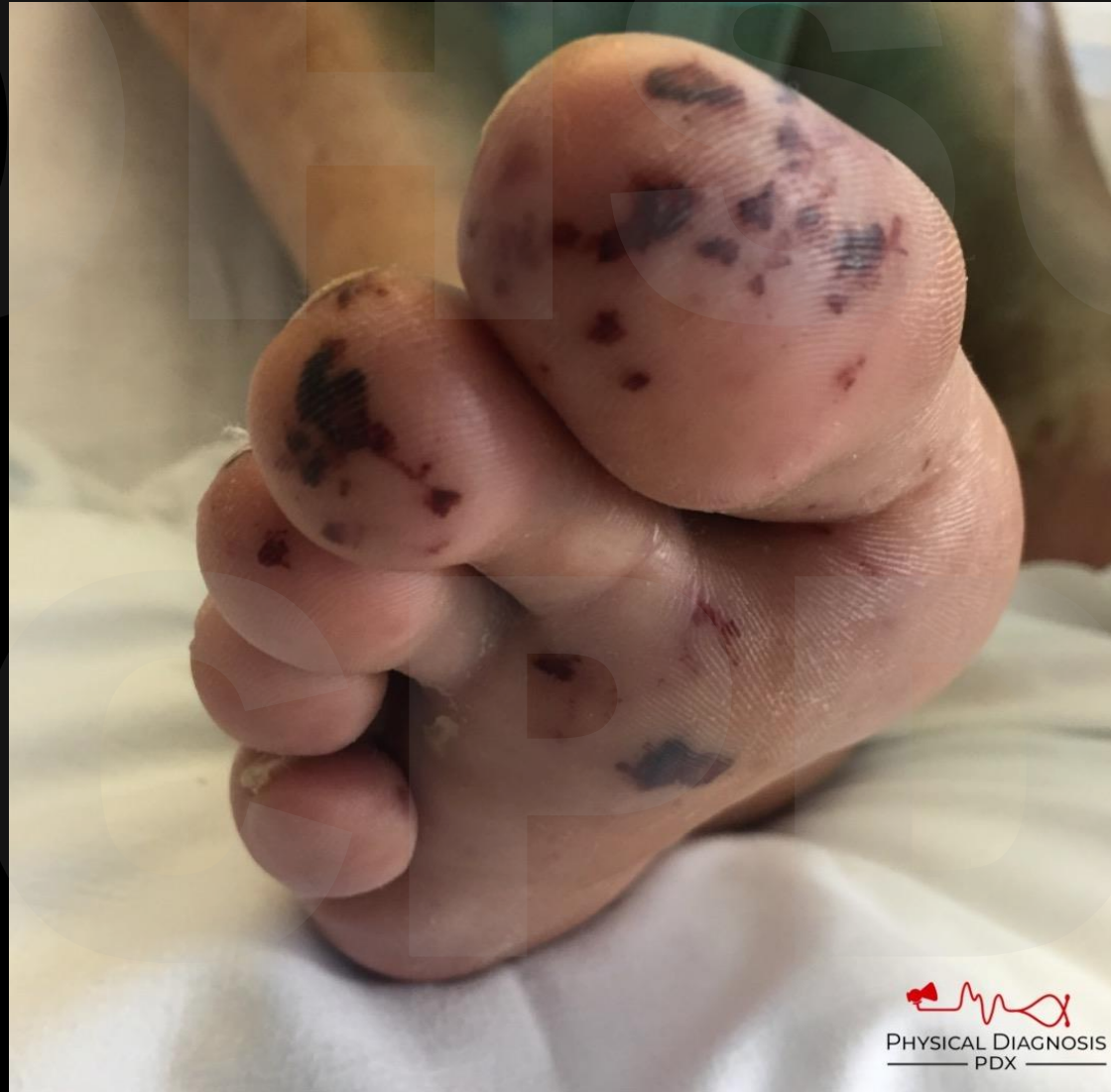Augenblick



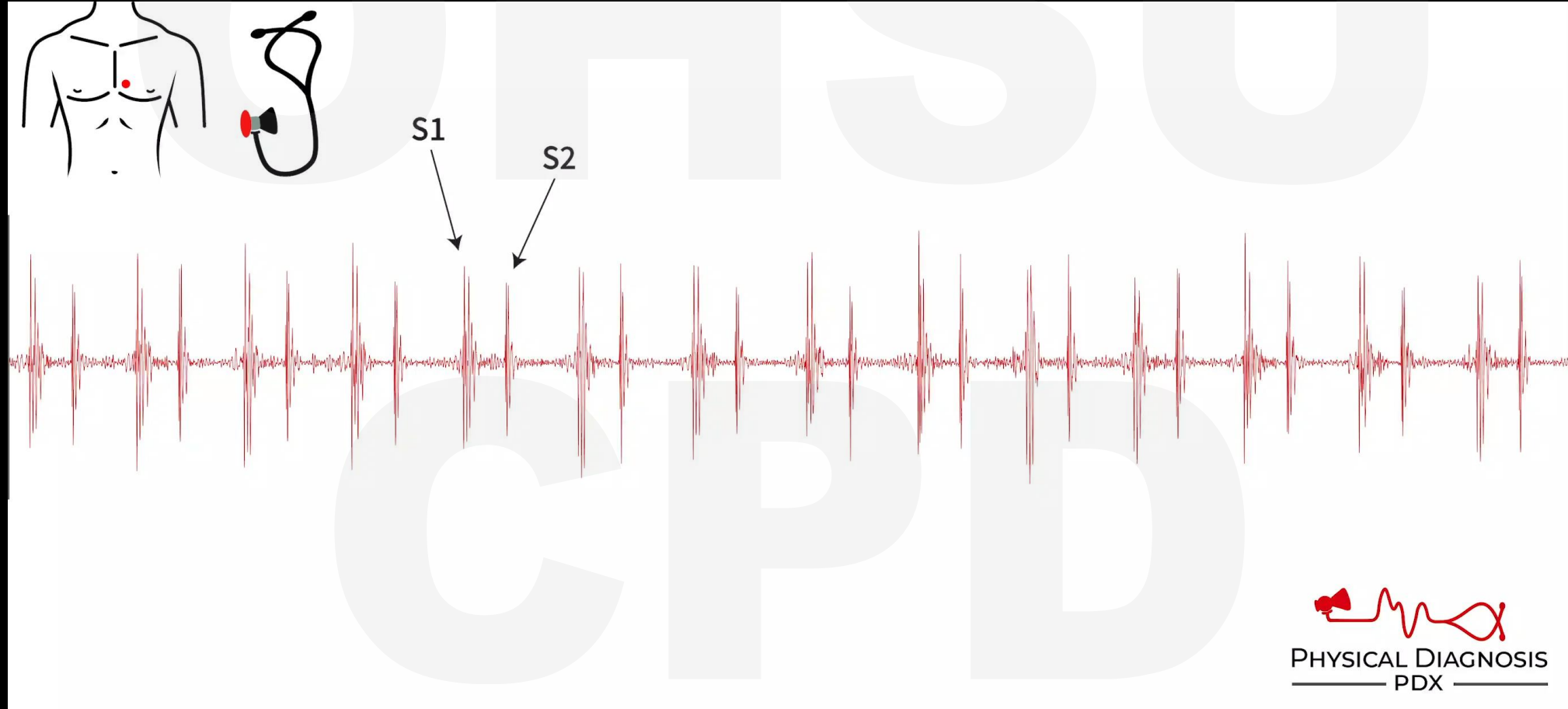
Case #2: 28 y/o man with fever and chills



Case #2: 28 y/o man with fever and chills



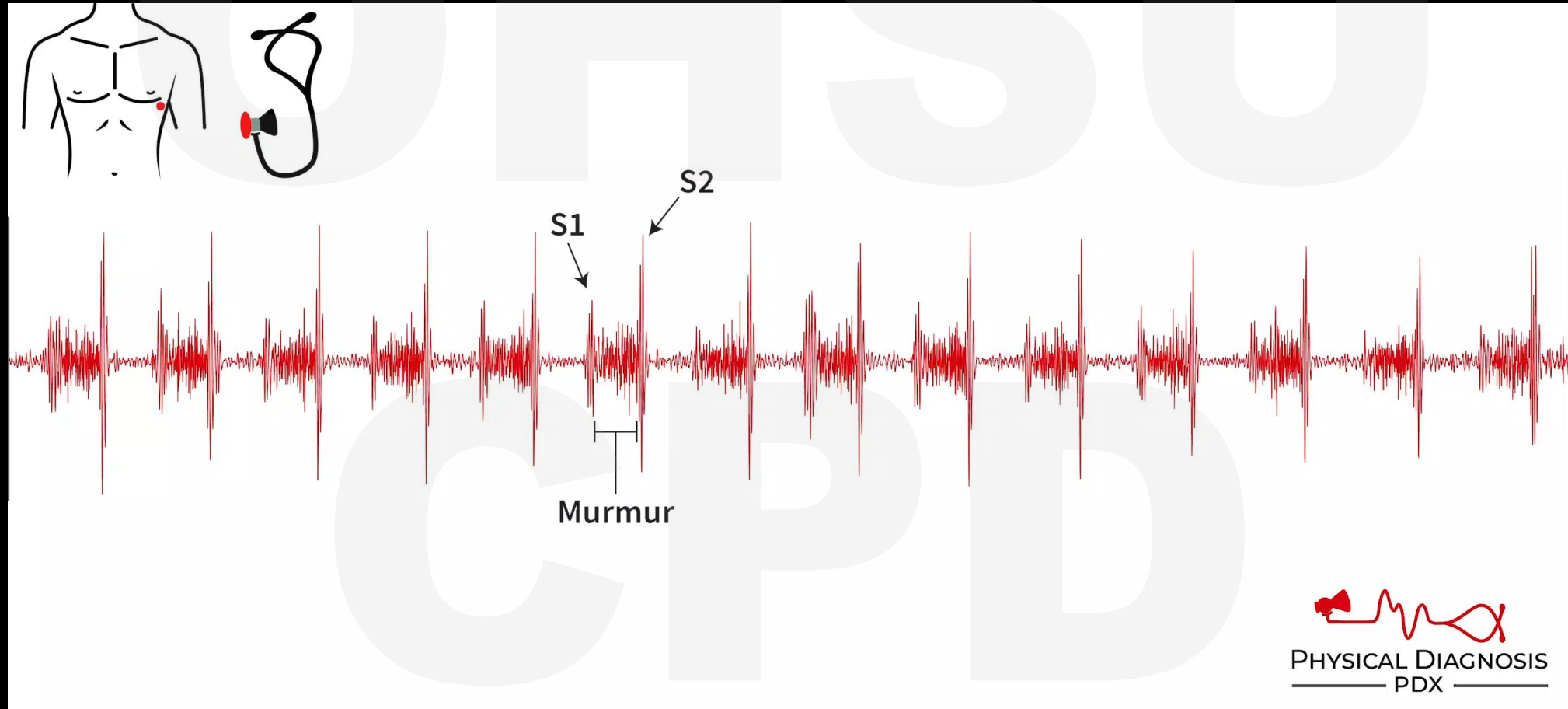
Case #2: 28 y/o man with fever and chills



Case #2: 28 y/o man with fever and chills



Case #2: 28 y/o man with fever and chills



Case #2: 28 y/o man with fever and chills

- Clinical findings:
 - Osler's nodes
 - Janeway lesions
 - Heart murmur
- **Underlying diagnosis: ?**

Case #2: 28 y/o man with fever and chills

- Clinical findings:
 - Osler's nodes
 - Janeway lesions
 - Heart murmur
- Underlying diagnosis: **Endocarditis**

Case #2: 28 y/o man with fever and chills



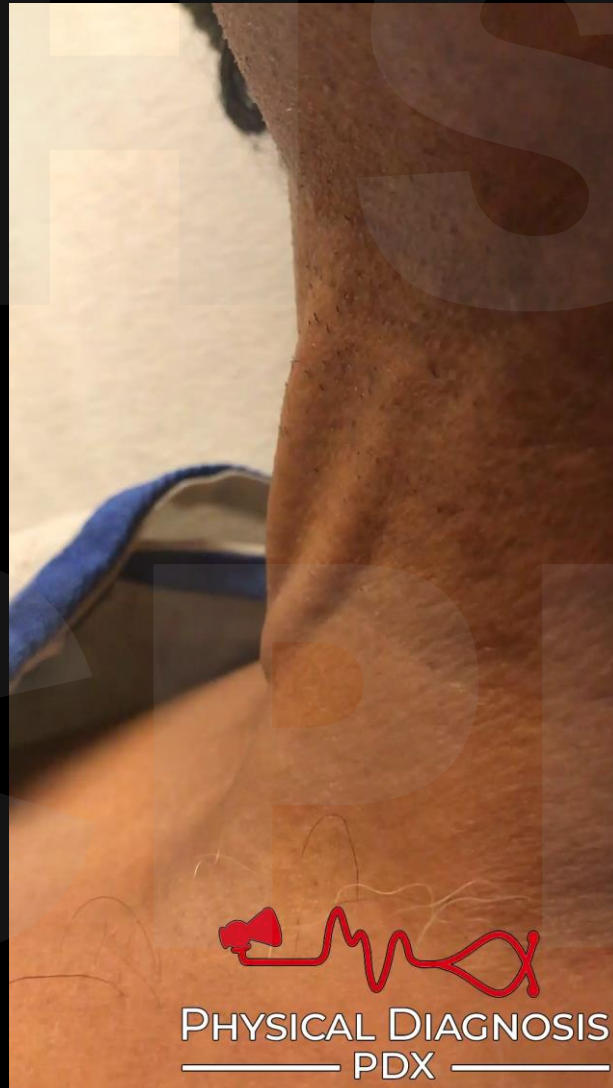Case #2: 28 y/o man with fever and chills

- 3-component pericardial friction rub

Case #2: 28 y/o man with fever and chills

- Patient becomes hypotensive and presyncopal
- Rub has gone away
- Heart sounds more distant
- And his neck looked like this. . .

Case #2: 28 y/o man with fever and chills



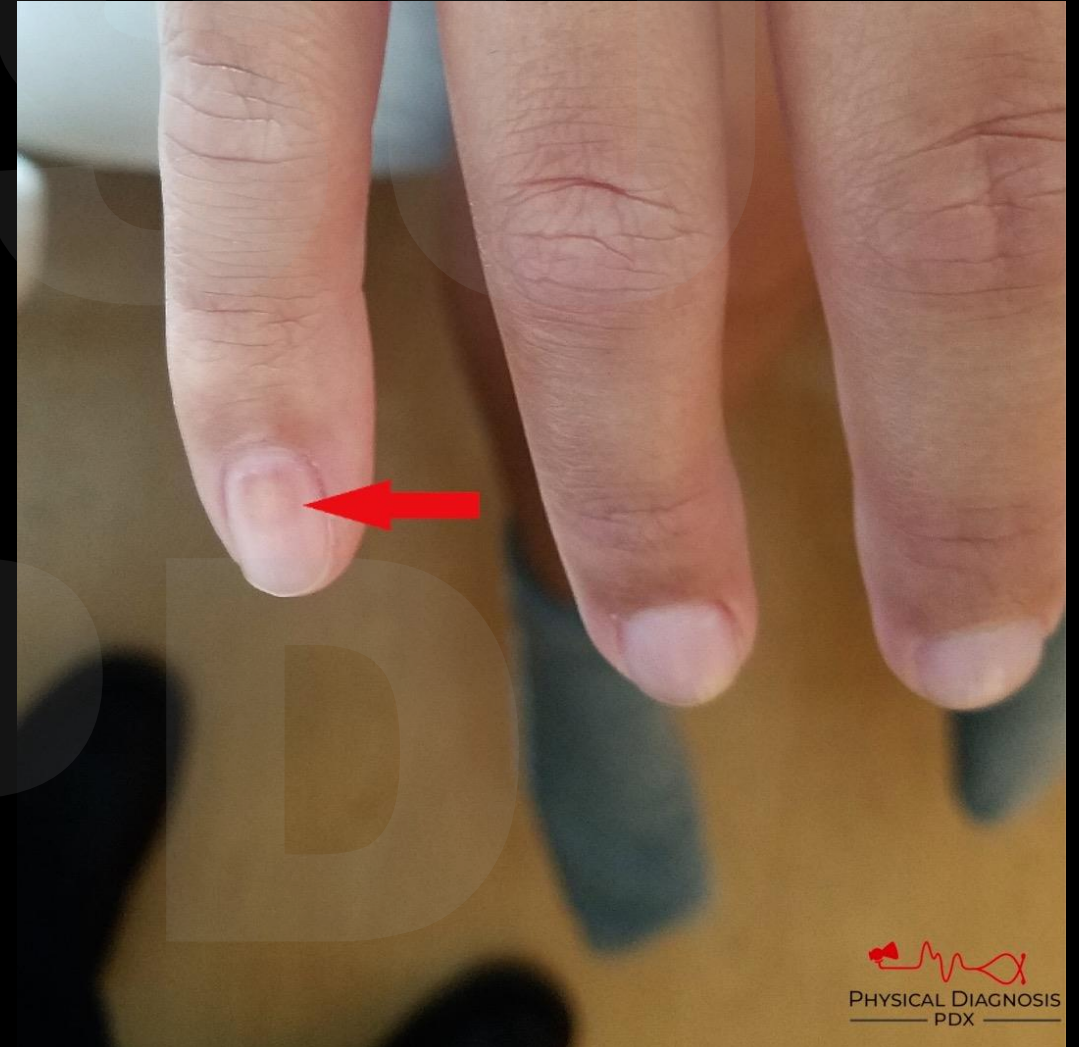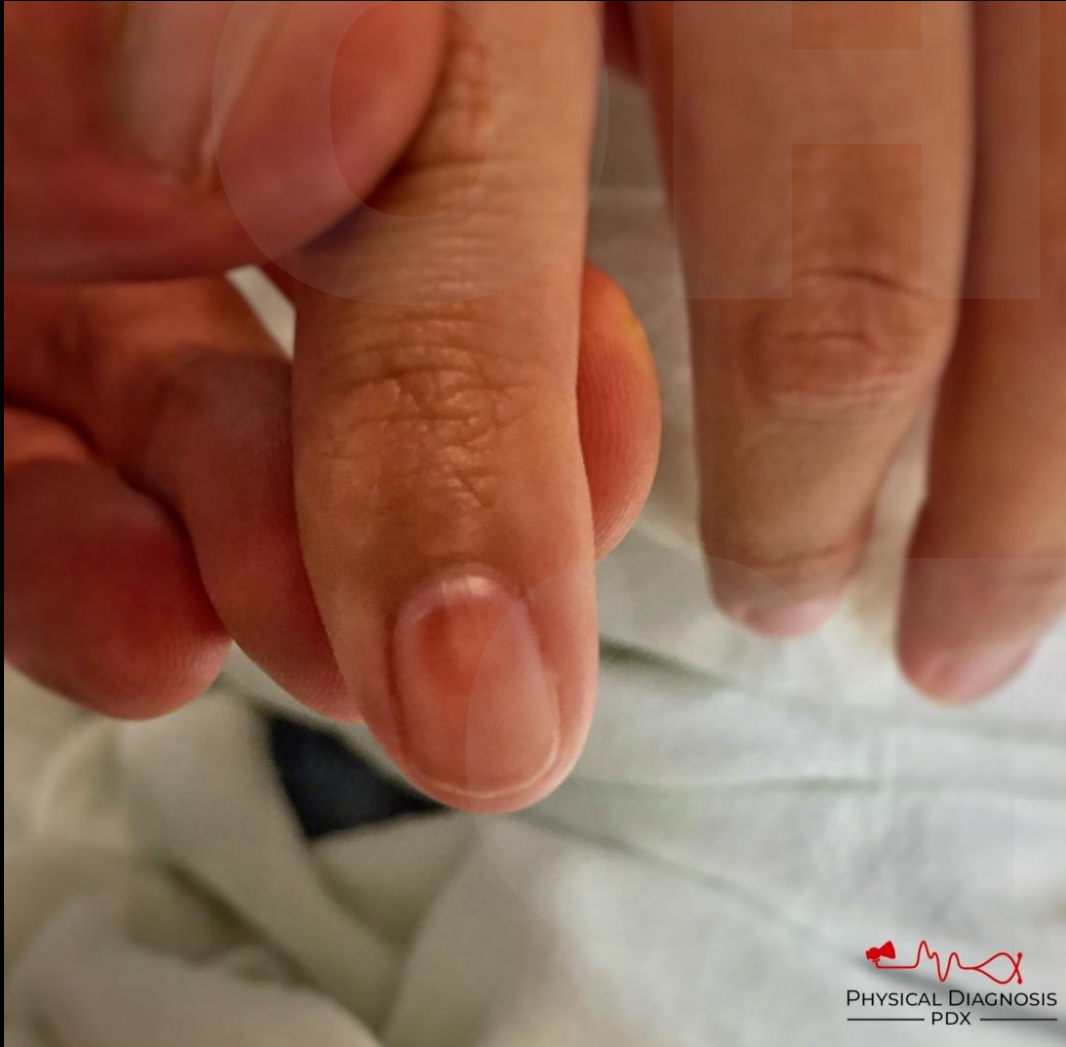Case #2: 28 y/o man with fever and chills

- Clinical findings:
 - Distant heart sounds
 - Hypotension
 - Elevated JVP
- **Underlying diagnosis: ?**

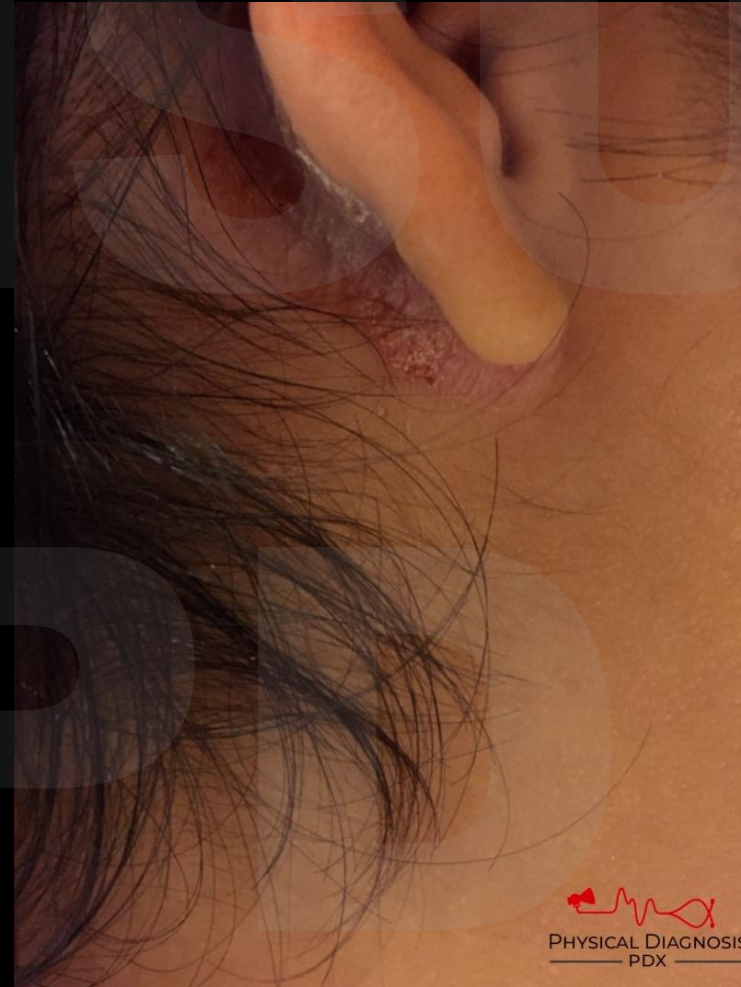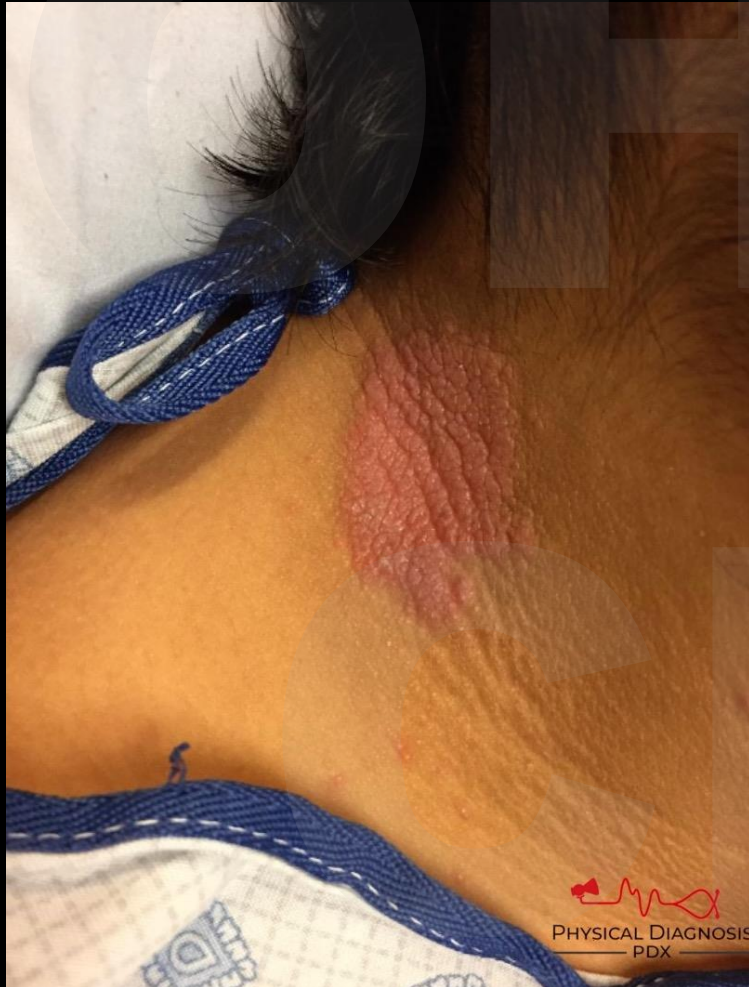Case #2: 28 y/o man with fever and chills

- Clinical findings:
 - Distant heart sounds
 - Hypotension
 - Elevated JVP
- Underlying diagnosis: **Tamponade**

Case #3: 24 y/o woman with joint pain



Case #3: 24 y/o woman with joint pain



Case #3: 24 y/o woman with joint pain

- Clinical findings:
 - Oil drop sign
 - Psoriatic plaques
- **Underlying diagnosis: ?**


Case #3: 24 y/o woman with joint pain

- Clinical findings:
 - Oil drop sign
 - Psoriatic plaques
- **Underlying diagnosis: Psoriatic arthritis**

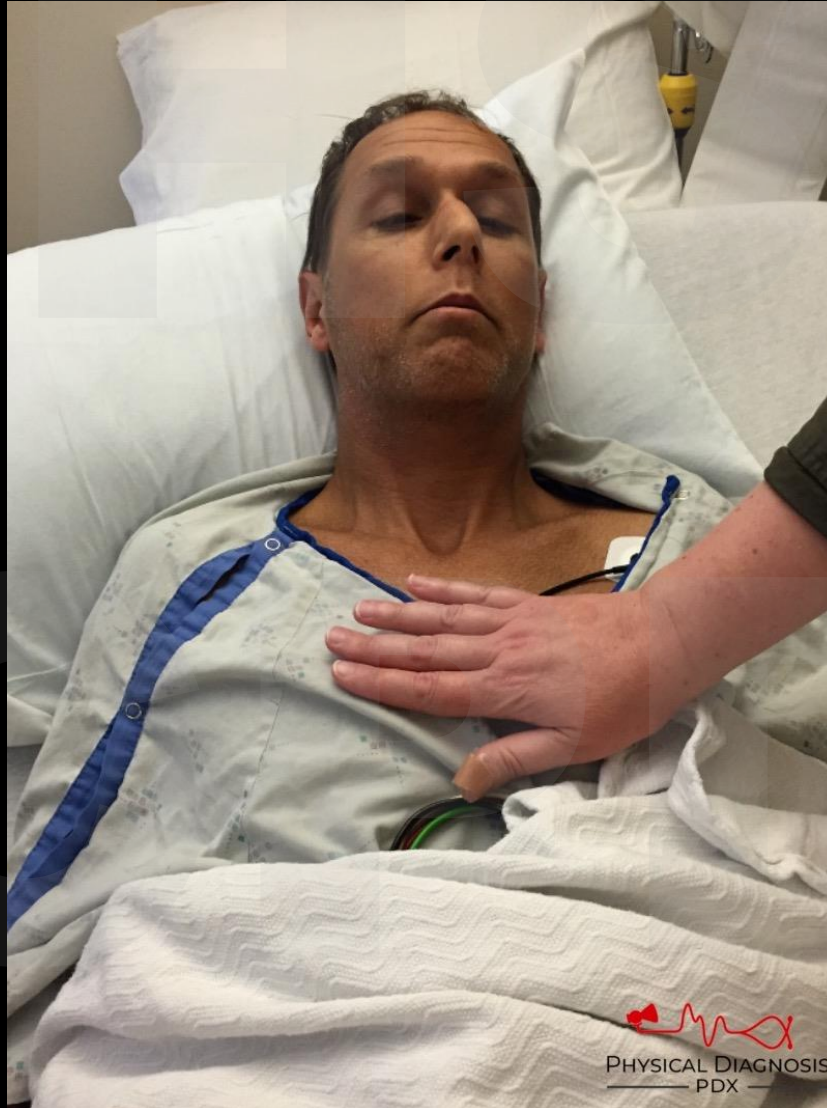Augenblick




Case #4: 34 y/o woman with light-headedness



Case #4: 34 y/o woman with light-headedness



Case #4: 34 y/o woman with light-headedness



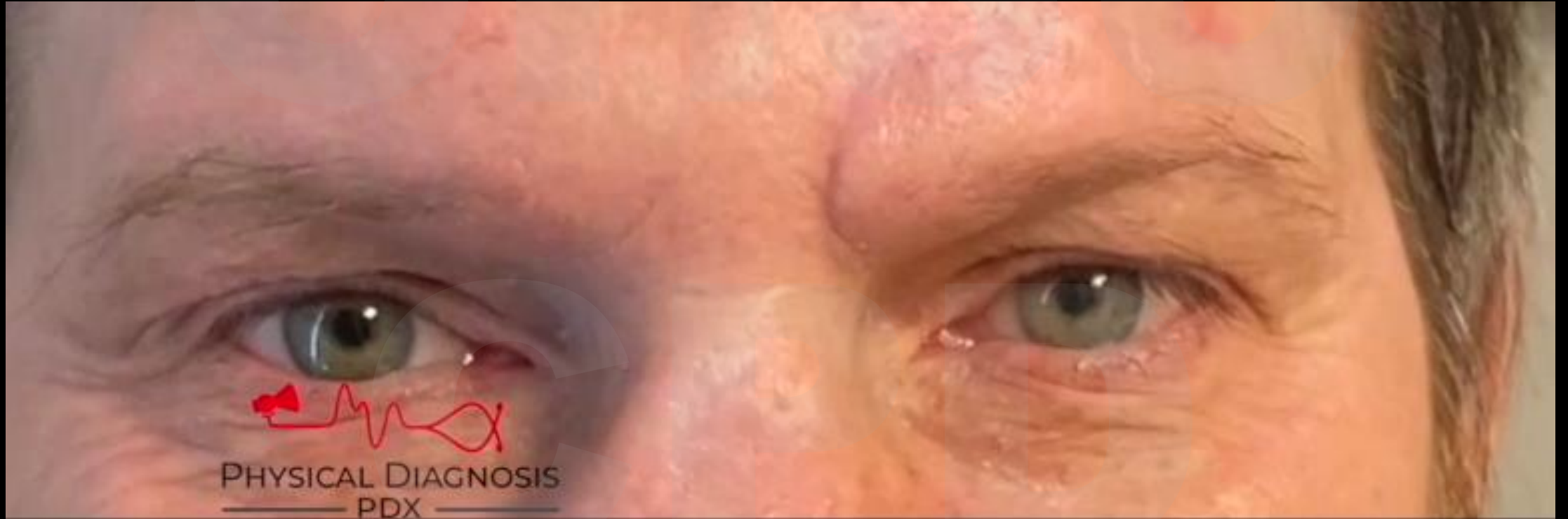Case #4: 34 y/o woman with light-headedness

- Clinical findings:
 - Hyperpigmentation
- **Underlying diagnosis: ?**

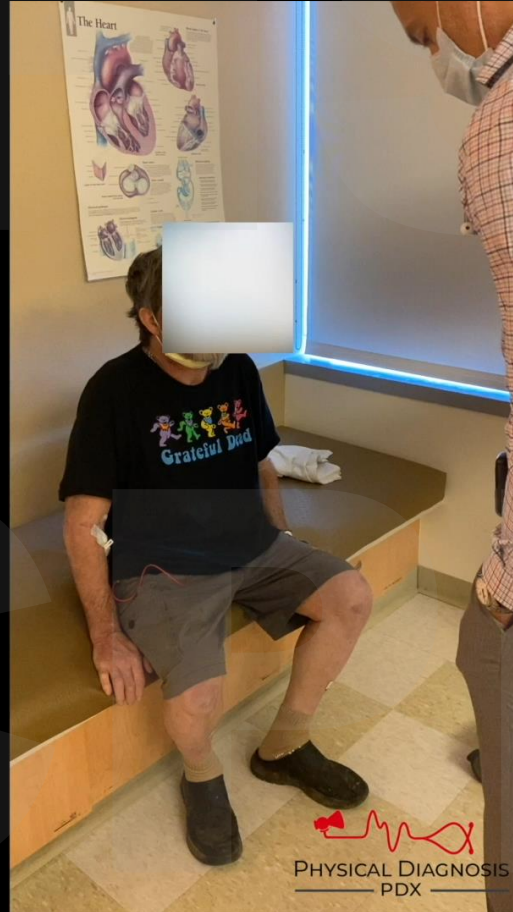Case #4: 34 y/o woman with light-headedness

- Clinical findings:
 - Hyperpigmentation
- **Underlying diagnosis: Adrenal insufficiency**

Case #5: 60 y/o man with confusion



Case #5: 60 y/o man with confusion



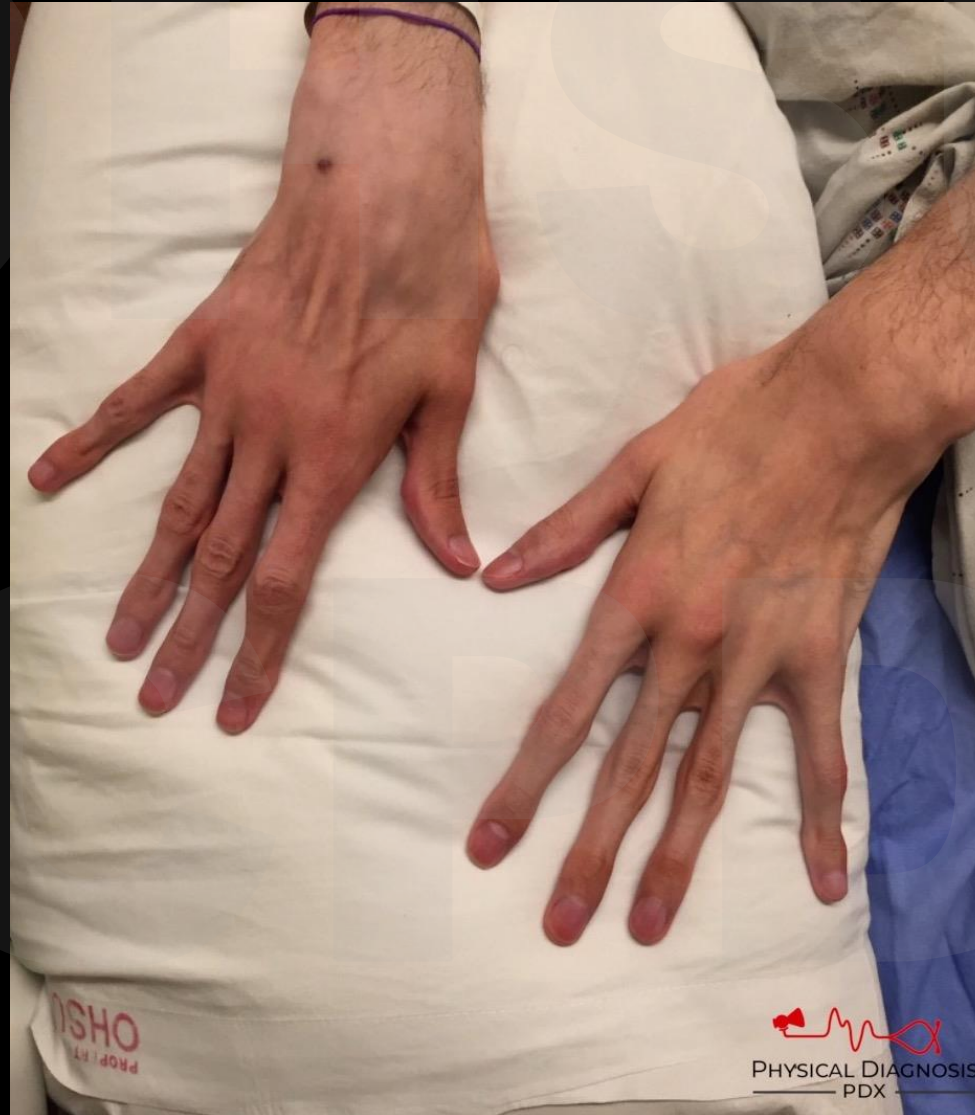Case #5: 60 y/o man with confusion

- Clinical findings:
 - Nystagmus
 - Confabulation
- **Underlying diagnosis: ?**

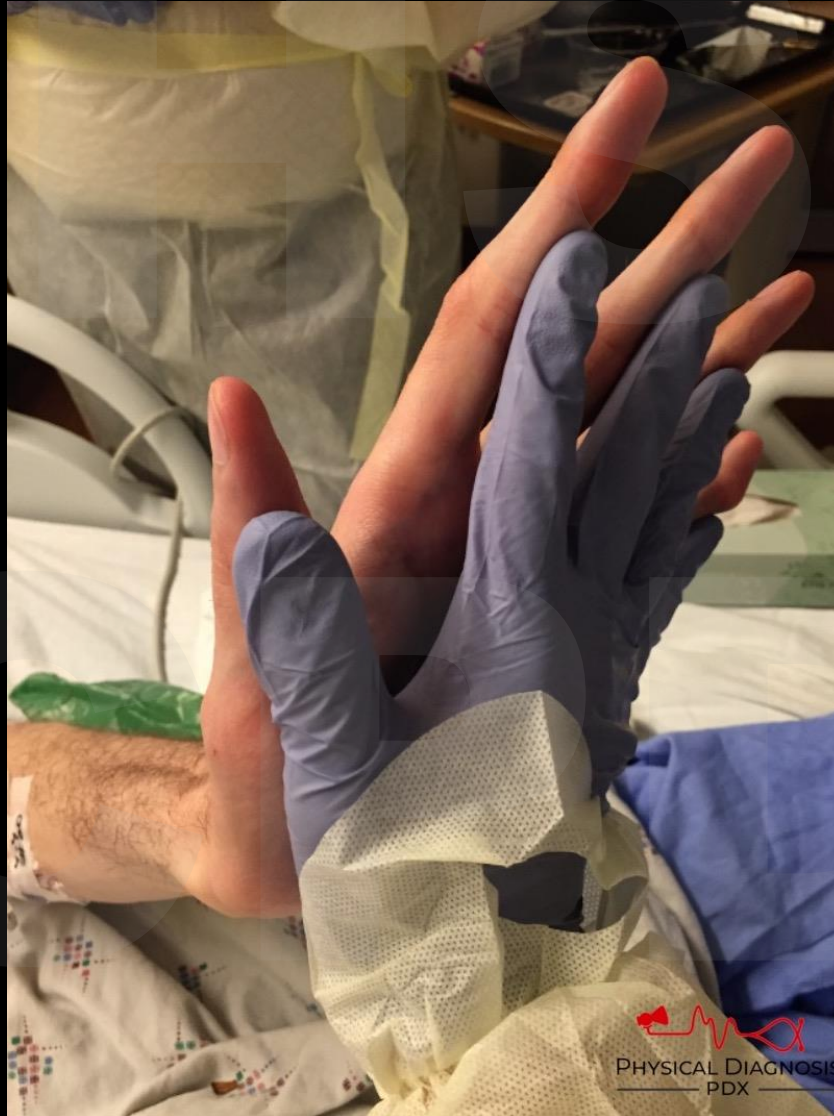Case #5: 60 y/o man with confusion

- Clinical findings:
 - Nystagmus
 - Confabulation
- Underlying diagnosis: **Wernicke-Korsakoff syndrome**

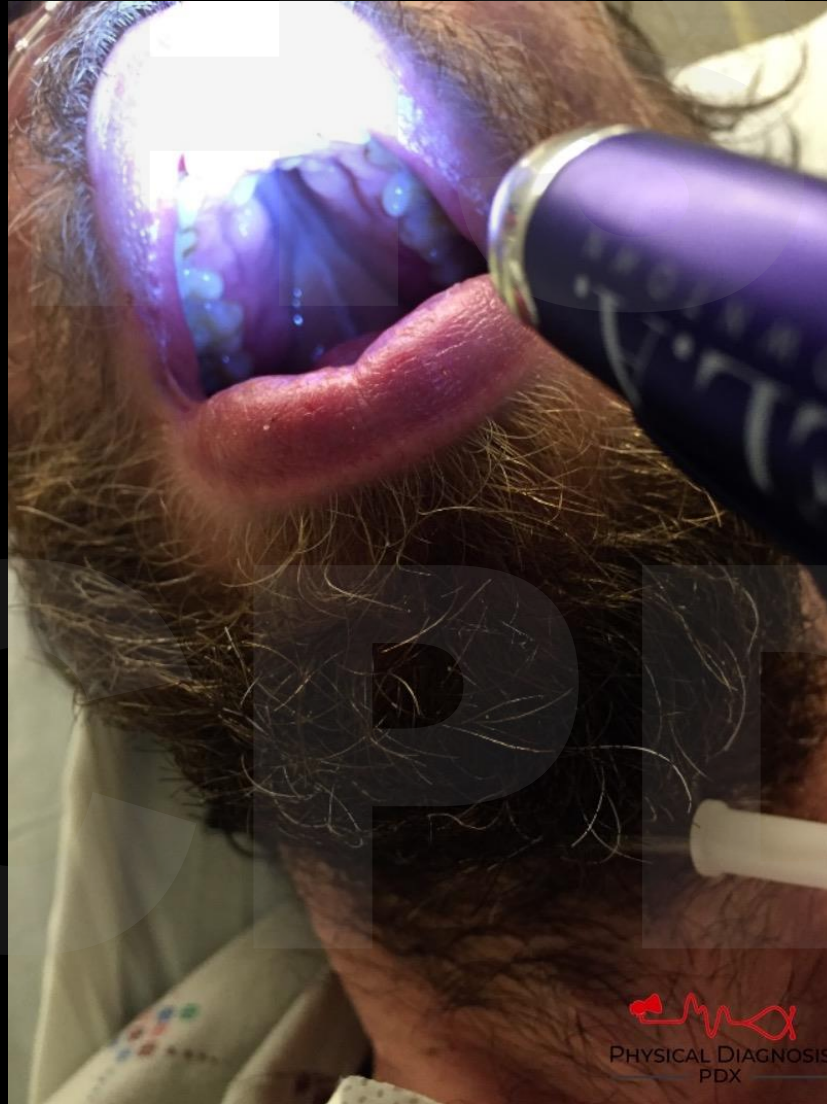Case #6: 25 y/o man with blurry vision



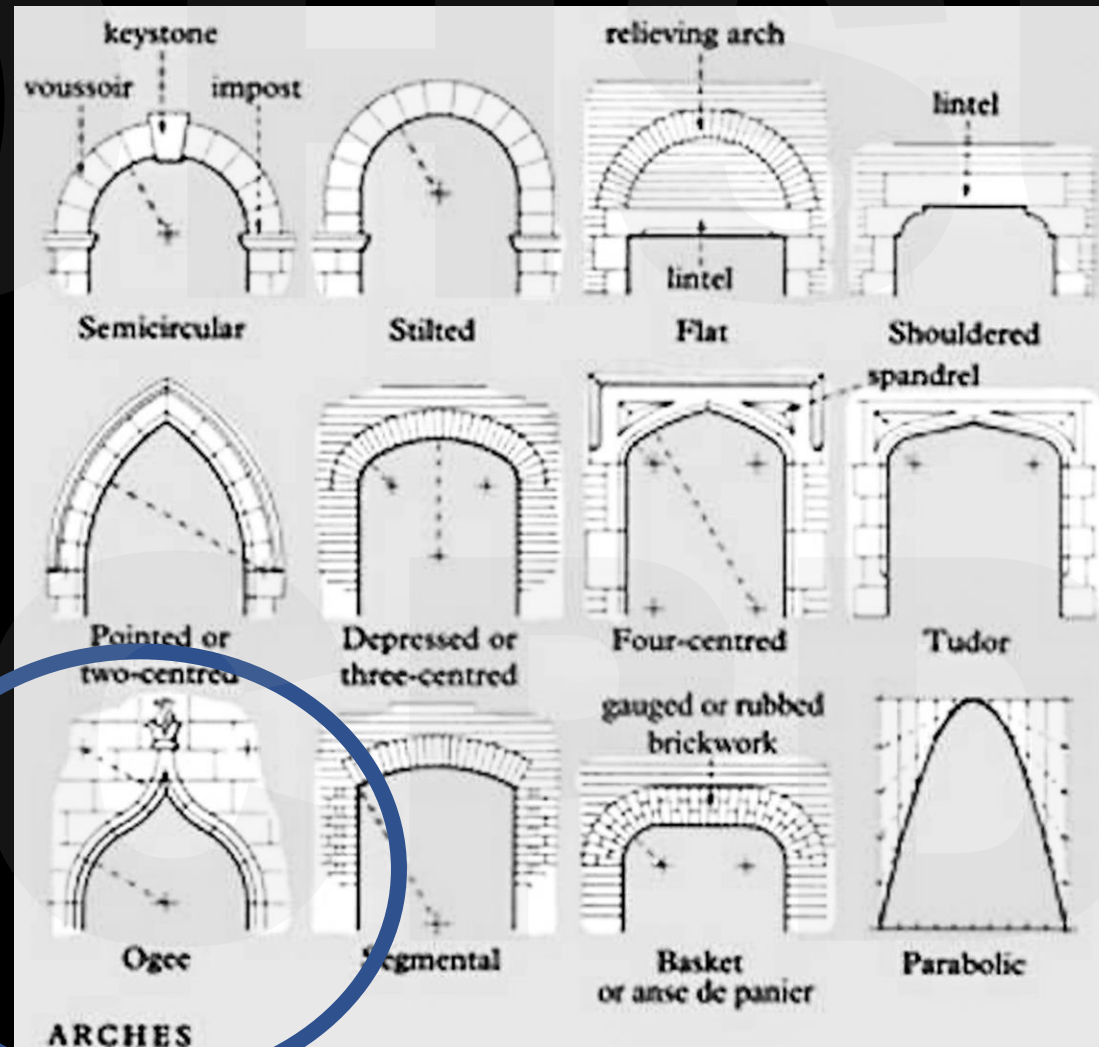
Case #6: 25 y/o man with blurry vision



Case #6: 25 y/o man with blurry vision



Case #6: 25 y/o man with blurry vision




Case #6: 25 y/o man with blurry vision



Case #6: 25 y/o man with blurry vision



Case #6: 25 y/o man with blurry vision



Case #6: 25 y/o man with blurry vision



Case #6: 25 y/o man with blurry vision



Case #6: 25 y/o man with blurry vision




Case #6: 25 y/o man with blurry vision



Case #6: 25 y/o man with blurry vision



Case #6: 25 y/o man with blurry vision



Case #6: 25 y/o man with blurry vision



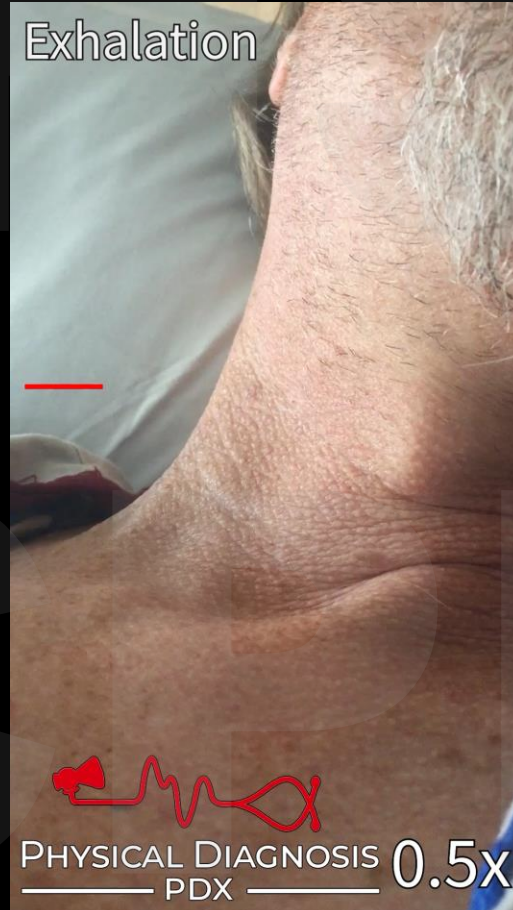Case #6: 25 y/o man with blurry vision

- Clinical findings:
 - Arachnodactyly
 - High-arched palate (ogival palate)
- **Underlying diagnosis: ?**

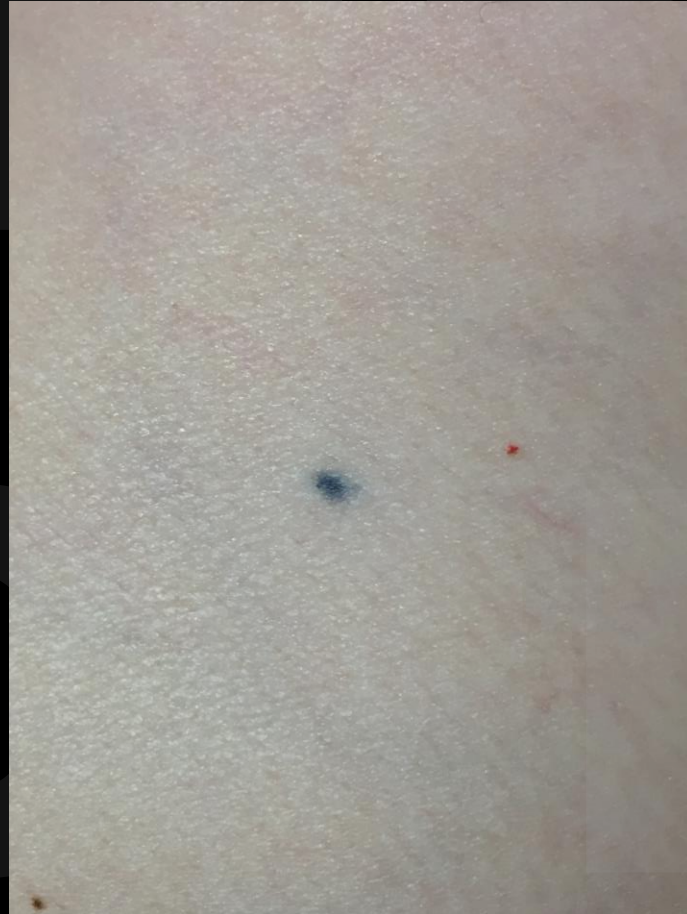Case #6: 25 y/o man with blurry vision

- Clinical findings:
 - Arachnodactyly
 - High-arched palate (ogival palate)
- Underlying diagnosis: **Marfan's syndrome**

Case #7: 65 y/o man with dyspnea



Case #7: 65 y/o man with dyspnea



Case #7: 65 y/o man with dyspnea



Case #7: 65 y/o man with dyspnea



Case #7: 65 y/o man with dyspnea



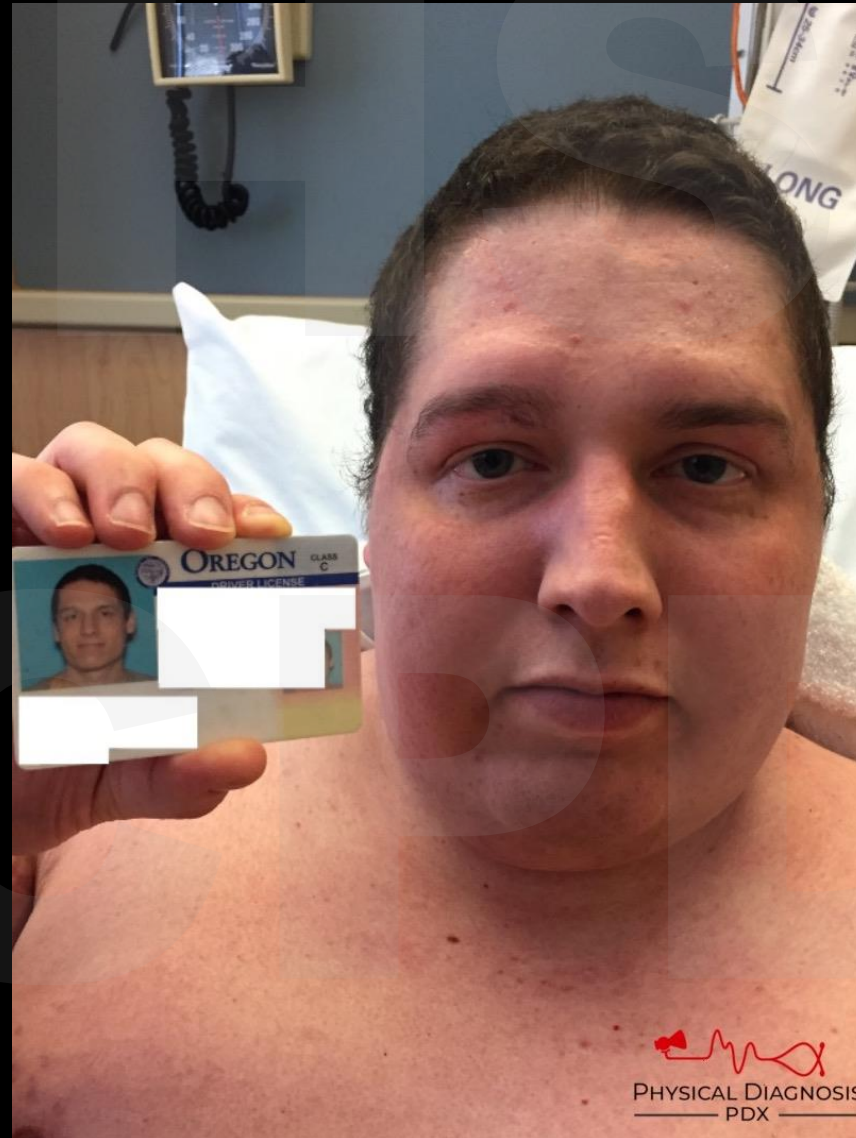
Case #7: 65 y/o man with dyspnea

- Clinical findings:
 - Kussmaul's sign
 - Radiation tattoo marker
 - Pericardial knock
- **Underlying diagnosis: ?**

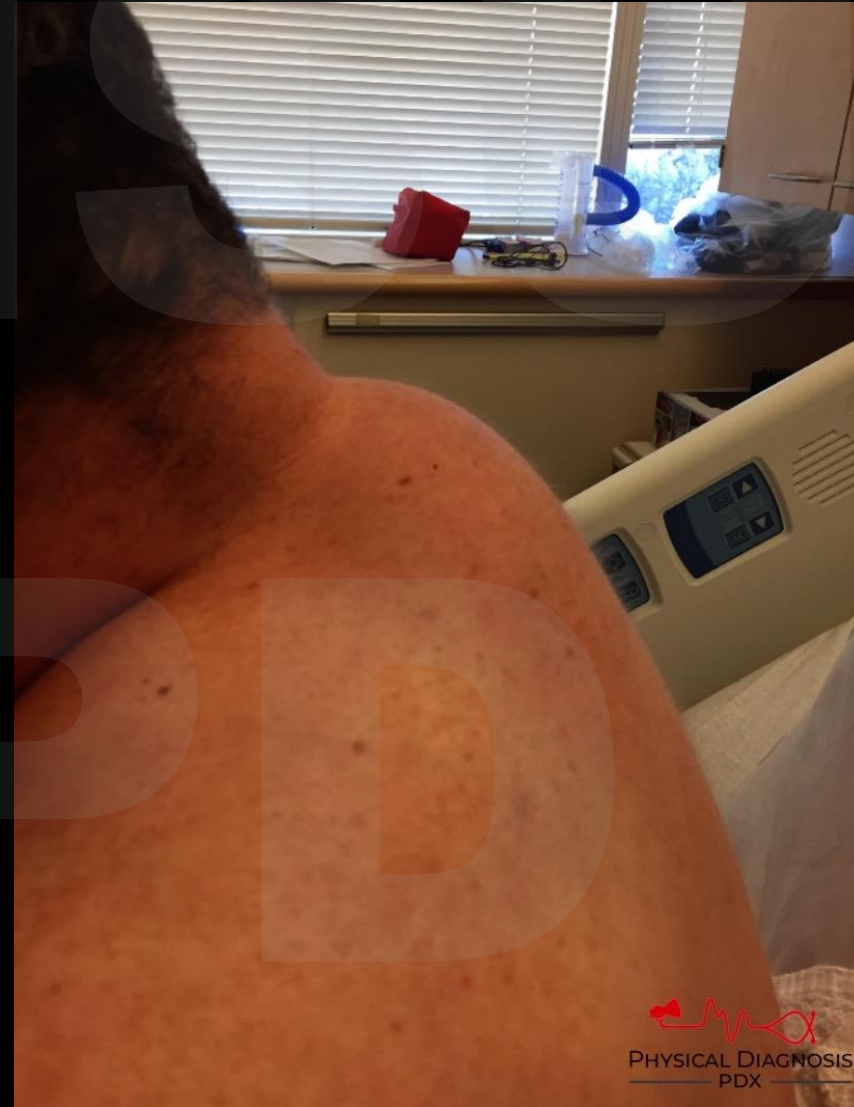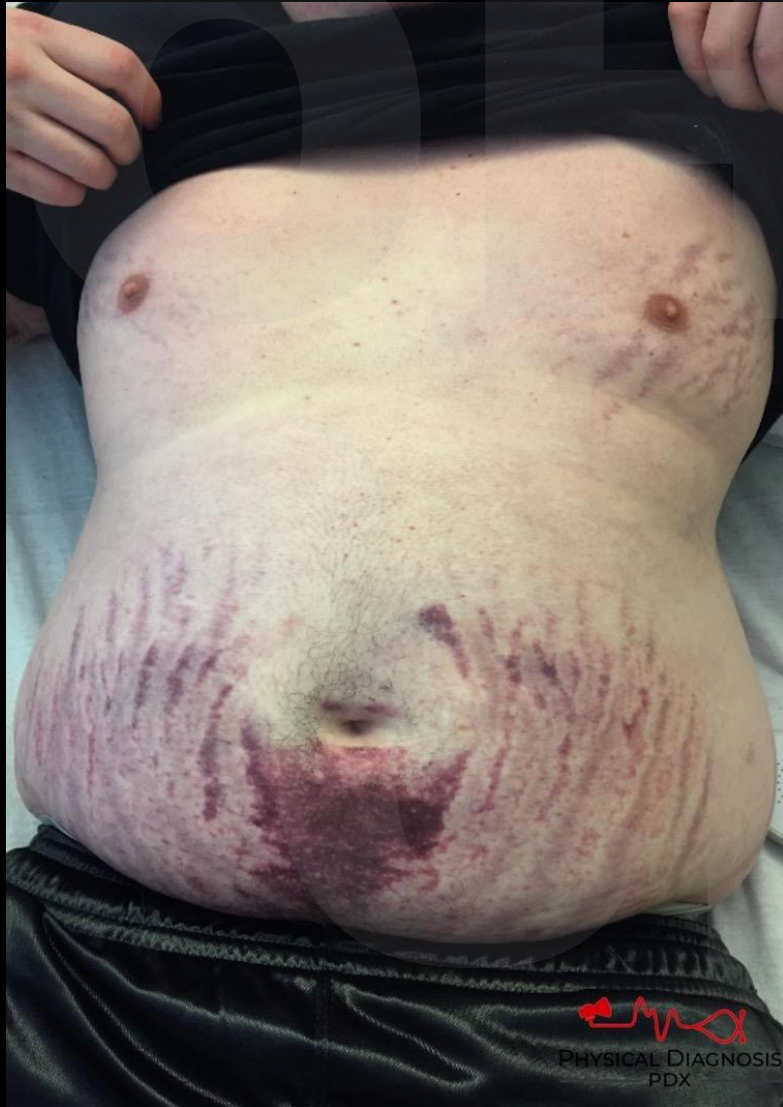Case #7: 65 y/o man with dyspnea

- Clinical findings:
 - Kussmaul's sign
 - Radiation tattoo marker
 - Pericardial knock
- Underlying diagnosis: **Constrictive pericarditis**

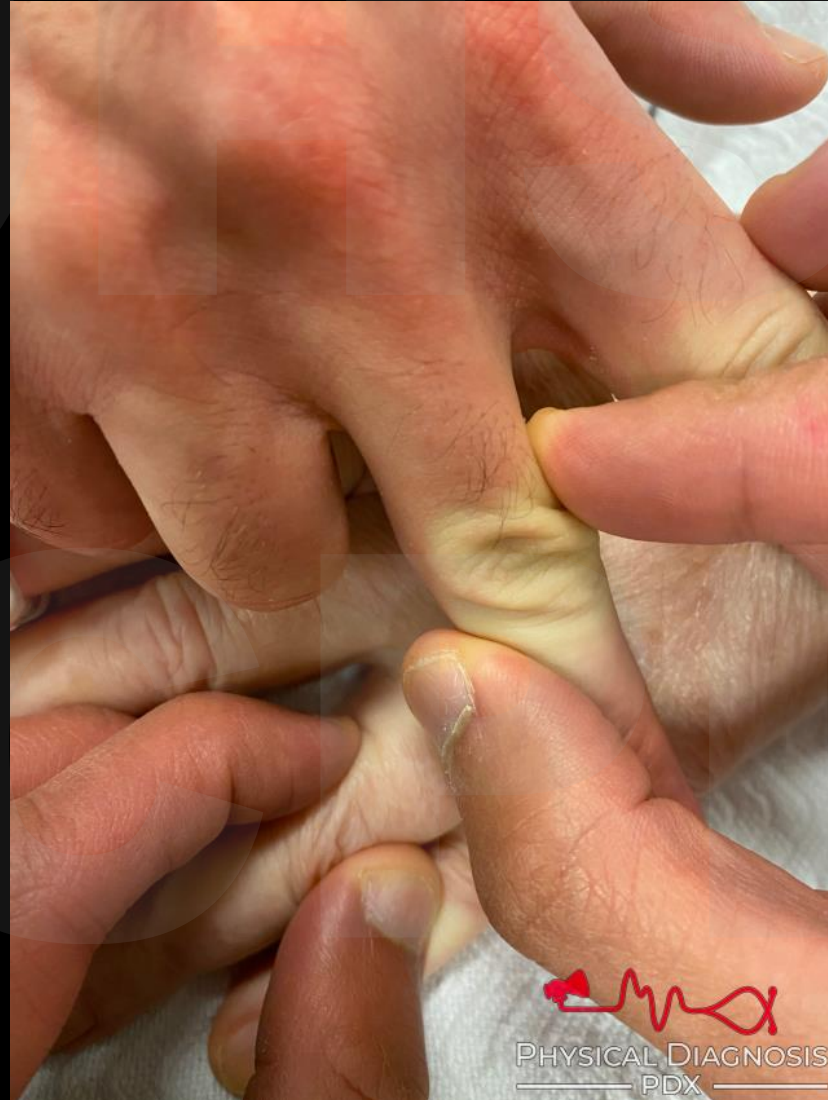Case #8: 28 y/o man with rapid weight gain



Case #8: 28 y/o man with rapid weight gain



Case #8: 28 y/o man with rapid weight gain



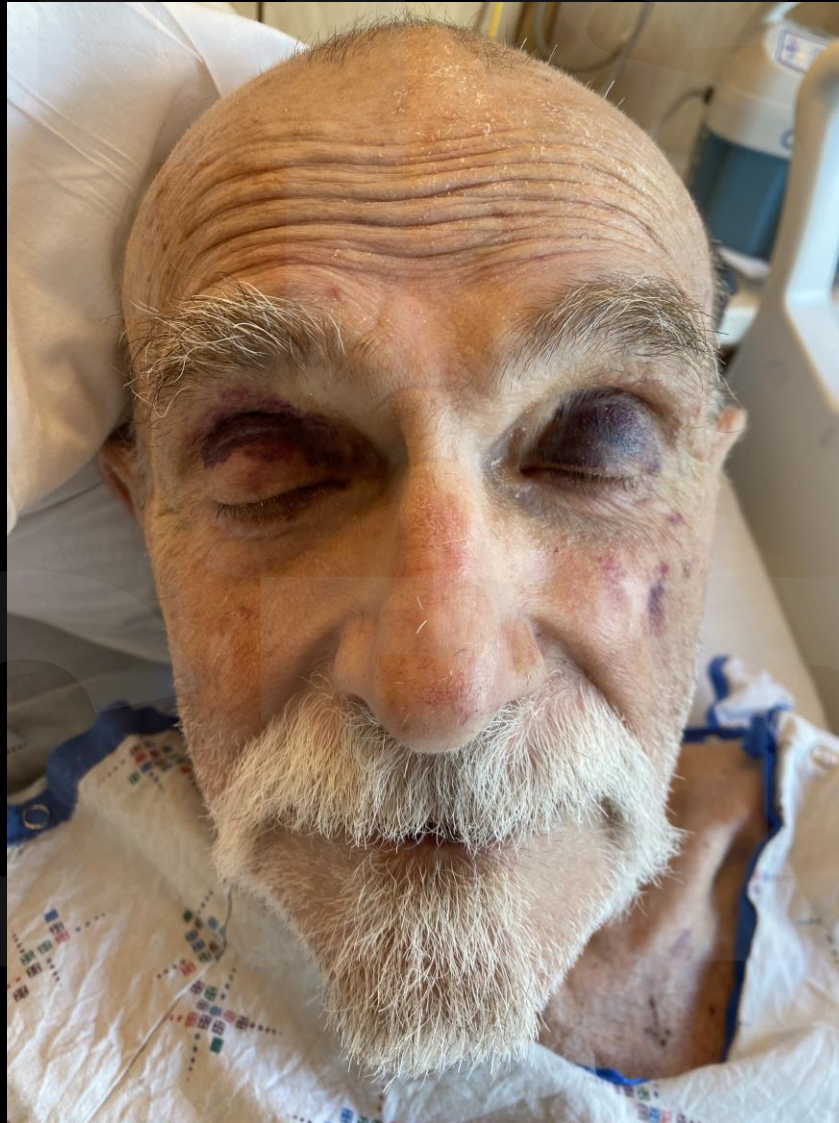Case #8: 28 y/o man with rapid weight gain

- Clinical findings:
 - Moon facies
 - Acne
 - Abdominal striae
 - Buffalo hump
 - Thin skin
- Underlying diagnosis: ?

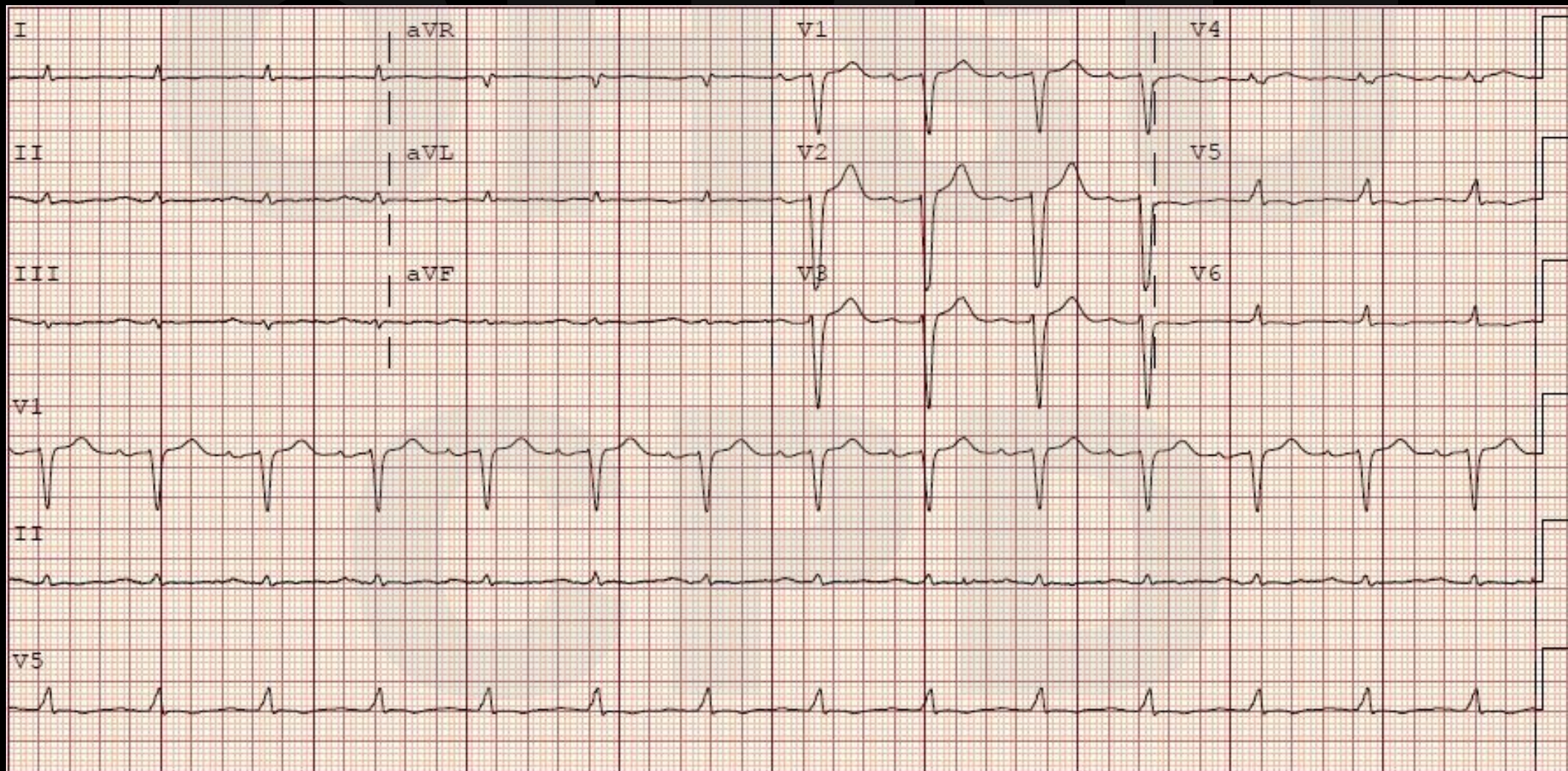
Case #8: 28 y/o man with rapid weight gain

- Clinical findings:
 - Moon facies
 - Acne
 - Abdominal striae
 - Buffalo hump
 - Thin skin
- Underlying diagnosis: **Cushing's syndrome**

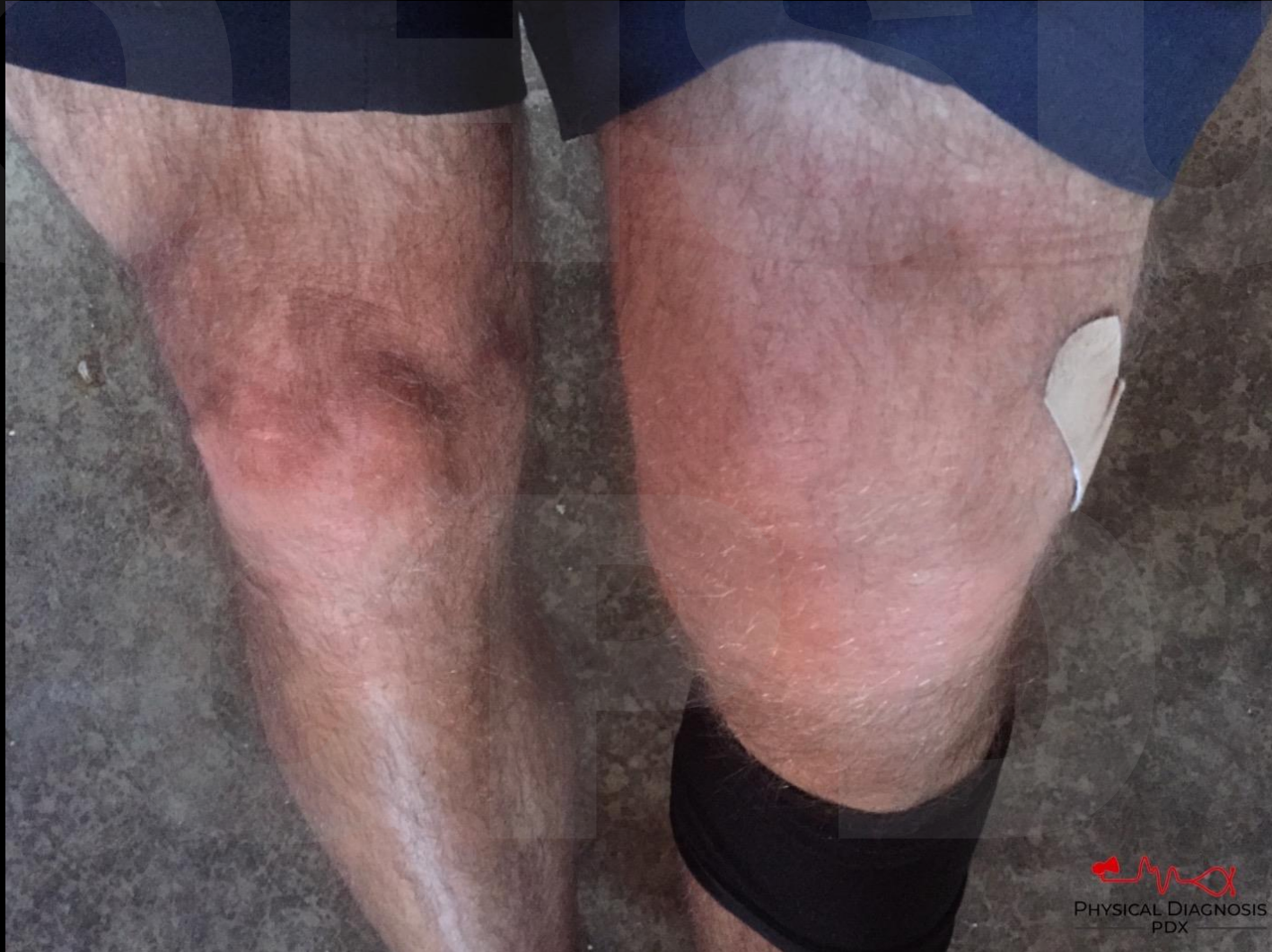Augenblick



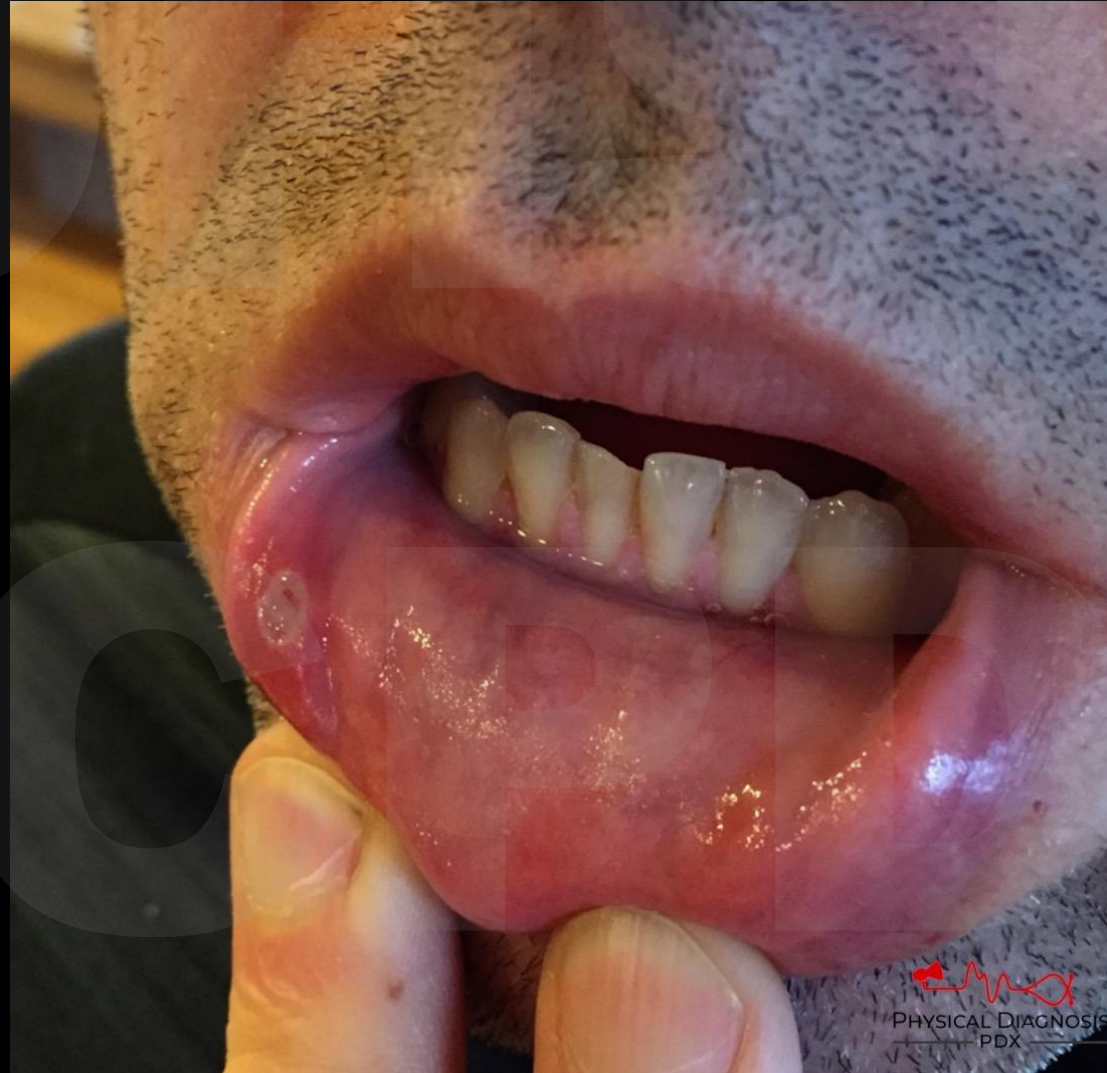Augenblick



Case #9: 37 y/o man with a painful knee



Case #9: 37 y/o man with a painful knee



Case #9: 37 y/o man with a painful knee

- Clinical findings:
 - Arthritis
 - Oral ulcers
- **Underlying diagnosis: ?**

Case #9: 37 y/o man with a painful knee

- Clinical findings:
 - Arthritis
 - Oral ulcers
- Underlying diagnosis: **Reactive arthritis**

Case #9: 37 y/o man with a painful knee

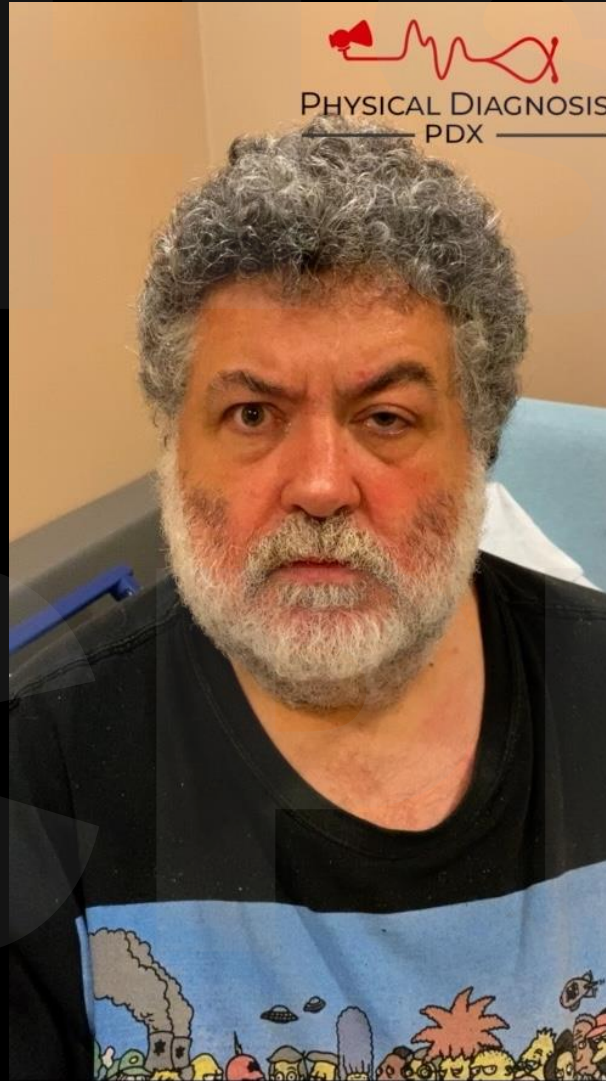

Case #10: 55 y/o M with EtOH withdrawal

OHSU

CPD

Case #10: 55 y/o M with EtOH withdrawal



Case #10: 55 y/o M with EtOH withdrawal



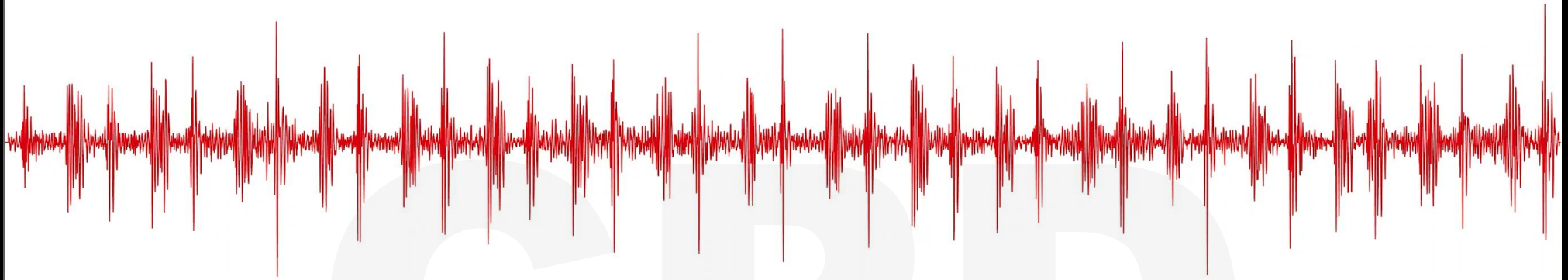
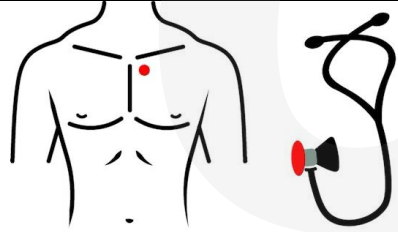
Case #10: 55 y/o M with EtOH withdrawal

- Clinical findings:
 - Unilateral ptosis
 - Fatigability
- **Underlying diagnosis: ?**

Case #10: 55 y/o M with EtOH withdrawal

- Clinical findings:
 - Unilateral ptosis
 - Fatigability
- Underlying diagnosis: **Myasthenia gravis**

Case #10: 55 y/o M with EtOH withdrawal



Case #10: 55 y/o M with EtOH withdrawal



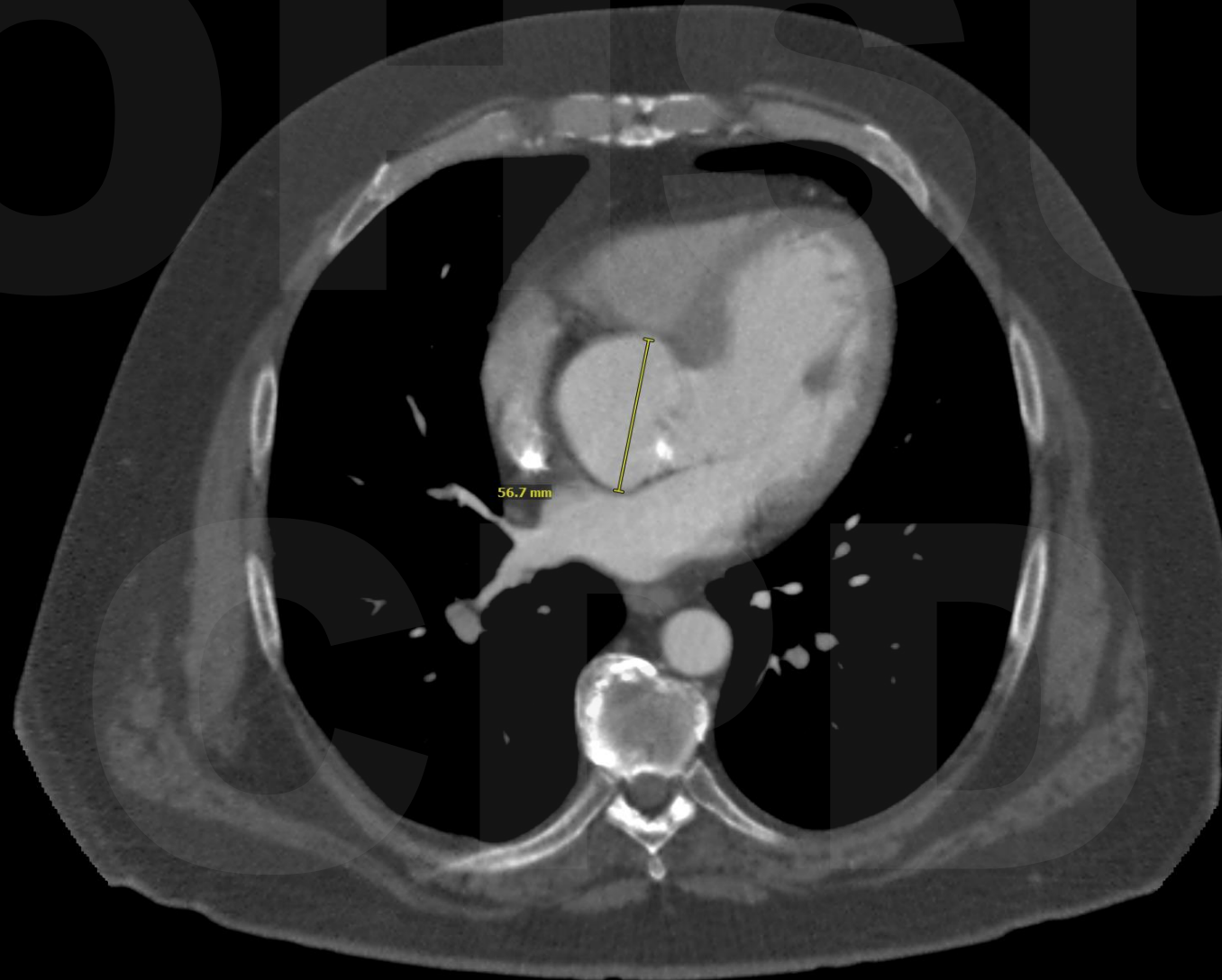
Case #10: 55 y/o M with EtOH withdrawal



Case #10: 55 y/o M with EtOH withdrawal

- Clinical findings:
 - Extra transient heart sound heard near S1
 - High pitched
 - Best heard over the base of the heart
- **Underlying diagnosis: ?**

Case #10: 55 y/o M with EtOH withdrawal



Case #10: 55 y/o M with EtOH withdrawal

- Clinical findings:
 - Extra transient heart sound heard near S1
 - High pitched
 - Best heard over the base of the heart
- Underlying diagnosis: **Dilated aortic aneurysm (6 cm)**

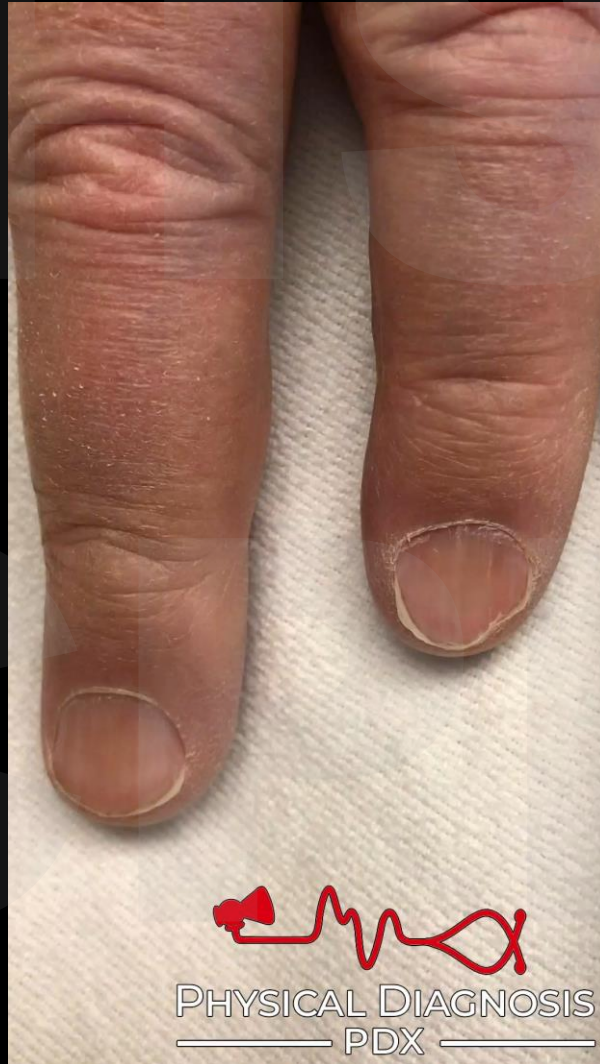Case #11: 62 y/o man with heart failure

T 36.8, HR 84, BP 177/56 mm Hg, RR 16

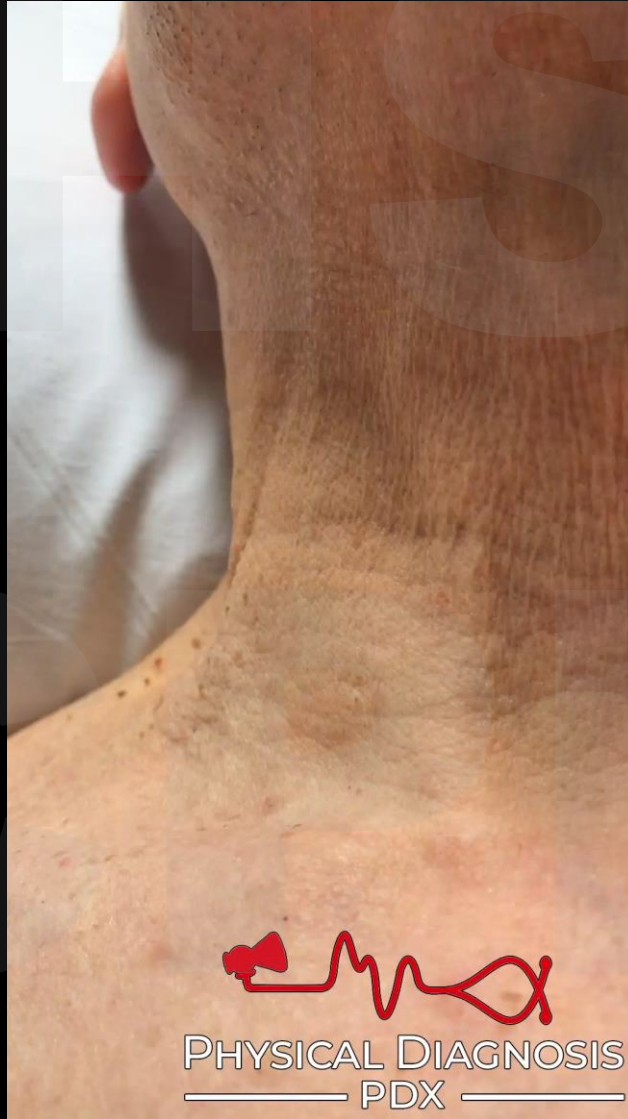Case #11: 62 y/o man with heart failure

T 36.8, HR 84, BP 177/56 mm Hg, RR 16

Case #11: 62 y/o man with heart failure



Case #11: 62 y/o man with heart failure



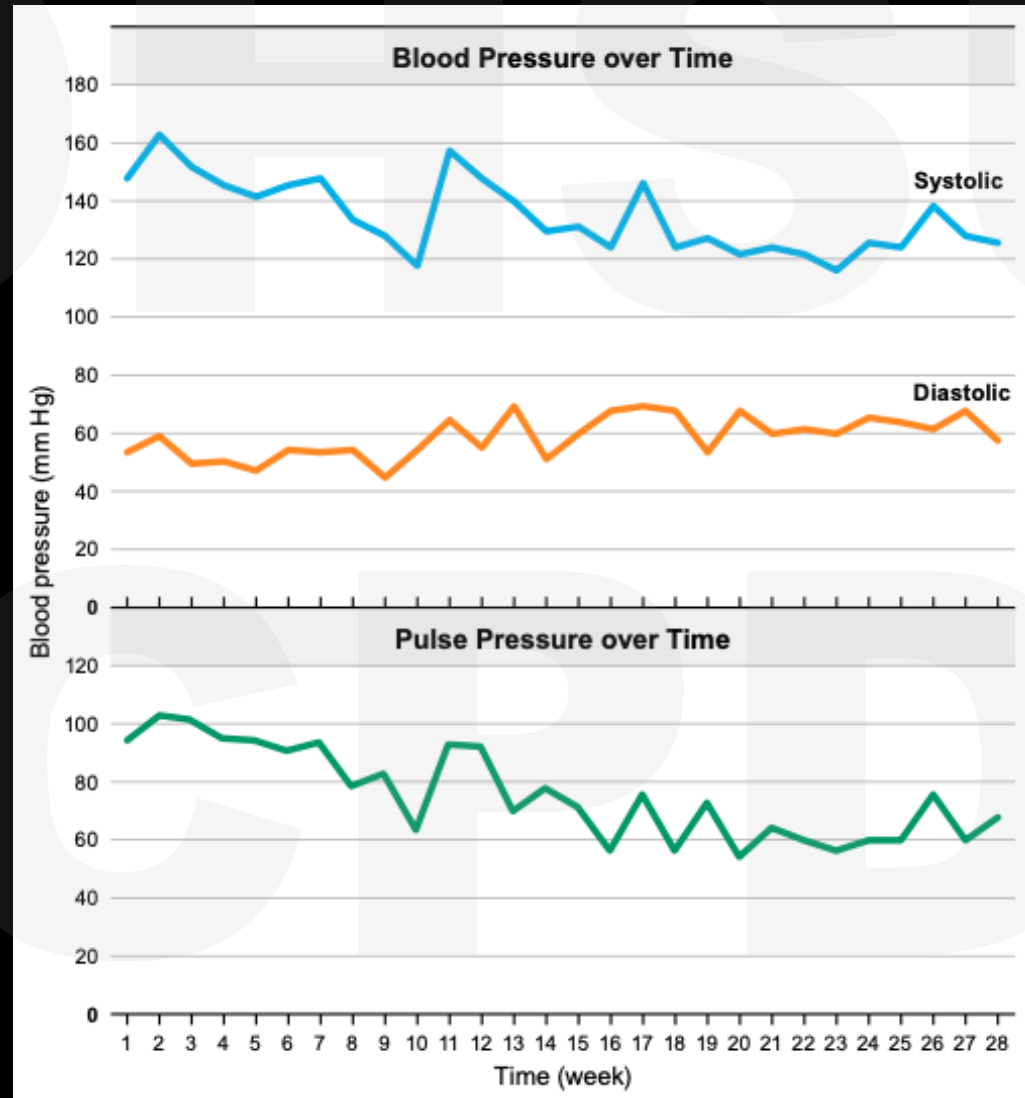
Case #11: 62 y/o man with heart failure

- Clinical findings:
 - Wide pulse pressure
 - Quincke's pulse
 - Bounding peripheral pulse
- **Underlying diagnosis: ?**

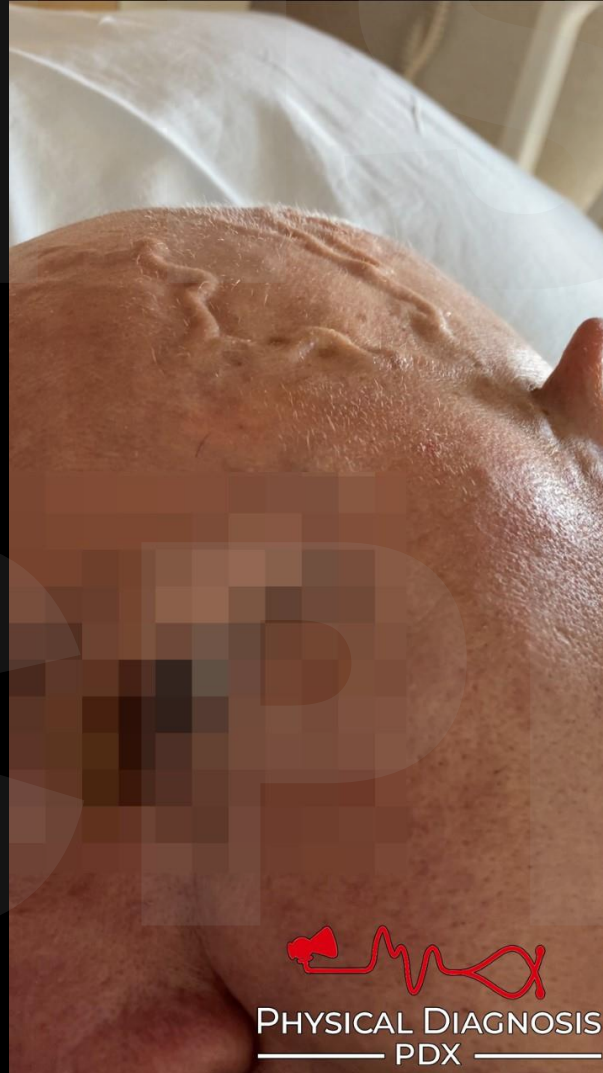Case #11: 62 y/o man with heart failure

- Clinical findings:
 - Wide pulse pressure
 - Quincke's pulse
 - Bounding peripheral pulse
- Underlying diagnosis: **Wet beriberi (thiamine deficiency)**

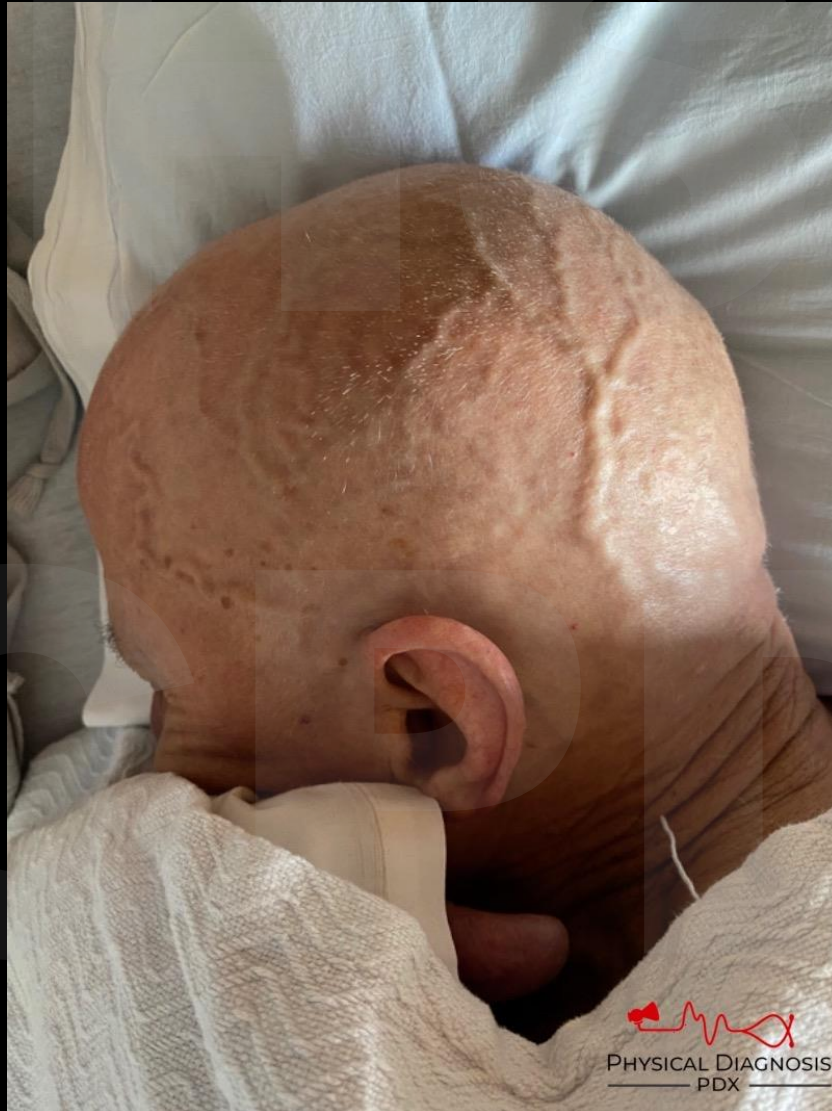Case #11: 62 y/o man with heart failure



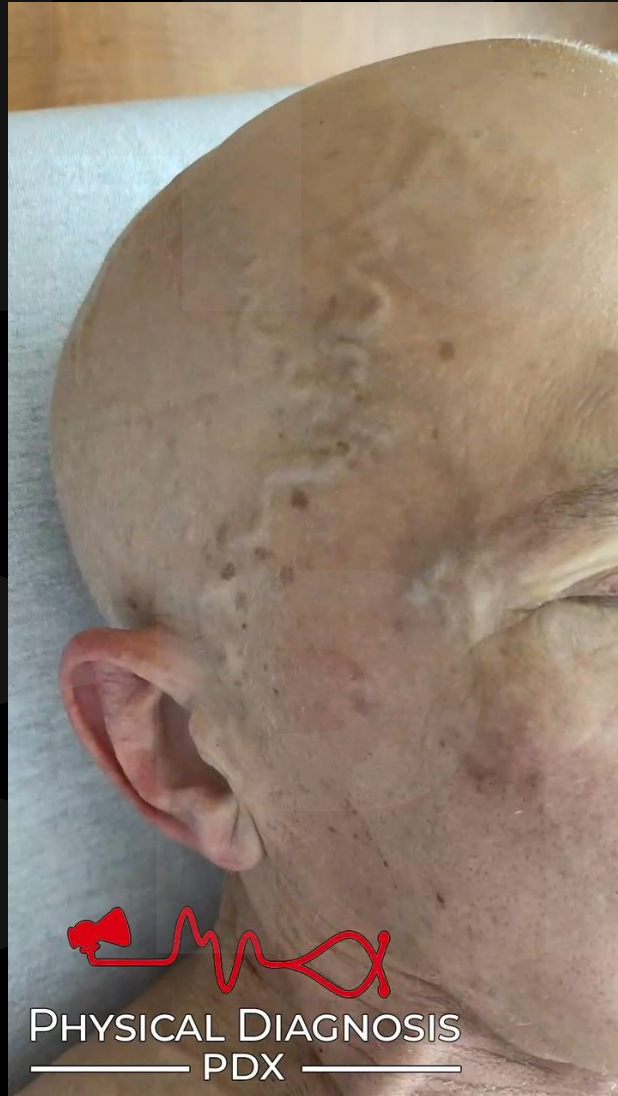Case #12: 55 y/o man w ascites



Case #12: 55 y/o man w ascites



Case #12: 55 y/o man w ascites



PHYSICAL DIAGNOSIS
PDX

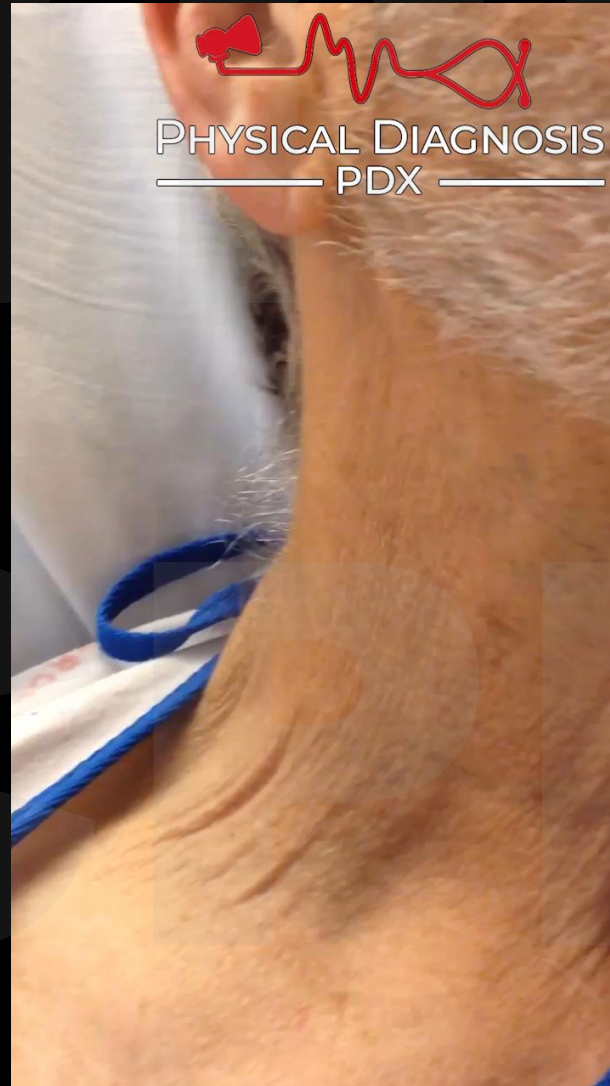Case #12: 55 y/o man w ascites

- Clinical findings:
 - Dilated head veins
- **Underlying diagnosis: ?**

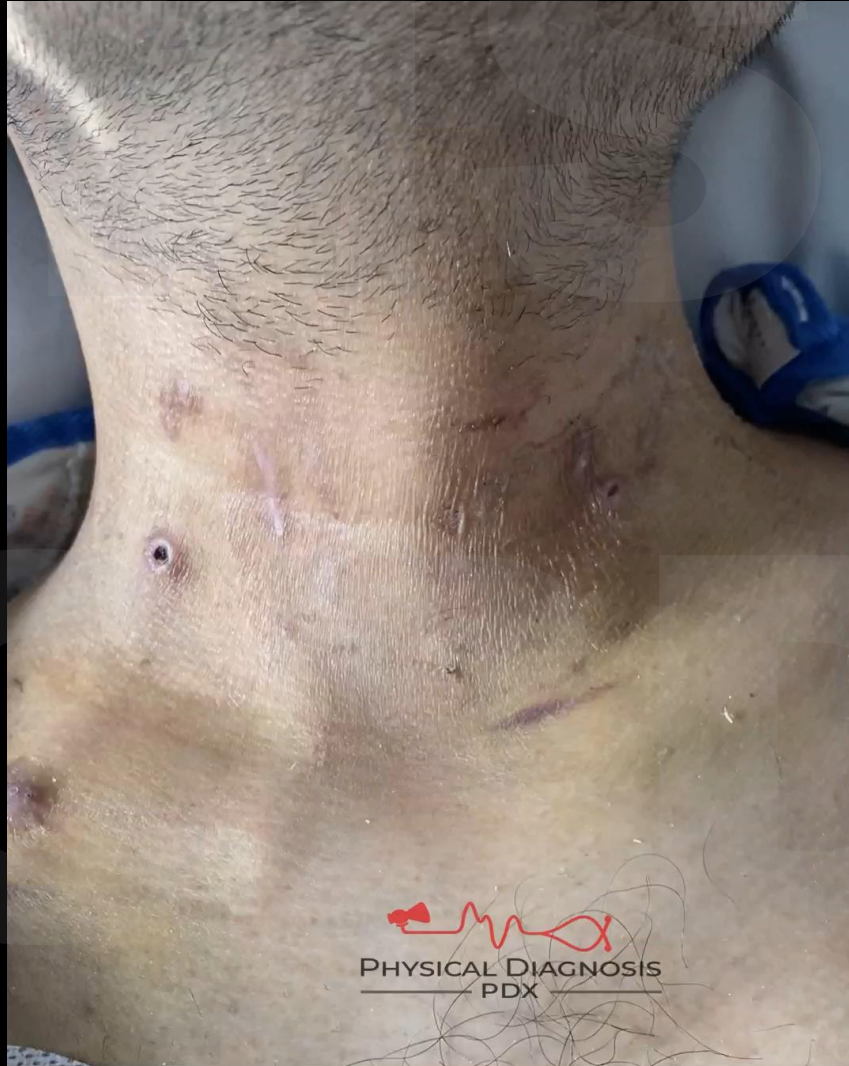Case #12: 55 y/o man w ascites

- Clinical findings:
 - Dilated head veins
- **Underlying diagnosis: Heart failure**

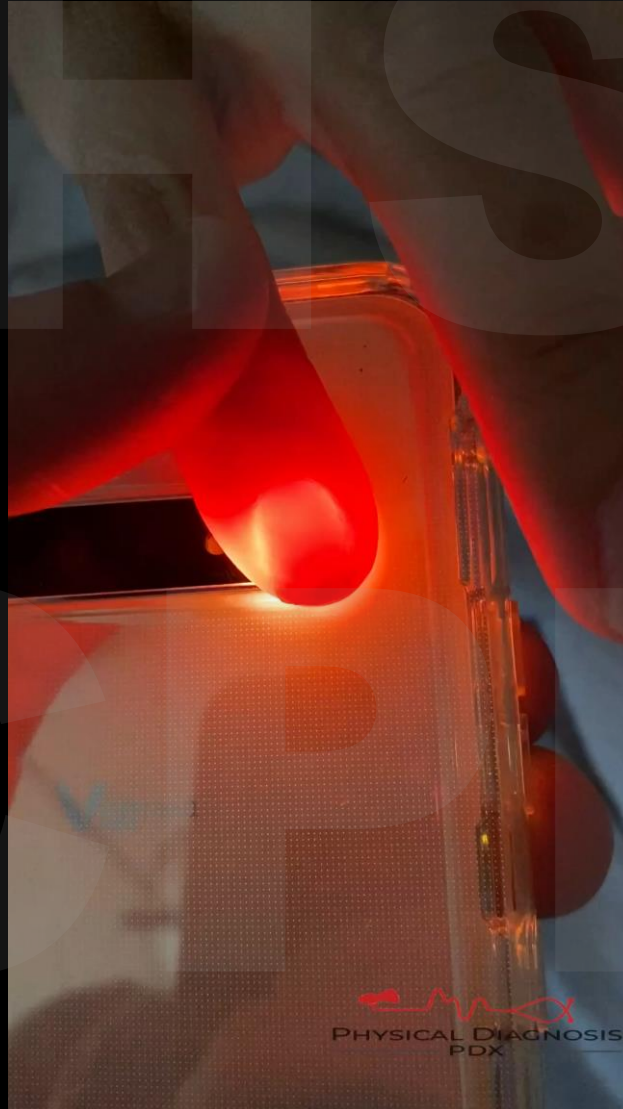
Augenblick



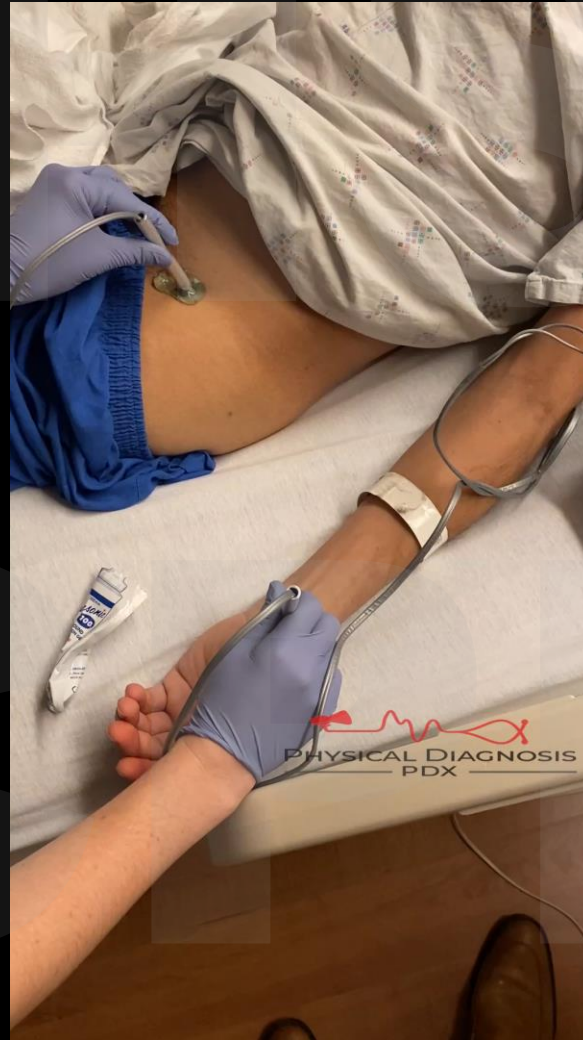Case #13: 44 y/o man w heart failure



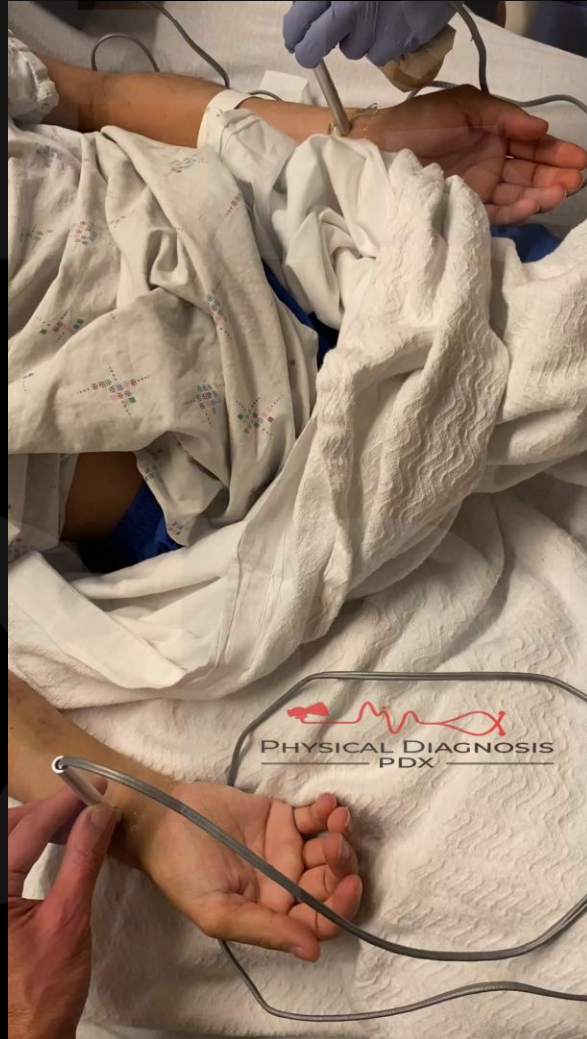Case #13: 44 y/o man w heart failure



Case #13: 44 y/o man w heart failure



Case #13: 44 y/o man w heart failure



Case #13: 44 y/o man w heart failure



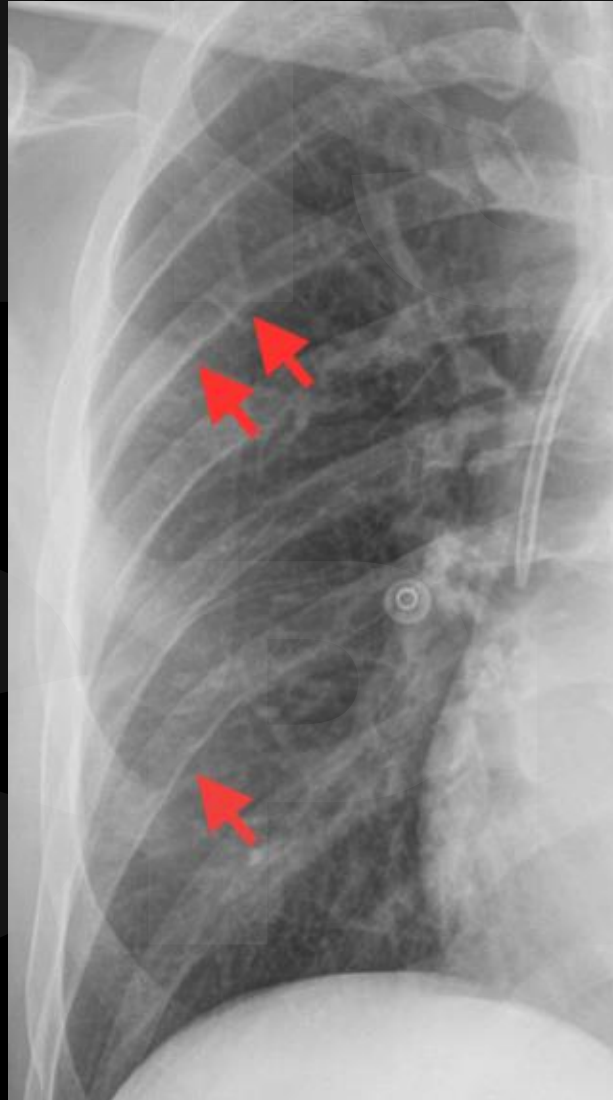
Case #13: 44 y/o man w heart failure

- Clinical findings:
 - Bounding carotid pulse
 - Quincke's pulse
 - Radial-femoral pulse delay
- **Underlying diagnosis: ?**

Case #13: 44 y/o man w heart failure

- Clinical findings:
 - Bounding carotid pulse
 - Quincke's pulse
 - Radial-femoral pulse delay
- Underlying diagnosis: **Coarctation of the aorta**

Case #13: 44 y/o man w heart failure



OH SU
THANK YOU

CPD

Additional Resources

- For more:
 - Physical Diagnosis PDX (www.pdxdx.com)
 - Email: mansooan@ohsu.edu