



OHSU

A Simple Approach to MSK Physical Exam

Jesse Day, MD
Assistant Professor
Physical Medicine & Rehabilitation
Oregon Health & Science University

What are we covering?

- Anatomy review
- How to structure examination
- MSK exam
 - Hip
 - Knee
 - Shoulder

Why cover it?

- It's complicated!
- Infrequently taught/poorly covered
- Common complaints
- It's easy to break down and complete quickly

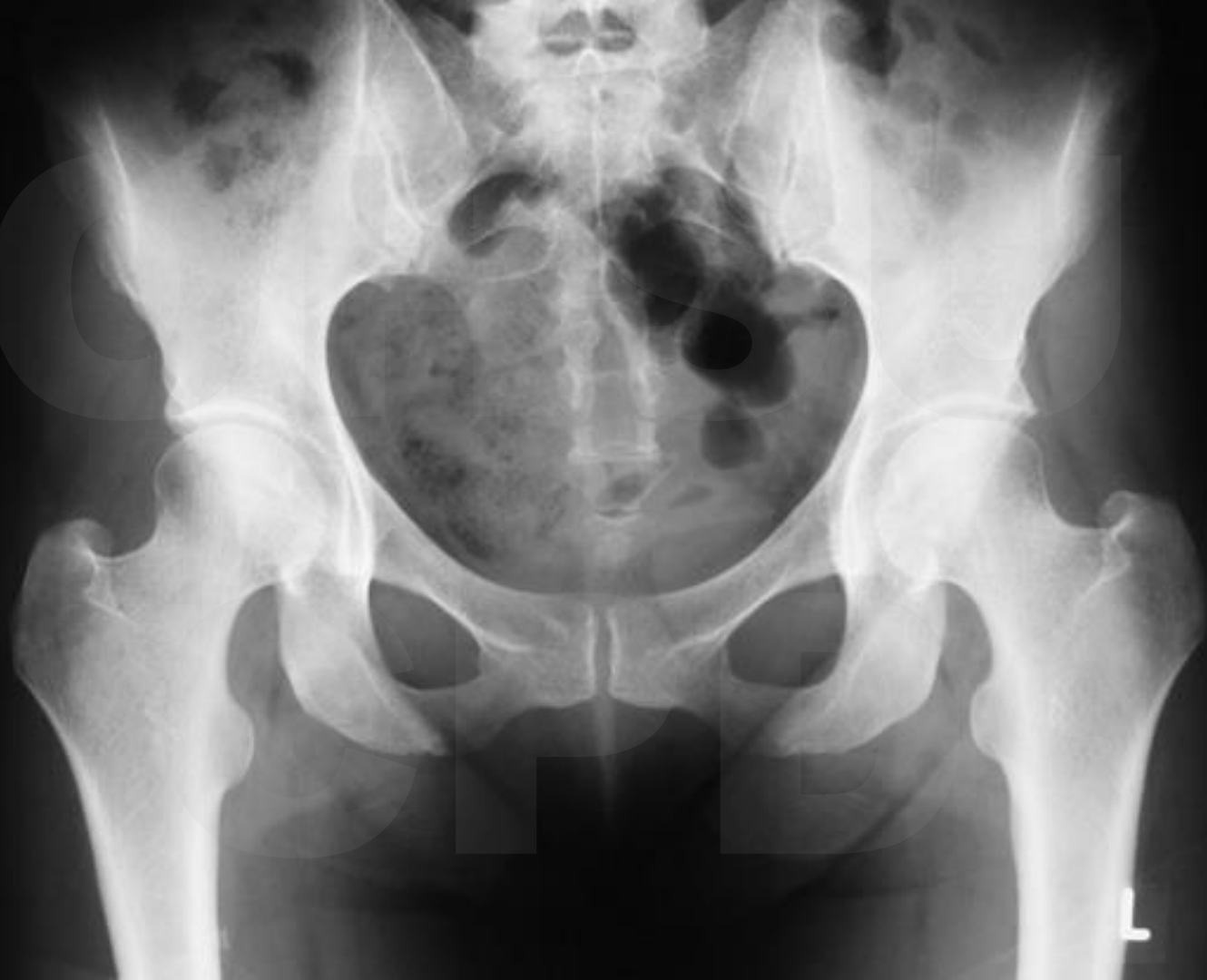Disclosures

- None

Important Concepts!

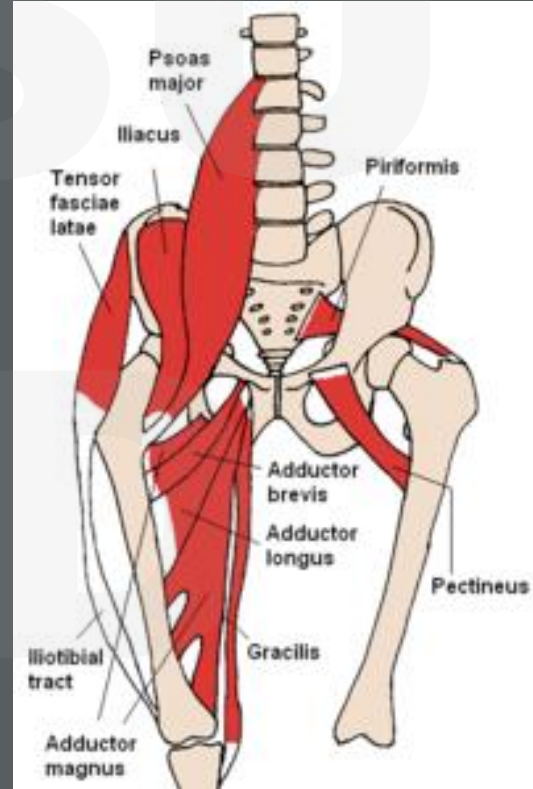
- **Not all positive exams have meaning!!** I won't be including sn/sp for time's sake, but use your common sense
- **You should be thinking about WHAT pain/symptoms you're reproducing**
 - Is it causing pain where you'd expect given the structure you're testing
 - Is it causing the pain/symptoms that the patient has
- **Always consider mimics and focus your exam** -> move to a more broad exam if you need

HIP



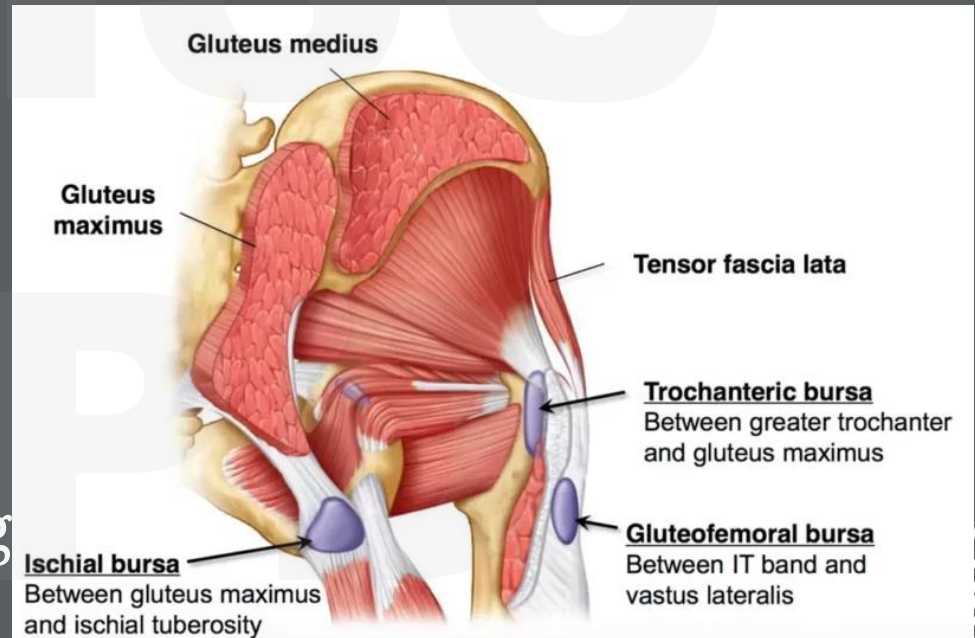
How I think about the hip:

- Anterior
- Lateral
- Posterior
- Mimics
 - (will discuss tangentially)



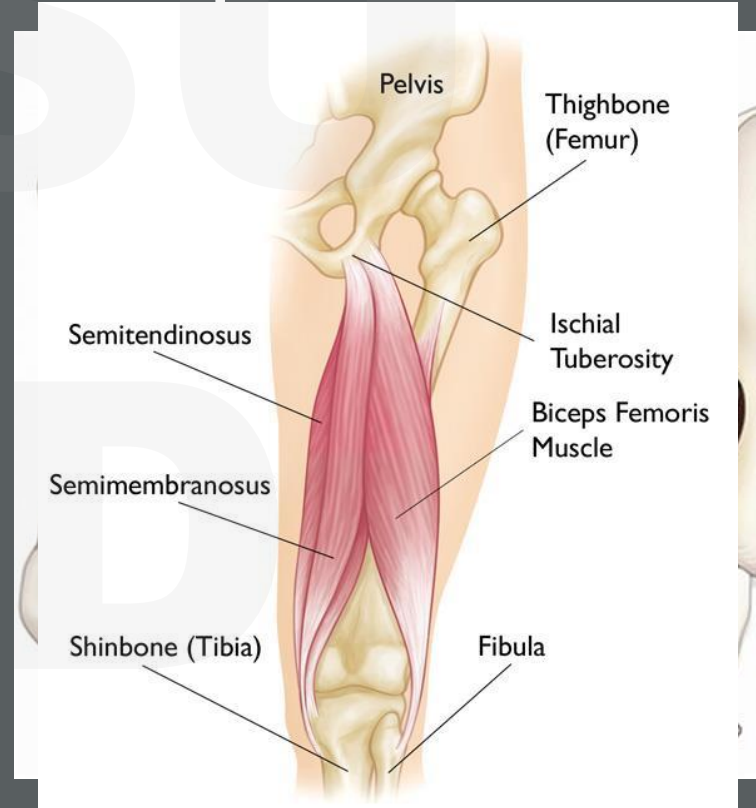
How I think about the hip:

- Anterior
- **Lateral**
- Posterior
- Mimics
 - (will discuss tang



How I think about the hip:

- Anterior
- Lateral
- **Posterior**
- Mimics
 - (will discuss tangentially)



General Exam Points

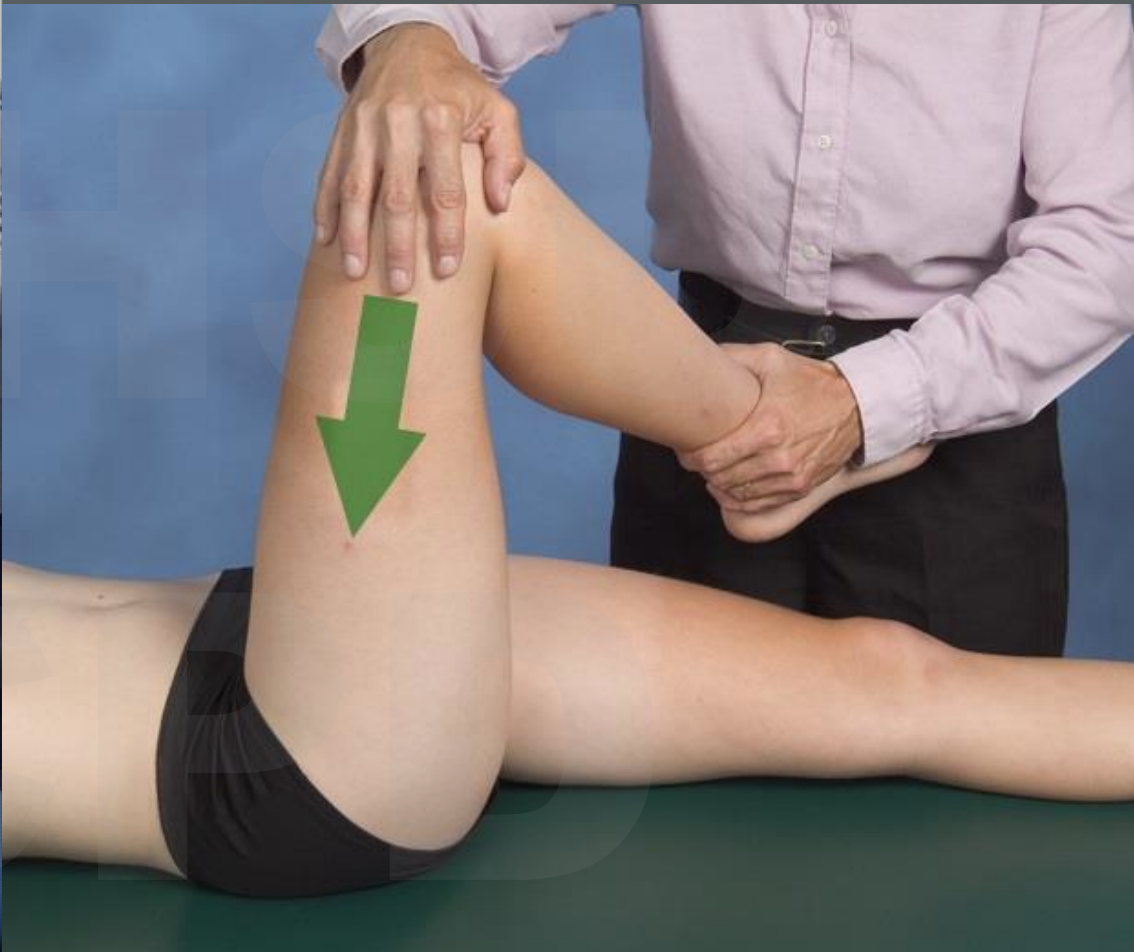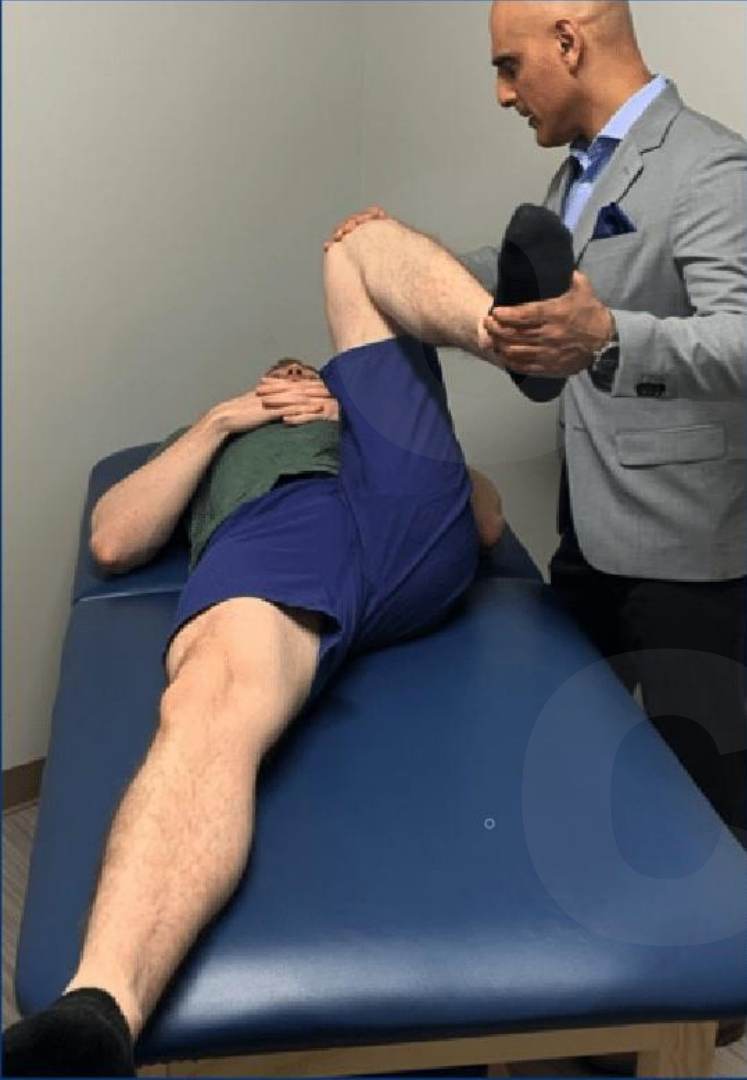- ROM (gross restriction)
- TTP (in area of interest)
- Special exam (targeted)

So how do we evaluate these?

- Anterior
- Lateral
- Posterior

So how do we evaluate these?

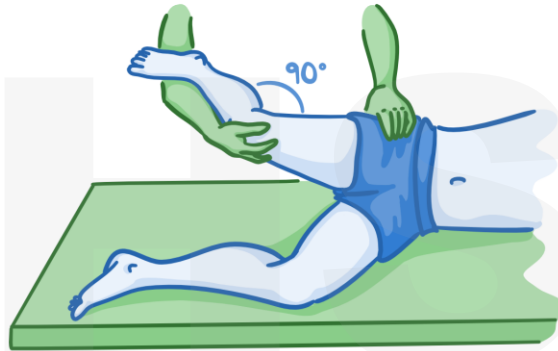
- **Anterior**
 - Intraarticular (cartilage, labrum)
 - FADIR, deep flexion, scour
 - Hip flexor
 - Resisted hip flexion, palpation



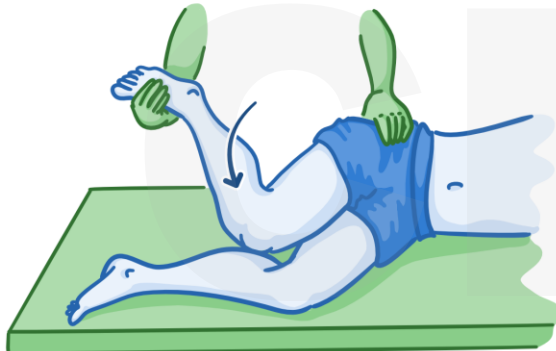So how do we evaluate these?

- Lateral
 - IT band (TTP distal IT, Ober's)
 - Greater trochanteric pain syndrome (GT bursitis, IT friction, gluteal tendinopathy) (TTP over GT)

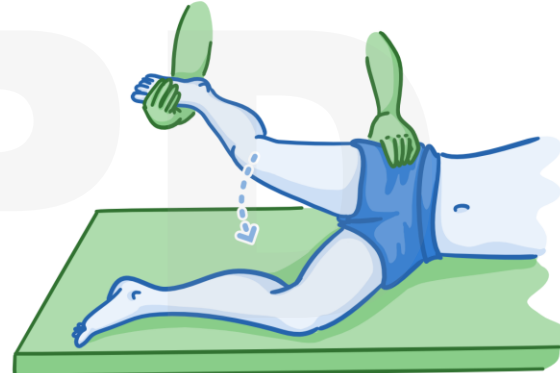OBER TEST



NEGATIVE



POSITIVE



So how do we evaluate these?

- Posterior
 - SI joint (FABER, Fortin Finger, SI shear/thigh thrust)
 - Deep external rotators (TTP, resisted ER)
 - Hamstring (TTP/resisted knee flexion)
 - Intraarticular hip (already covered!)

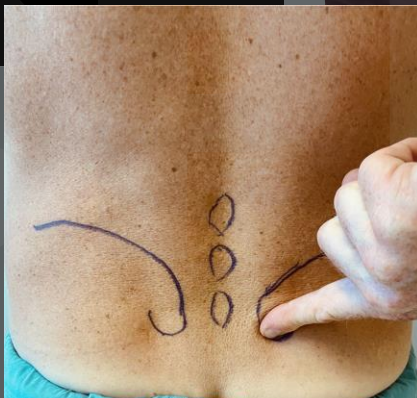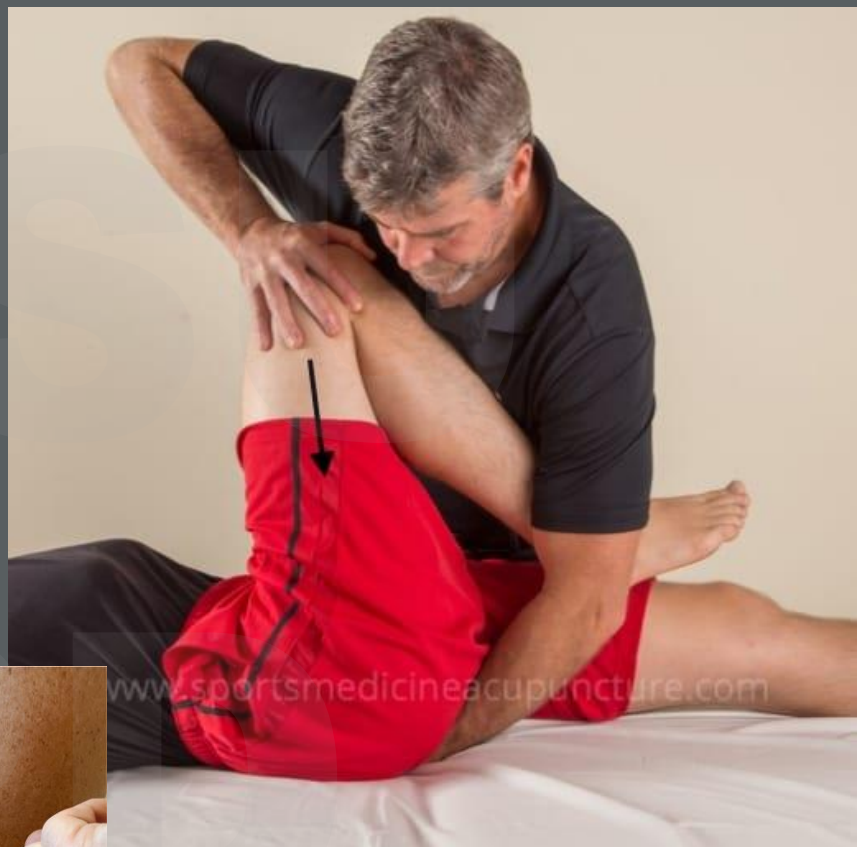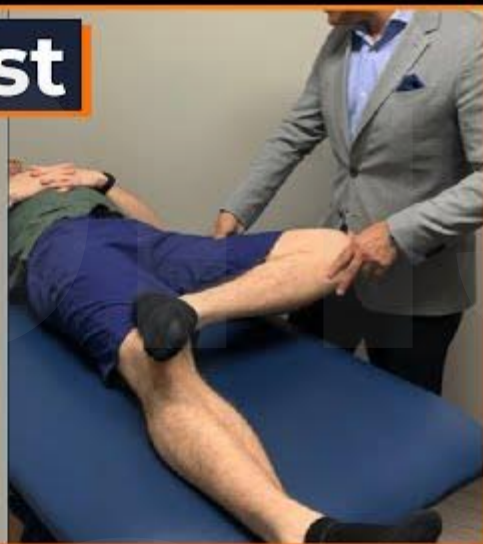FABER Test

(Flexion

Abduction

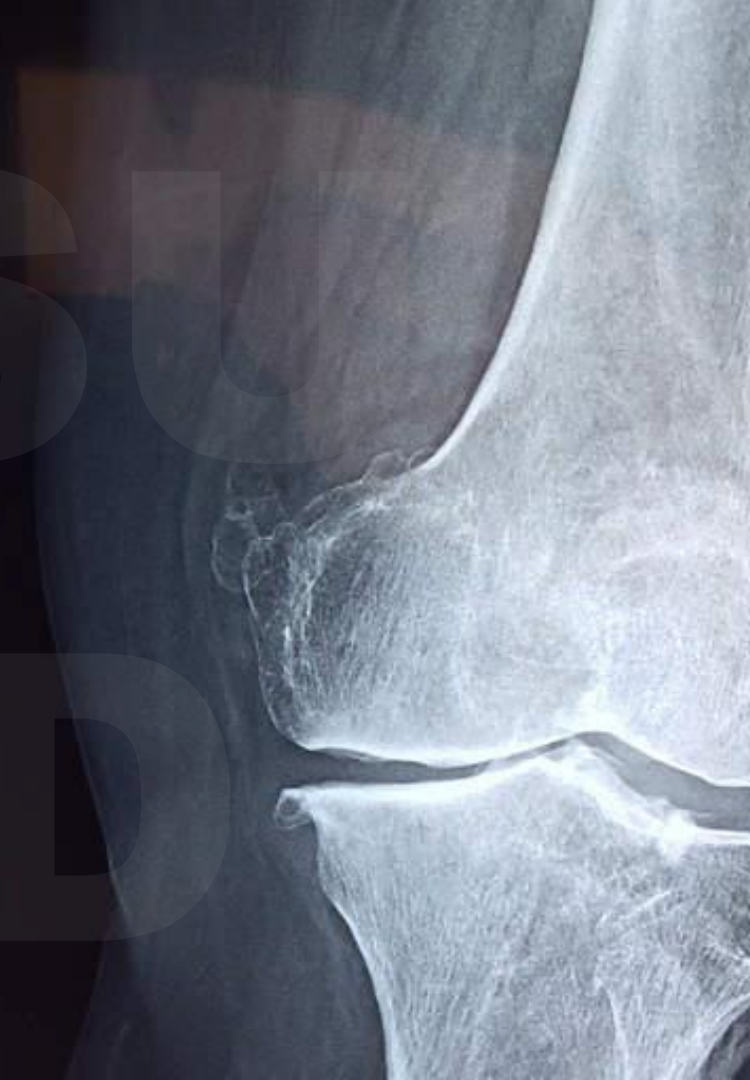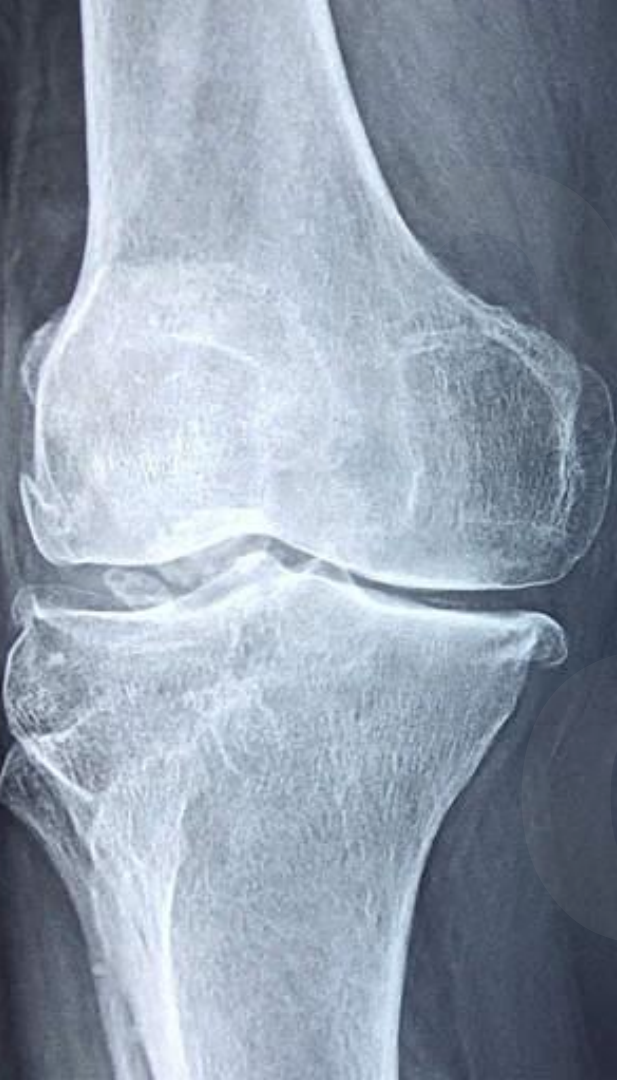External

Rotation)



Hip Exam Summary

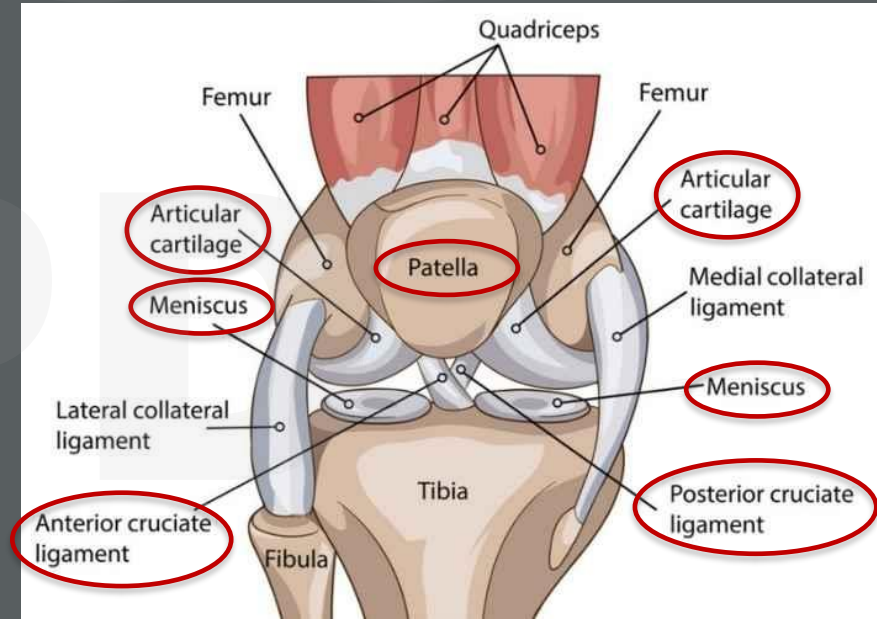
- ROM
- Palpate area(s) of interest
- FADIR, deep flexion, Scour
- Ober's
- FABER, SI joint shear, Fortin Finger test
- Resisted knee flexion



KNEE

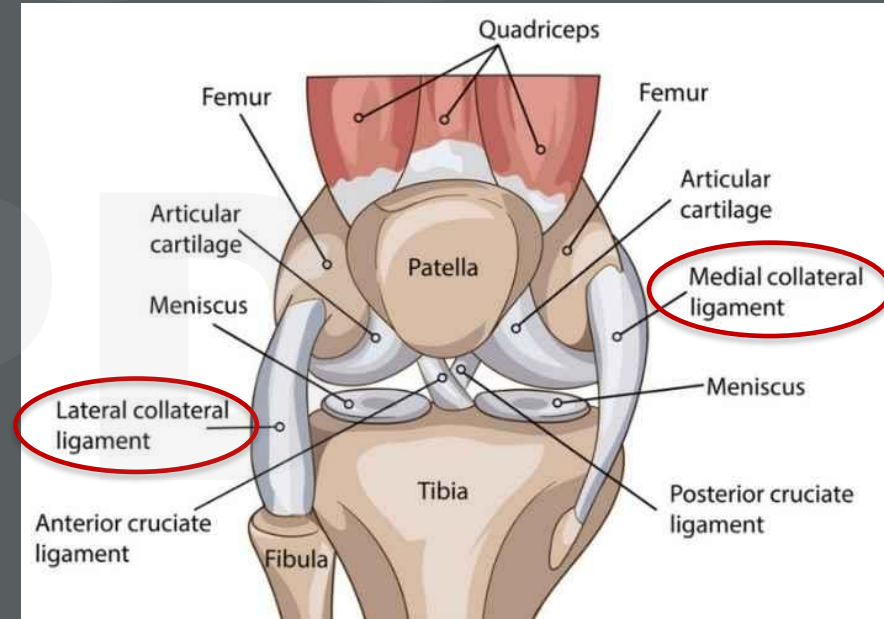
How I think about the knee:

- Anterior (medial/lateral)
- Lateral/Medial (far)
- Posterior



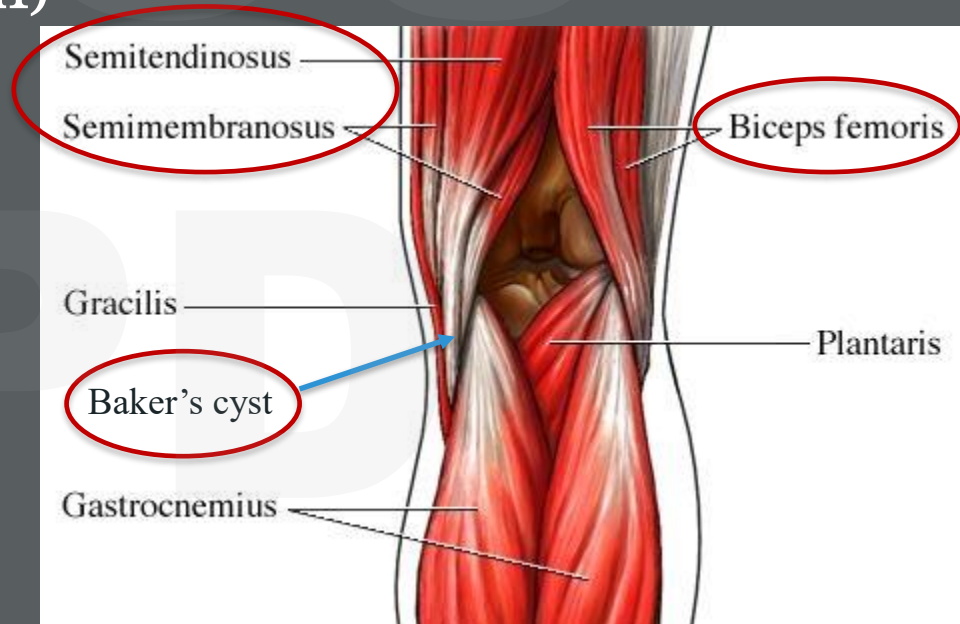
How I think about the knee:

- Anterior (medial/lateral)
- **Lateral/Medial (far)**
- Posterior



How I think about the knee:

- Anterior (medial/lateral)
- Lateral/Medial (far)
- **Posterior**

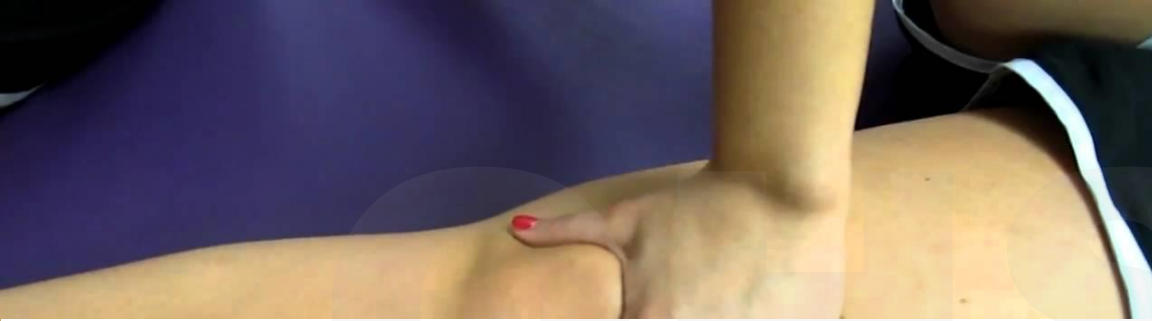

General Exam Points

- ROM (gross restriction)
- TTP (in area of interest)
- Special exam (targeted)


So how do we evaluate these?

- **Anterior (medial/lateral)**
 - Cartilage/OA (TTP joint lines, imaging)
 - Patellofemoral (patellar grind)
 - ACL/PCL (anterior/posterior drawer)
 - Meniscus (McMurray, Thessaly)

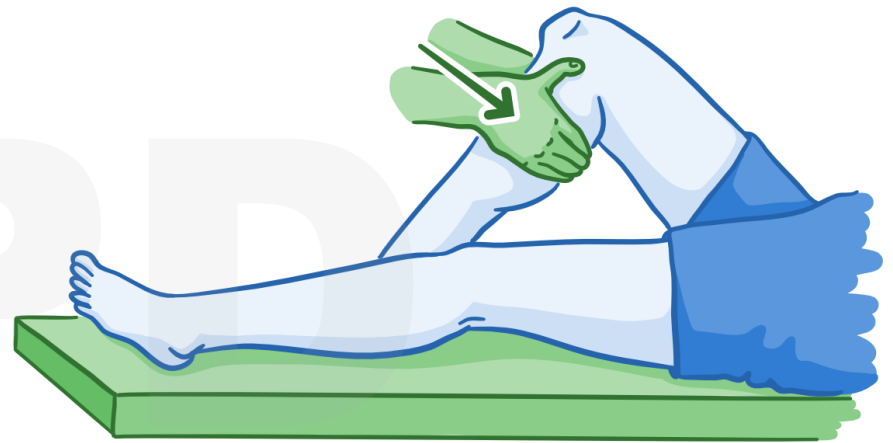

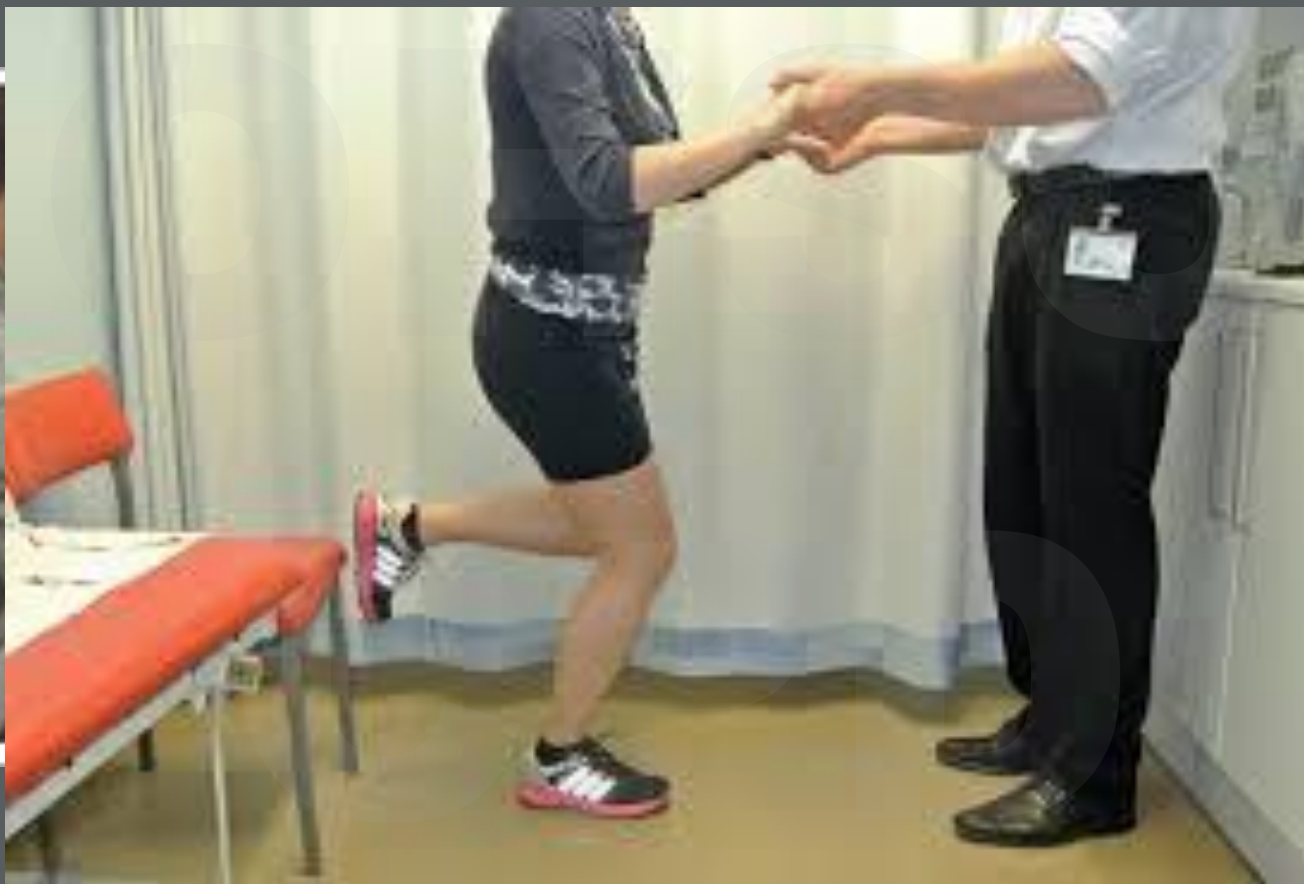KNEE DRAWER TESTS

ANTERIOR



POSTERIOR

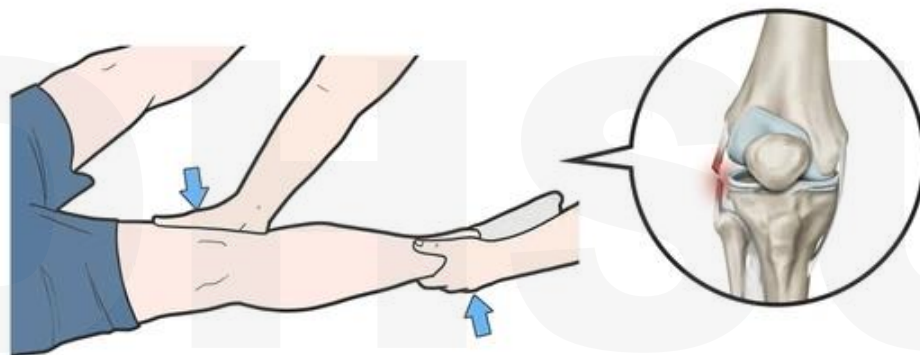




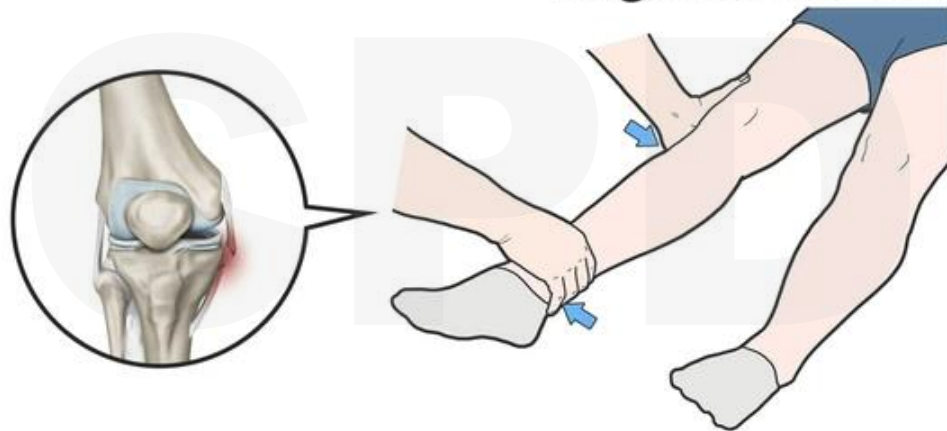
So how do we evaluate these?

- Lateral/Medial (far)
 - LCL (varus stress test)
 - MCL (valgus stress test)

Varus stress test



Valgus stress test



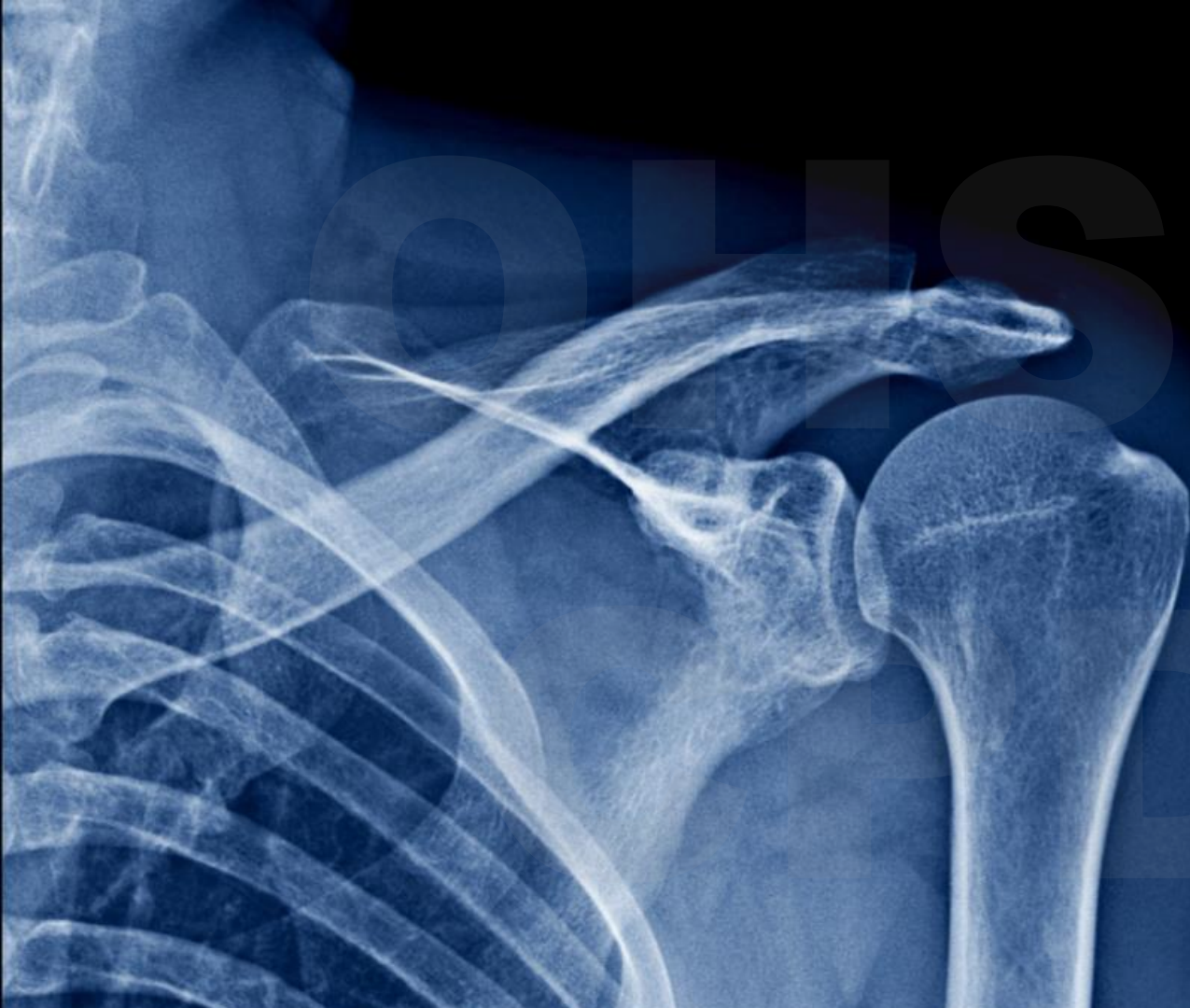How I think about the knee:

- Posterior
 - Baker's cyst (palpate posteromedial, US/MRI)
 - Distal hamstring (TTP, pain with resisted knee flexion)

Knee Exam Summary

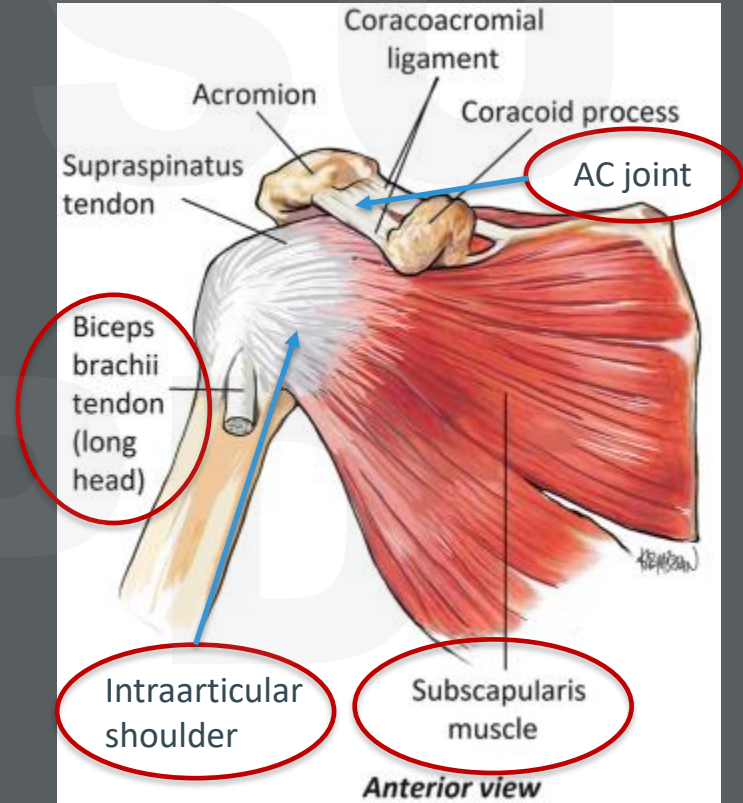
- ROM
- TTP (joint lines, MCL/LCL, hamstrings, Baker's)
- Anterior/posterior drawer
- McMurray vs Thessaly
- Varus/valgus stress
- Patellar grind
- Resisted knee flexion

SHOULDER



How I think about the shoulder:

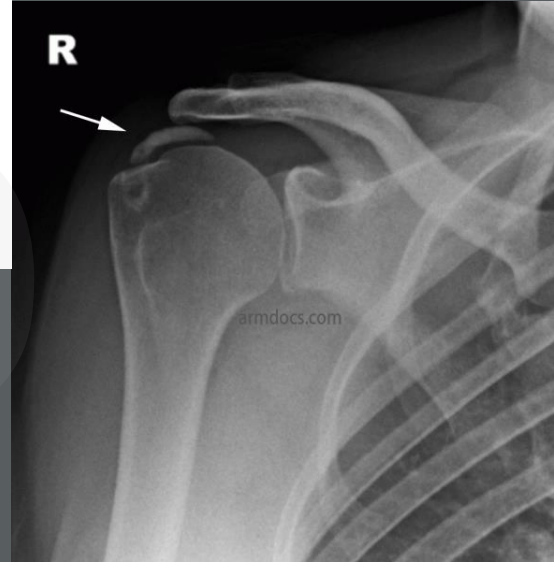
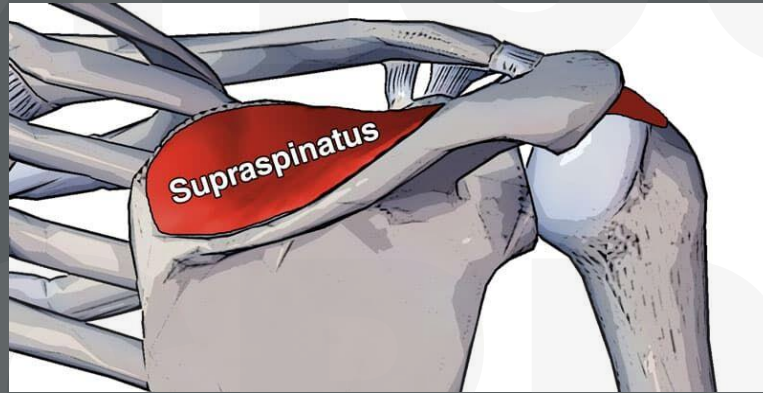
- Anterior
- Lateral
- Posterior
- Intra vs extraarticular



How I think about the shoulder:

- Anterior
- **Lateral**
- Posterior

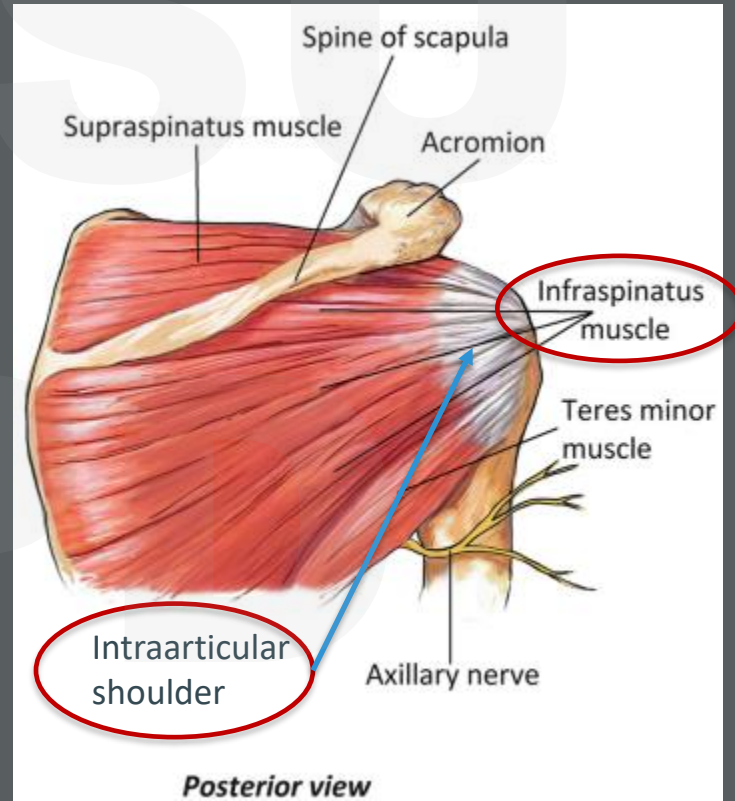
- Intra vs extraarticular



How I think about the shoulder:

- Anterior
- Lateral
- **Posterior**

- Intra vs extraarticular

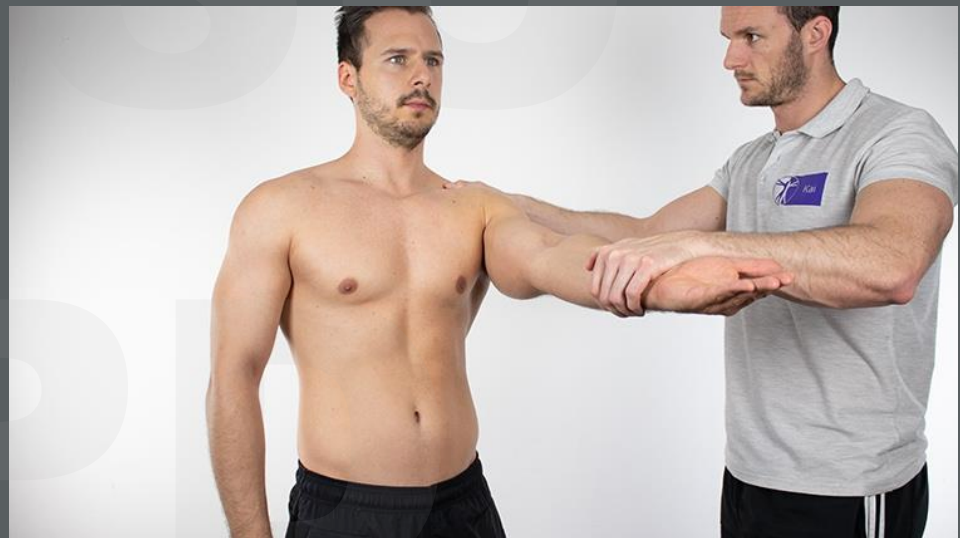
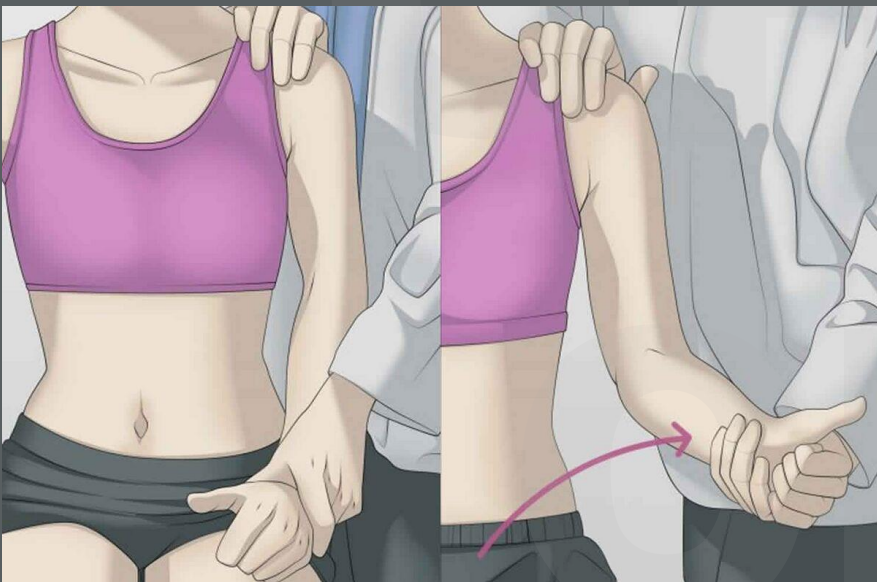


General Exam Points

- ROM (gross restriction)
- TTP (in area of interest)
- Special exam (targeted)

So how do we evaluate these?

- Anterior
 - Biceps long head (palpation, Speeds, Jergeson)
 - AC joint (palpation, scarf)
 - Subscapularis (belly press/lift off)
 - Joint/Labrum (O'Brien's)

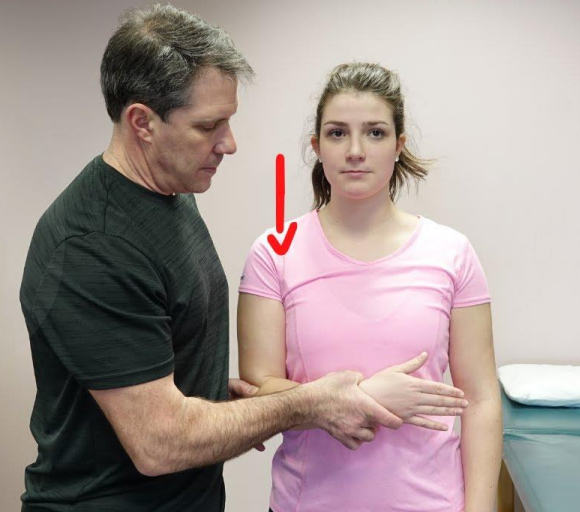

SCARF TEST



Belly Press Test

Subscapularis
Test



O'Brien's Test

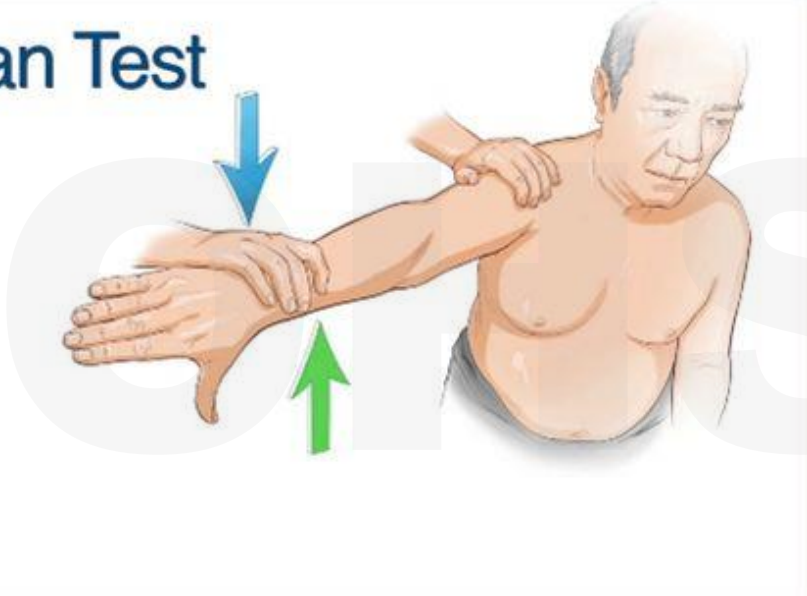
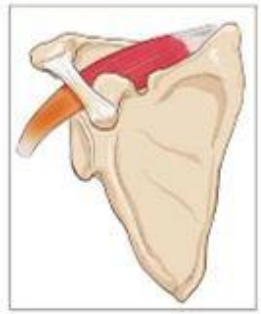Shoulder Exam



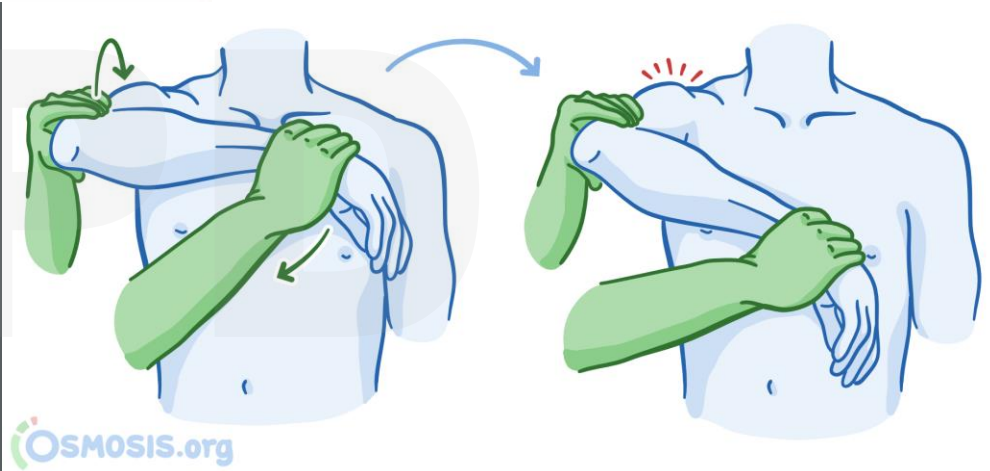So how do we evaluate these?

- Lateral
 - Supraspinatus/impingement (Hawkin's, Empty can)

Empty Can Test

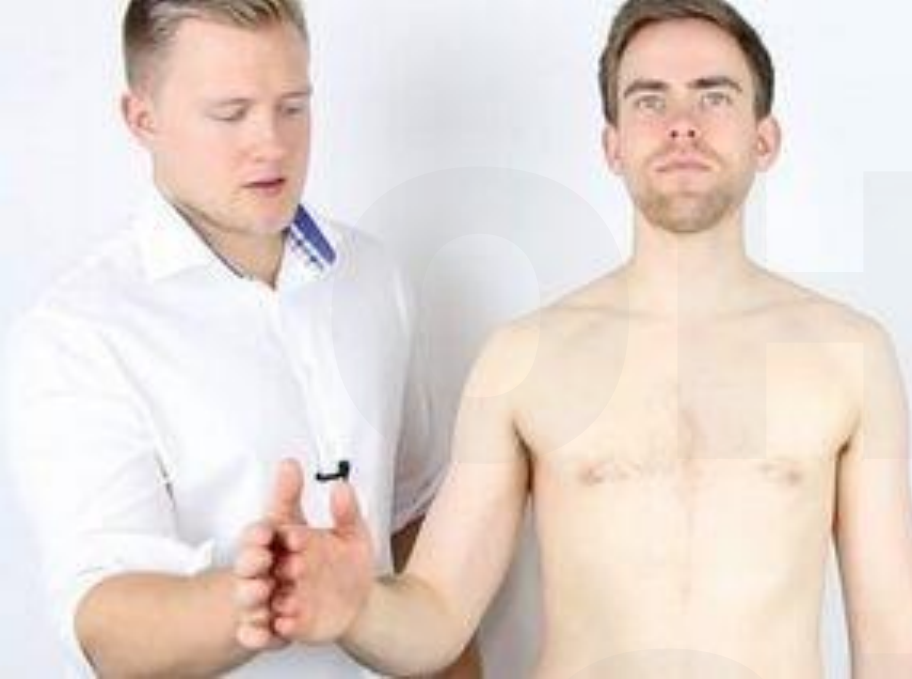

HAWKINS-KENNEDY TEST



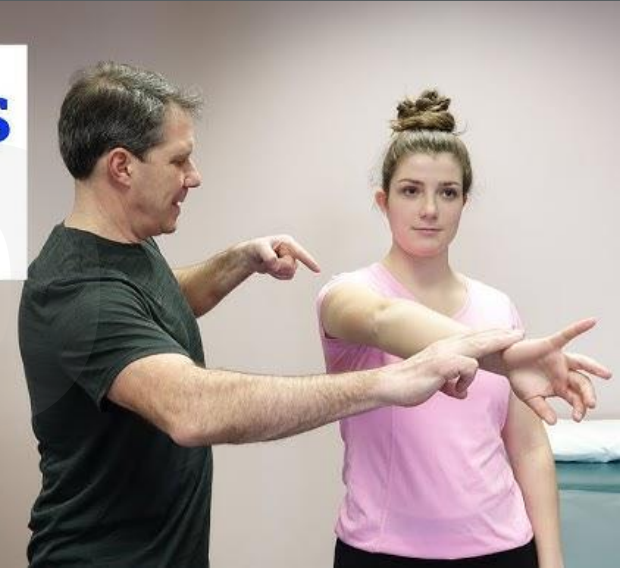So how do we evaluate these?

- Posterior
 - Infraspinatus (resisted ER)
 - Intraarticular (O'Brien's)



O'Brien's Test

Shoulder
Exam





Thank You