Croup Clinical Pathway

February 2021

Outcomes/Goals	**1.** Identification and treatment of pediatric patients with croup **2.** Create a team-oriented approach to treatment and care **3.** Identify and distinguish mild, moderate, and severe croup and prevent impending respiratory failure
NURSE Documentation	Chief complaint. Onset of symptoms, alleviating/contributing factors, appearance, lung sounds, work of breathing, retractions, pulses, and skin temperature/fever. Assess for possibility of airway foreign body.
INTERVENTIONS Initiate on arrival	Initiate isolation: Droplet and Contact Full set of vitals per standard of care Minimize noxious stimuli for moderate and severe croup (see algorithm) Determine severity of exacerbation (*Severity Assessment) Continuous pulse oximetry for moderate and severe croup, spot check SaO2 for mild croup Initiate oral Dexamethasone for mild and moderate severity Administer oxygen if cyanosis or SaO2 <93% present Give racemic epi for stridor at rest – Use mask for neb delivery if severe symptoms Alert LIP immediately for child who presents with stridor at rest *Mist therapy (saline nebs)* ***not*** *recommended for any severity category*
DIAGNOSTICS	May include: • Chest x-ray • Soft tissue neck x-ray
PHYSICIAN (LIP)	
Medication Steroids	Oral Dexamethasone 0.6 mg/kg (parenteral if not able to tolerate PO safely) *Use parenteral version orally to minimize volume *Maximum dose 16mg
Inhalation therapy (for stridor **at rest with distress**)	Nebulized racemic epinephrine 2.25% (0.5 ml in 2.5 ml Saline) • May repeat racemic epinephrine x 1. If 3rd dose needed reconsider differential and admit
Rehydration	Evaluate/encourage oral rehydration as appropriate for mild croup NPO for moderate/severe croup until symptoms improve
Radiology	Consider imaging to exclude alternate diagnoses for children who do not respond to treatment, present with high fever, or are without infectious symptoms.
Rescue Therapy	Consider Heliox (blend of oxygen-30% and helium-70%) for stridor refractory to racemic epinephrine.
ADMISSION	Consider admit if recurrent stridor after 2 hours observation and requires epinephrine x 2 Call pediatric ward or PICU attending Prepare family/infant for admission

***Severity Assessment**

Mild	Moderate	Severe	Impending Respiratory Failure
Occasional barky cough No audible stridor at rest No to mild suprasternal and/or intercostal retractions	Frequent barky cough Easily audible stridor at rest Suprasternal and sternal wall retraction at rest, but little or no distress or agitation	Frequent barky cough Prominent inspiratory and occasionally expiratory stridor Marked sternal retractions Significant distress and agitation	Change in mental status Fatigue Listlessness Agitation Pallor Dusky appearance Decreased retractions Decreased breath sounds with decreasing stridor

Clinical Pathway Decision Making Process: Croup

February 2021

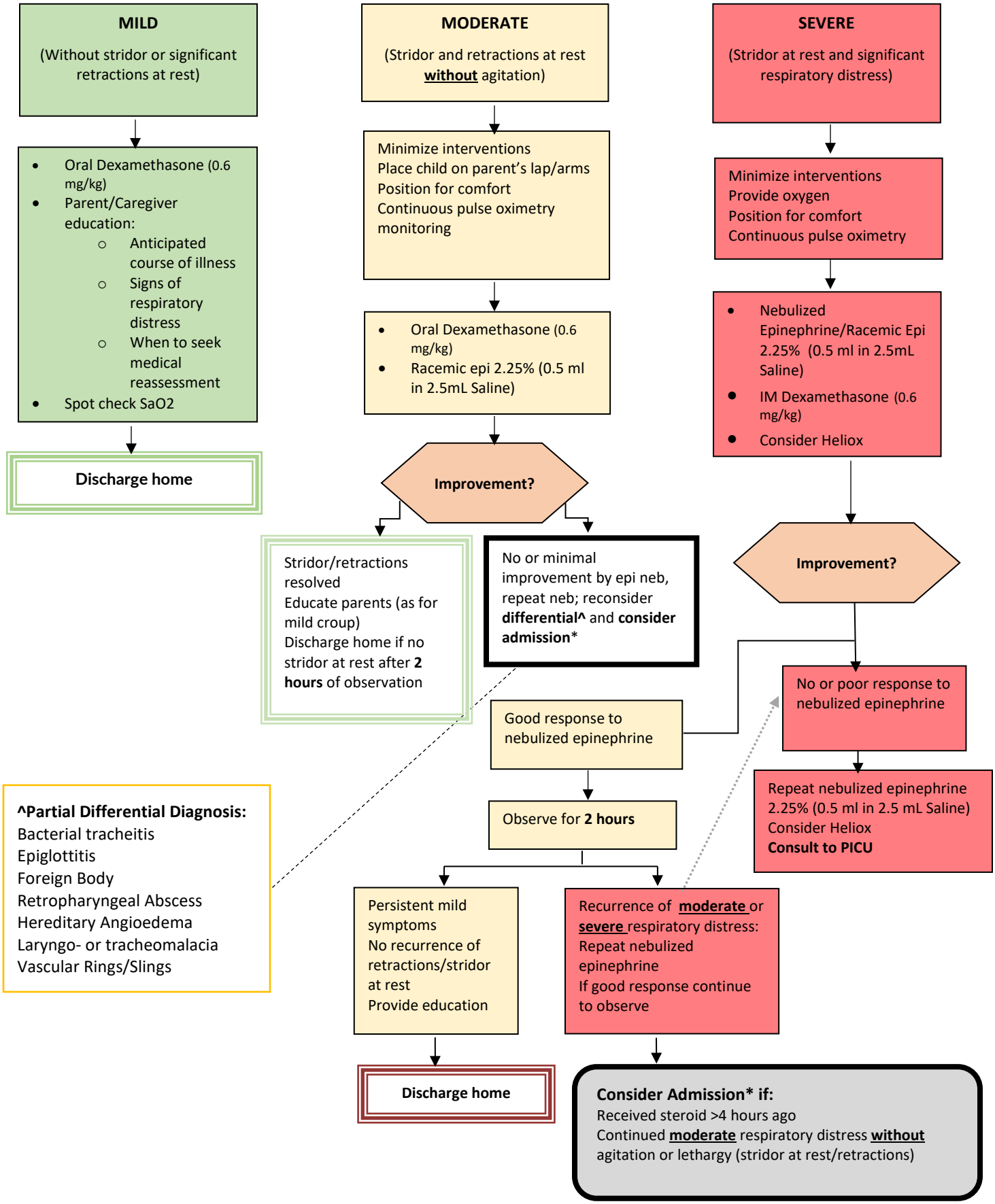

Croup Rationale and Data

Goals of Clinical Pathway

1. Identification and treatment of pediatric patients with croup
2. Create a team-oriented approach to treatment and care
3. Identify and distinguish mild, moderate and severe croup and prevent impending respiratory failure

Data Considerations	Interventions	Rationale
Steroids	Dexamethasone	Single dose oral dexamethasone is indicated in all children diagnosed to have croup including those with only a barky cough without any other signs of respiratory distress Dexamethasone may be administered orally to all but those children with very severe croup. It is rapidly absorbed with less than 5% of children vomiting the medication.
Diagnostics	Lab and radiology	Laboratory and radiological assessments are not necessary to make the diagnosis of croup. Reliable diagnosis can be made by clinical presentation in combination with a thorough history and physical exam. Viral cultures or rapid antigen tests do not aid in routine management of patients and add unnecessary and potentially counterproductive additional stimulus. Radiological assessment may be helpful for ruling out foreign body, bacterial tracheitis, or retropharyngeal abscess for moderate and severe symptoms that do not respond to treatment
Monitoring	Pulse Oximetry Observation	Pulse oximetry is indicated in children with moderate to severe croup. Continuous monitoring is not required in patients with mild croup. Children should not be discharged with less than 2 hours of observation following administration of epinephrine

Croup Severity Assessment

Mild	Moderate	Severe	Impending Respiratory Failure
• Occasional barky cough • No audible stridor at rest • No to mild suprasternal and/or intercostal retractions	• Frequent barky cough • Audible stridor at rest • Suprasternal and sternal wall retraction at rest • Little or no distress or agitation	• Frequent barky cough • Prominent inspiratory and occasionally expiratory stridor • Marked sternal retractions • Significant distress and agitation	• Change in mental status • Fatigue • Listlessness • Pallor • Dusky appearance • Decreased retractions • Decreased breath sounds with decreasing stridor

Citations:

Westley CR, Cotton EK, Brooks JG. Nebulized racemic epinephrine by IPPB for the treatment of croup: a double-blind study. Am J Dis Child 1978; 132:484

Gates A, Gates M, Vandermeer B, et al. Glucocorticoids for croup in children. Cochrane Database Syst Rev 2018; 8:CD001955.

Clarke M, Allaire J. An evidence-based approach to the evaluation and treatment of croup in children. Pediatric Emergency Medicine Practice 2012; 9:1.

Bjornson C, Russell K, Vandermeer B, et al. Nebulized epinephrine for croup in children. Cochrane Database Syst Rev 2013; CD006619.