An Unusual MI: Intricacies of Management for the Patient with Spontaneous Coronary Artery Dissection

U.S. Department of Veterans Affairs
Veterans Health Administration
VA Portland Health Care System

Harrison Sapper MD, Maedeh Khayyat Kholghi DO, Brian Davidson MD
VA Portland Health Care System, Portland, OR
Department of Medicine, Oregon Health & Science University, Portland, OR

OREGON HEALTH & SCIENCE UNIVERSITY

Introduction

- Spontaneous Coronary Artery Dissection (SCAD) is a condition defined by non-traumatic, non-iatrogenic dissection of the coronary artery wall not attributable to atherosclerosis.[1]
- This under recognized condition has important management distinctions when compared to atherosclerotic coronary artery disease

Case Description

- A 36-year-old G5P2 woman with a history of infertility requiring in vitro fertilization two years prior presented to the ED with sudden onset 10/10 substernal chest pain.
- Initial vital signs were normal. Physical exam revealed a young woman in distress, but was otherwise normal.
- Her initial workup was consistent with ST elevation MI.
- She received aspirin, clopidogrel, and intravenous heparin and nitroglycerin.
- Emergent angiography revealed spontaneous proximal dissection of obtuse marginal 1; balloon angioplasty was performed with restoration of flow in the inferior branch but not in the superior branch.
- Echocardiography revealed slightly reduced ejection fraction with regional wall motion abnormalities.
- On discharge she was continued on aspirin and metoprolol.
- She has chronic angina as an outpatient with improvement after undergoing cardiac rehabilitation.
- She was later found to have evidence of fibromuscular dysplasia involving the bilateral internal carotid arteries on outpatient screening.

Initial Data	
CBC / CMP	Unremarkable
Troponin I	Initially negative. Peaked at 121 ng/mL (normal < 0.8 ng/mL)
ECG	ST elevations in II, III, aVF, V5, V6 with reciprocal ST depressions

Risk Factors	
Hypertension history	No
Hyperlipidemia	No, LDL = 60
Diabetes	No, HgbA1c = 5.3
Tobacco use	No
Obesity	No (BMI = 28)
Family history of coronary artery disease	No
Exogenous hormone Use	Yes, prior in vitro fertilization
Multiparous	Yes, G5P2

Diagnostic Workup

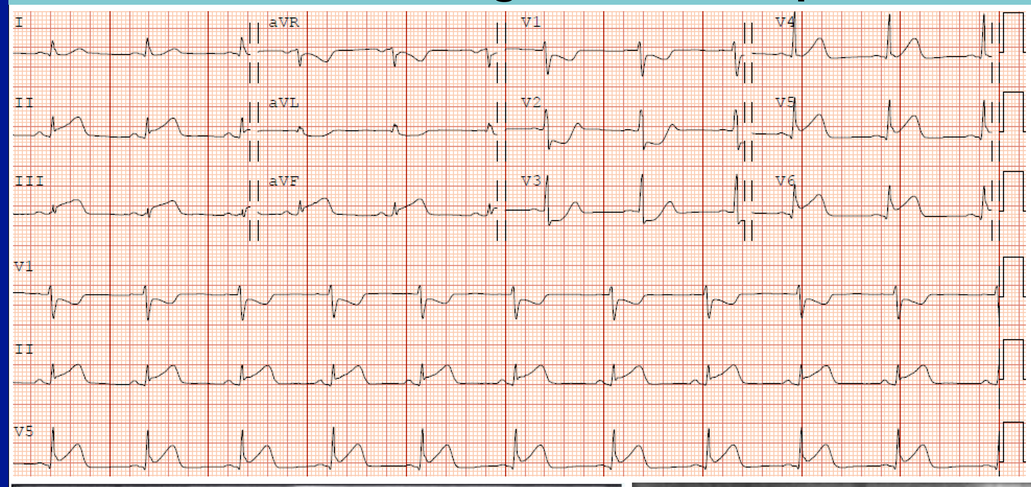

Figure 1: Initial ECG showing ST elevations in leads II, III, aVF, V5, and V6 with reciprocal ST depressions

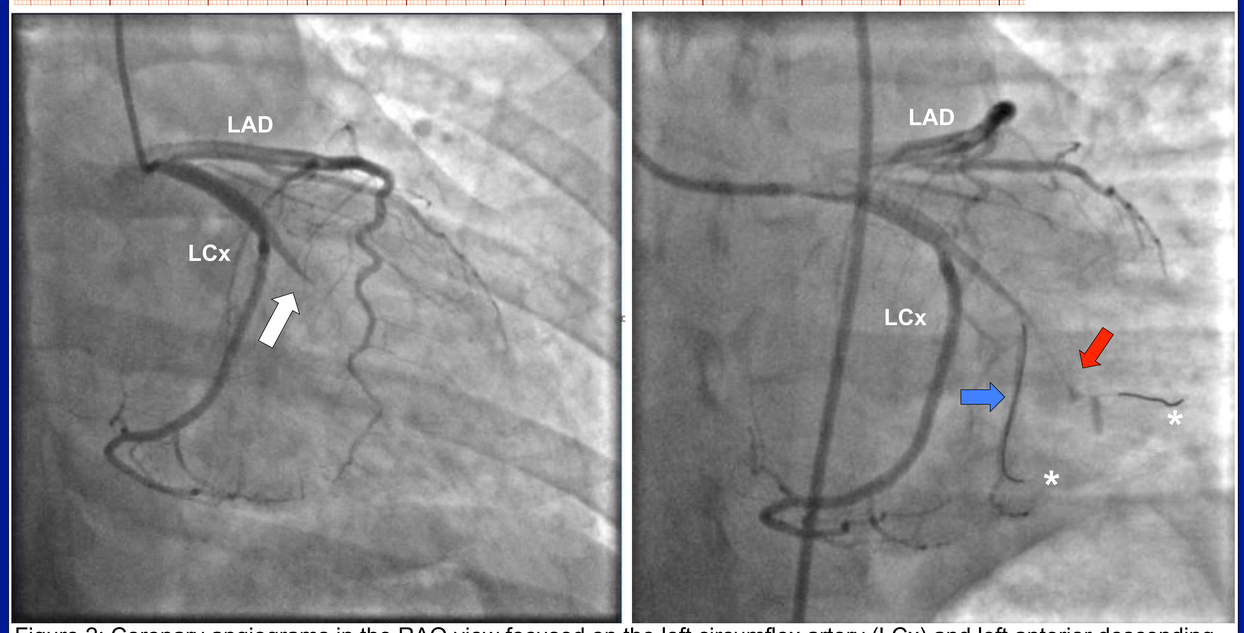

Figure 2: Coronary angiograms in the RAO view focused on the left circumflex artery (LCx) and left anterior descending artery (LAD). Left: angiogram showing occlusion (white arrow) in the proximal segment of the first obtuse marginal (OM1) branch. Right: angiogram during percutaneous coronary intervention (PCI) with coronary wires (asterisks) in both the superior (red arrow) and inferior (blue arrow) braches of OM1 demonstrating dissection of both branches without other angiographic stenosis.

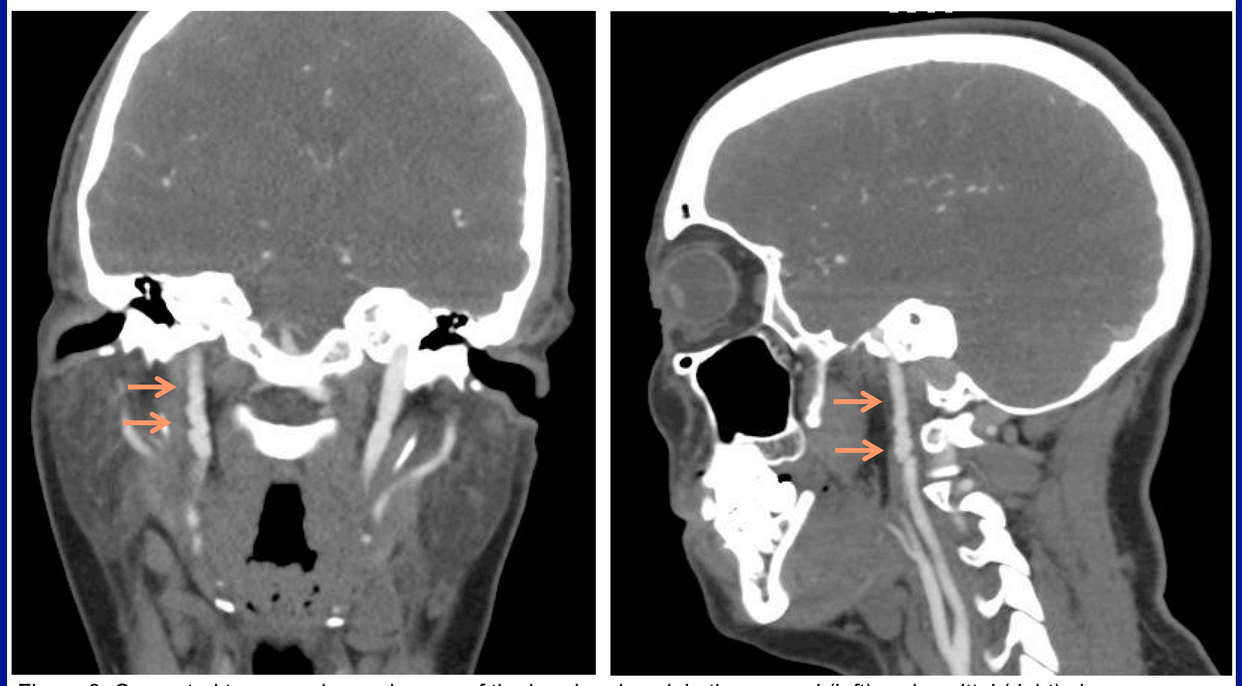

Figure 3: Computed tomography angiogram of the head and neck in the coronal (left) and sagittal (right) views demonstrating the beaded appearance of the cervical internal carotid arteries (arrows), consistent with fibromuscular dysplasia.

Discussion

- SCAD typically presents as acute coronary syndrome (ACS) in healthy young women.[1]
- The timely diagnosis of SCAD is important in patients with ACS because it alters management when compared to atherosclerotic disease.
- Definitive diagnosis of SCAD can be difficult but is typically made during angiography and can be facilitated with intracoronary imaging.
- Over 90% of cases occur in women. Amongst women less than 50 years old presenting with STEMI, the prevalence of SCAD is approximately 30%.[2]
- SCAD has been linked with multiparity and exposure to hormonal therapy.[2,3]
- Fibromuscular dysplasia is discovered in approximately 50% of patients with SCAD, and screening for FMD with further imaging is recommended.[2]
- Management of SCAD is largely based on observational data. A conservative approach is often favored since PCI carries a high rate of complications and most dissections heal spontaneously.[2]
- There is strongest evidence for beta-blockers and aspirin, but clopidogrel, ACE inhibitors, and statins are of unclear utility. Anticoagulation and thrombolytics may cause harm.[2]
- The estimated 10-year risk of future cardiac events is nearly 50%.[2]
- Patients should be counseled about high risk of future pregnancy and to avoid hormonal therapy.[2]
- Cardiac rehabilitation programs are associated with improved outcomes in SCAD, but patients should have lower target heart rates and blood pressures.[2]

Teaching Points

- **Maintain a high index of suspicion for SCAD in young women presenting with MI.**
- **Be aware of alterations in management of SCAD when compared to atherosclerotic coronary artery disease.**
- **Counsel patients about the high risk of future pregnancies and to avoid exogenous hormones.**
- **Ensure patients with a history of SCAD are screened for fibromuscular dysplasia.**

References

1. Hayes SN, Kim ESH, Saw J, et al. Spontaneous Coronary Artery Dissection: Current State of the Science: A Scientific Statement From the American Heart Association. Circulation. 2018;137(19):e523-e557.
2. Saw J, Mancini GBJ, Humphries KH. Contemporary Review on Spontaneous Coronary Artery Dissection. J Am Coll Cardiol. 2016;68(3):297-312.
3. Sharma S, Kaadan MI, Duran JM, et al. Risk Factors, Imaging Findings, and Sex Differences in Spontaneous Coronary Artery Dissection. Am J Cardiol. 2019;123(11): 1783-1787.