# Leptomeningeal carcinomatosis: a rare manifestation of metastatic prostate adenocarcinoma

Claire Groth MD, James Clements MD (Oregon Health and Science University)

## Introduction

Leptomeningeal carcinomatosis, malignant spread to the pia-arachnoid, is an exceedingly rare complication of prostate cancer, with some studies noting a prevalence of 1/3000 in this malignancy.[1] It is more common in breast cancer (5%), small cell lung cancer (9-25%), and melanoma (23%).[2] While uncommon, the incidence is expected to increase as novel therapies prolong life for those living with prostate cancer and early treatment may provide some stability to its clinical sequelae.

## Case Description

A 68-year-old gentleman with **prostate adenocarcinoma** complicated by pelvic sidewall metastases treated with a non-nerve-sparing radical prostatectomy and chemotherapy presented after an episode of transient diplopia with subacute dysphagia and dysarthria in the setting of chronic gait instability and lower extremity pain progressive over several months.

His disease had been stable however **a new PSA rise** prior to presentation raised concern for progression.

**Exam:** systolic hypertension, severe dysarthria, tongue fasciculations, patchy loss of pinprick sensation below his knees, and absent patellar and Achilles reflexes bilaterally.

**Total spine MRI** (see figure 2): extensive nodular leptomeningeal enhancement, including of the spinal nerve roots, concerning for leptomeningeal disease.

**Brain MRI:** avid enhancement of the cerebellar folia, also suspicious for a leptomeningeal process (see figure 3). Oncology consulted and recommended lumbar puncture yielding the results shown in the "CSF Studies" section.

## CSF Studies

| |
|---|
| Glucose: 17 |
| Protein: 382 |
| WBC: 32 |
| Diff: 12% atypical cells |
| Flow cytometry: atypical cells, non-hematopoietic in origin |
| PSA staining: + |
| Prostatic Acid Phosphatase: + |

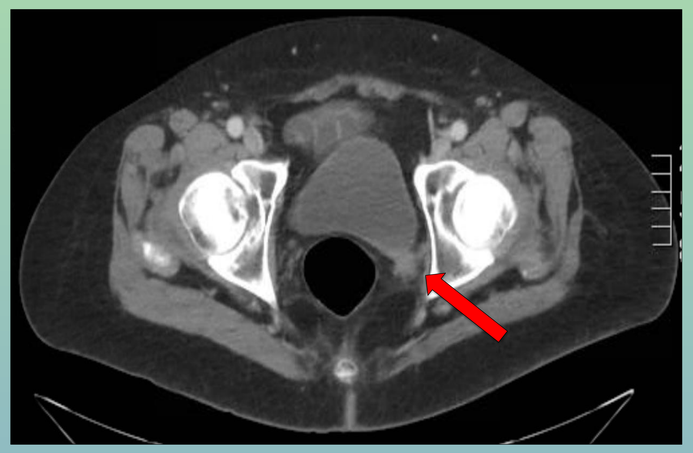

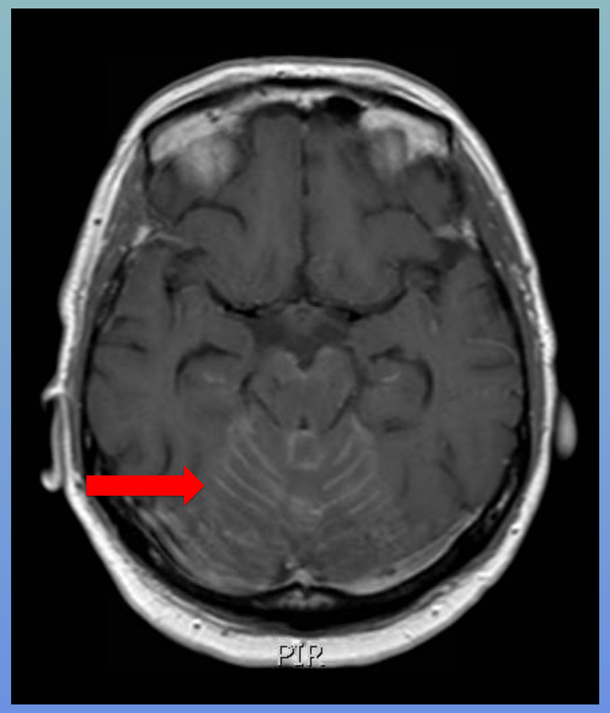


Figure 1 (above): CT AP showing pelvic sidewall mass (prostate cancer involvement) unchanged from prior.

Figure 2 (below): MRI cervical spine showing leptomeningeal enhancement.

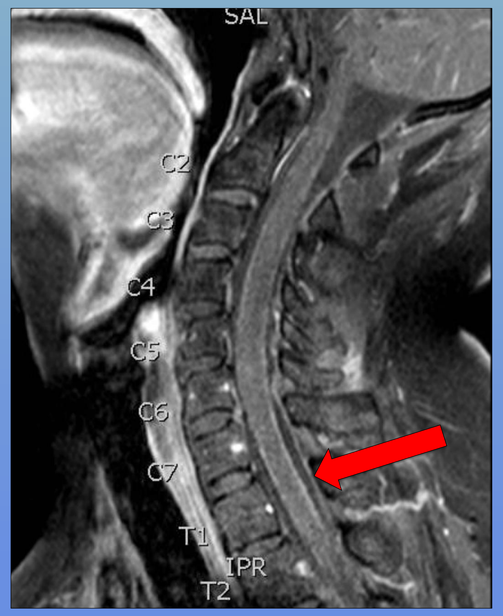


Figure 3 (above): MRI brain with contrast showing enhancement of the cerebellar folia.

## Case Continued

- Positive staining of the CSF atypical cells for PSA and Prostatic Acid Phosphatase (PSAP) supported the diagnosis of prostate adenocarcinoma metastatic to the CNS.
- Diagnosed with leptomeningeal carcinomatosis, prostate primary.
- Intrathecal methotrexate infusions and oral dexamethasone initiated.
- Eventually chose hospice care and died two months after diagnosis.

## Discussion

- The most common clinical manifestations of leptomeningeal carcinomatosis, as seen in our patient, are cranial nerve deficits.[2]
- Frequently affected CNS regions include the posterior fossa where areas of slow CSF flow and gravity facilitate deposition of circulating malignant cells.[2]
- While the pathogenesis in prostate cancer is debated, one theory is metastasis through the venous drainage system via the lower paravertebral plexus with subsequent proximal CNS spread.[3]
- Diagnosis is made with a combination of clinical, MRI and lumbar puncture findings including PSA/PSAP staining.
- Despite the poor prognosis of the disease, it is important to recognize as early intrathecal chemotherapy may stabilize neurologic symptoms.[4]

## References

1. Tremont-Lukats, Ivo W., et al. "Brain Metastasis from Prostate Carcinoma." Cancer, vol. 98, no. 2, 2003, pp. 363–368., doi:10.1002/cncr.11522.
2. Grossman, Stuart A., and Michael J. Krabak. "Leptomeningeal Carcinomatosis." Cancer Treatment Reviews, vol. 25, no. 2, 1999, pp. 103–119., doi:10.1053/ctrv.1999.0119.
3. Cone, Lawrence A., et al. "Leptomeningeal Carcinomatosis in a Patient with Metastatic Prostate Cancer: Case Report and Literature Review." Surgical Neurology, vol. 65, no. 4, 2006, pp. 372–375., doi:10.1016/j.surneu.2005.08.026.
4. Kokkoris, Christos P. "Leptomeningeal Carcinomatosis: How Does Cancer Reach the Pia-Arachnoid?" Cancer, vol. 51, no. 1, 1983, pp. 154–160., doi:10.1002/1097-0142(19830101)51:13.0.co;2-k.