

Way Off From Korsakoff: A Case of Confabulation due to Anterior Communicating Artery Aneurysm Rupture

Carlton Scharman, MD, Wendy Tseng, MD, MS, Avital O'Glasser, MD, FACP
Department of Medicine, Oregon Health & Science University, Portland, OR

LEARNING OBJECTIVES

1. To better understand the definition of confabulation, its underlying pathophysiology, and its differential diagnosis
2. To recognize anterior communicating artery aneurysm rupture as a cause of confabulation

INTRODUCTION

Although many definitions exist, confabulation can be described as the compensation for memory loss by the verbal production of erroneous and fabricated material without the desire to mislead. Although confabulation is classically associated with Wernicke-Korsakoff syndrome, the differential diagnosis is much wider than one may expect. This is case of confabulation as a sequela of a ruptured anterior communicating artery (ACoA) aneurysm.

CASE PRESENTATION

- A 74-year-old woman presented with two months of confusion and confabulation in the setting of a recent subarachnoid hemorrhage (SAH) from an ACoA aneurysmal rupture that required clipping (see figure 1).
- Her SAH was complicated by post-hemorrhagic hydrocephalus requiring ventriculoperitoneal shunt.
- Since her aneurysm rupture, her family noticed that she began to fabricate stories and eventually began to occasionally act on these fabrications.
- Her neurological exam showed fluent but tangential speech, disorientation to time and place, no nystagmus or ataxia, and confabulation, in which she provided unprovoked recent anecdotes of recent events that family denied were true.
- She also had a positive "string sign", in which she elaborated on a string that the examiner was pretending to hold and stretch.
- Otherwise vitals, remainder of exam, and laboratory work-up, including CSF studies, were unremarkable. Head CT showed no ventriculomegaly or other acute intracranial abnormalities.
- Neurosurgery was consulted who confirmed her ventriculoperitoneal shunt was functioning properly and had low suspicion for shunt infection.
- Despite no history of alcohol use, she was empirically treated with thiamine, but this caused no significant improvement.
- Further review of literature by her treatment team revealed that ACoA rupture can cause similar behavioral and cognitive changes known as "ACoA syndrome."
- Given the negative work-up and the temporal correlation with her SAH, her presentation was deemed most likely from ACoA syndrome, and the patient was discharged home with plan for cognitive rehabilitation.

WHAT IS CONFABULATION?

"The compensation for memory loss by the verbal production of erroneous and fabricated material without the desire to mislead"

-Fotopoulou et al¹

OUR PATIENT

Patient: "I went to the Oregon Coast today and we sat by the beach."

(She also packed bags this AM for the trip)

Family: "We stayed at home today."

~~~~~

**Patient:** "I had breast cancer and had chemotherapy at age 40."

**Family:** "Her mother died of breast cancer at age 40. She has never had breast cancer."

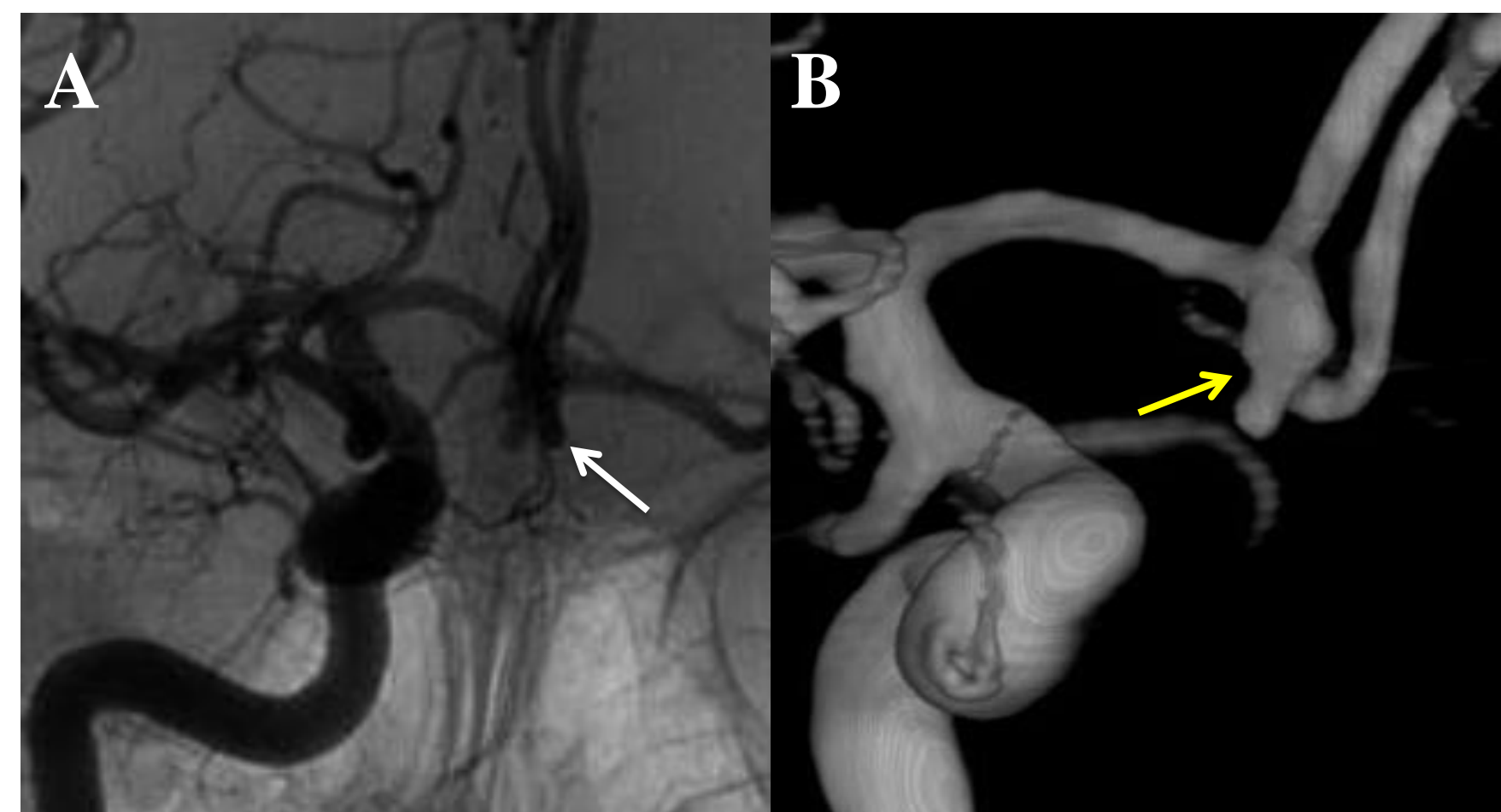
~~~~~

Patient: "I have an infant grandson."

Family: "He is actually 17 years old, and she has been wandering the house at night looking for him."

~~~~~

**Family:** "She has been setting up the home for dinner parties that are not even planned."



**Figure 1: Cerebral angiogram findings.** A) Right internal carotid arteriogram showing a 5 x 4 mm inferiorly-projecting lobulated irregular anterior communicating aneurysm (white arrow). B) 3-dimensional reconstruction of right internal carotid arteriogram showing the same anterior communicating artery aneurysm (yellow arrow)

| System      | Pathology                                                                                        |
|-------------|--------------------------------------------------------------------------------------------------|
| Psychiatric | Schizophrenia                                                                                    |
| Dementia    | Frontotemporal dementia<br>Alzheimer's dementia                                                  |
| Metabolic   | Thiamine deficiency (eg, Korsakoff syndrome)<br>Nicotinic acid deficiency                        |
| Infectious  | Neurosyphilis<br>Herpes encephalitis                                                             |
| Structural  | ACoA aneurysm rupture<br>Normal pressure hydrocephalus<br>Traumatic brain injury<br>Brain tumors |
| Other       | Cardiopulmonary arrest<br>Multiple sclerosis                                                     |

Table 1: Pathologies associated with confabulations<sup>2</sup>

| Classification type    | Subtype                                 |
|------------------------|-----------------------------------------|
| How they arise         | Provoked<br>Spontaneous                 |
| Content                | Simple<br>Fantastic<br>Momentary        |
| Memory domain affected | Auto-biographic<br>Episodic<br>Semantic |

Table 2: Various proposed confabulation classification schemes<sup>3</sup>

## DISCUSSION

- Although classically seen with Wernicke-Korsakoff syndrome, confabulations are associated with a wide spectrum of etiologies (see table 1)<sup>2</sup>.
- Various classification schemes have been proposed (see table 2)<sup>3</sup>. In contrast to "provoked" confabulations (in which they occur only in the context of being questioned), this patient had "spontaneous" confabulations, which are most associated with being acted upon as this patient had done.
- Confabulation is most often associated with damage to the frontal lobe and anterior limbic system<sup>4</sup>. It frequently occurs in combination with both amnesia and executive function deficits.
- Confabulation has classically been attributed to "gap-filling" in memory, but more recently hypothesized as due to deficits in processing of temporal information and "strategic memory retrieval"<sup>5</sup>.
- ACoA syndrome composes of a triad of memory loss, confabulation (mostly "spontaneous", as this patient had), and altered personality, such as disinhibition. These changes are thought to be from ischemic damage to the frontal lobe.
- In a 1968 prospective study, ACoA syndrome occurred in 23% (18/79) of survivors of ACoA aneurysm rupture<sup>6</sup>.
- Cognitive deficits can persist for years after SAH. Treatment involves neuropsychological rehabilitation, caregiver coping strategies, and community integration.

## REFERENCES

- 1) Fotopoulou A.; Conway M. A.; Solms M. (2007). "Confabulation: Motivated reality monitoring". *Neuropsychologia*. 45 (10): 2180-2190.
- 2) Glowinski R, Payman V, Frencham K. Confabulation: a spontaneous and fantastic review. *Aust N Z J Psychiatry*. 2008;42(11):932-40.
- 3) Lorente-rovira E, Berrios G, Mckenna P, Moro-ipola M, Villagrán-moreno JM. Confabulations (I): concept, classification and neuropathology. *Actas Esp Psiquiatr*. 2011;39(4):251-9.
- 4) Gilboa A, Verfaellie M. Telling it like it isn't: the cognitive neuroscience of confabulation. *J Int Neuropsychol Soc*. 2010;16(6):961-6.
- 5) Ruggeri M, Sabatini U. Recovery from amnesic confabulatory syndrome after right fornix lesion. *Neurorehabil Neural Repair*. 2008;22(4):404-9.
- 6) Logue V, Durward M, Pratt RT, Piercy M, Nixon WL. The quality of survival after rupture of an anterior cerebral aneurysm. *Br J Psychiatry*. 1968;114(507):137-60.