



Cobal-ing Together a Diagnosis An Unexpected Cause of Hemolytic Anemia

Kevin Ducey, MD, Alan J. Hunter, MD, FACP

Oregon Health & Science University

Case Description

A 74-year-old man with hypertension presented with altered sensorium four days following a gastrointestinal flu-like illness., followed by syncope and visual hallucinations.

Exam:

- T 38.8 °C, HR 110s, BP 114/37, SpO2 80%
- Conjunctival pallor, pale skin
- Lethargic, oriented to self only, no focal neurologic findings
- Cardiac, pulmonary, abdominal exams unremarkable

Labs:

- Hgb 5.9 g/dL, MCV 115.3 fl
- Plt 77 (K/mm³)
- WBC 4.7 K/mm³, 80% neutrophils
- Cr 2.06 mg/dL, otherwise normal CMP
- Haptoglobin <14 mg/dL
- LDH 1724 IU/L

Blood smear: “target cells noted, dysmorphic red blood cells, poikilocytosis, 1+ schistocytes with helmet cells noted, atypical cells <2% also noted”

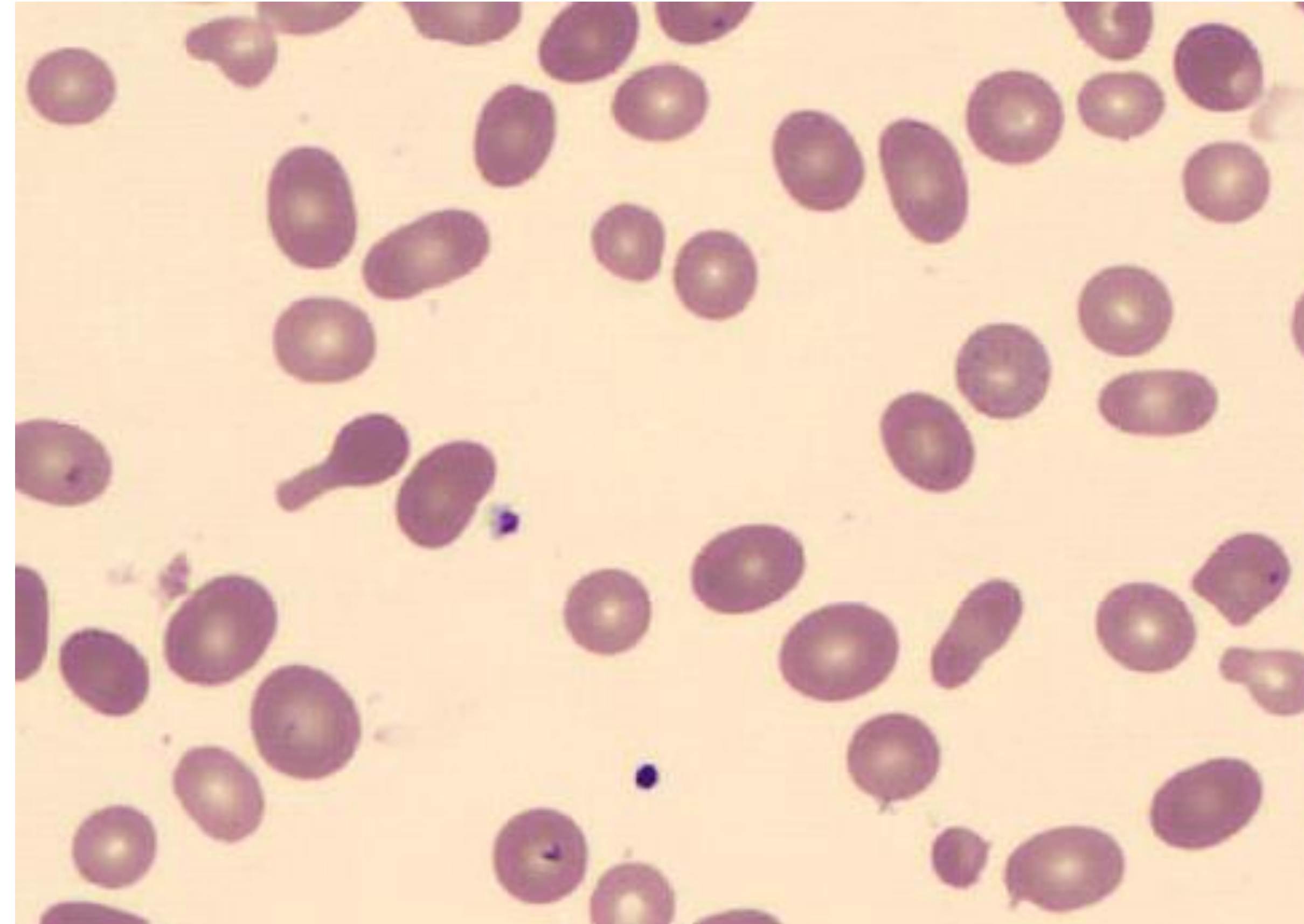
Presumptive diagnosis of TTP made, treated with high dose steroids and plasma exchange without improvement in anemia or thrombocytopenia

Bone marrow biopsy: hypercellularity

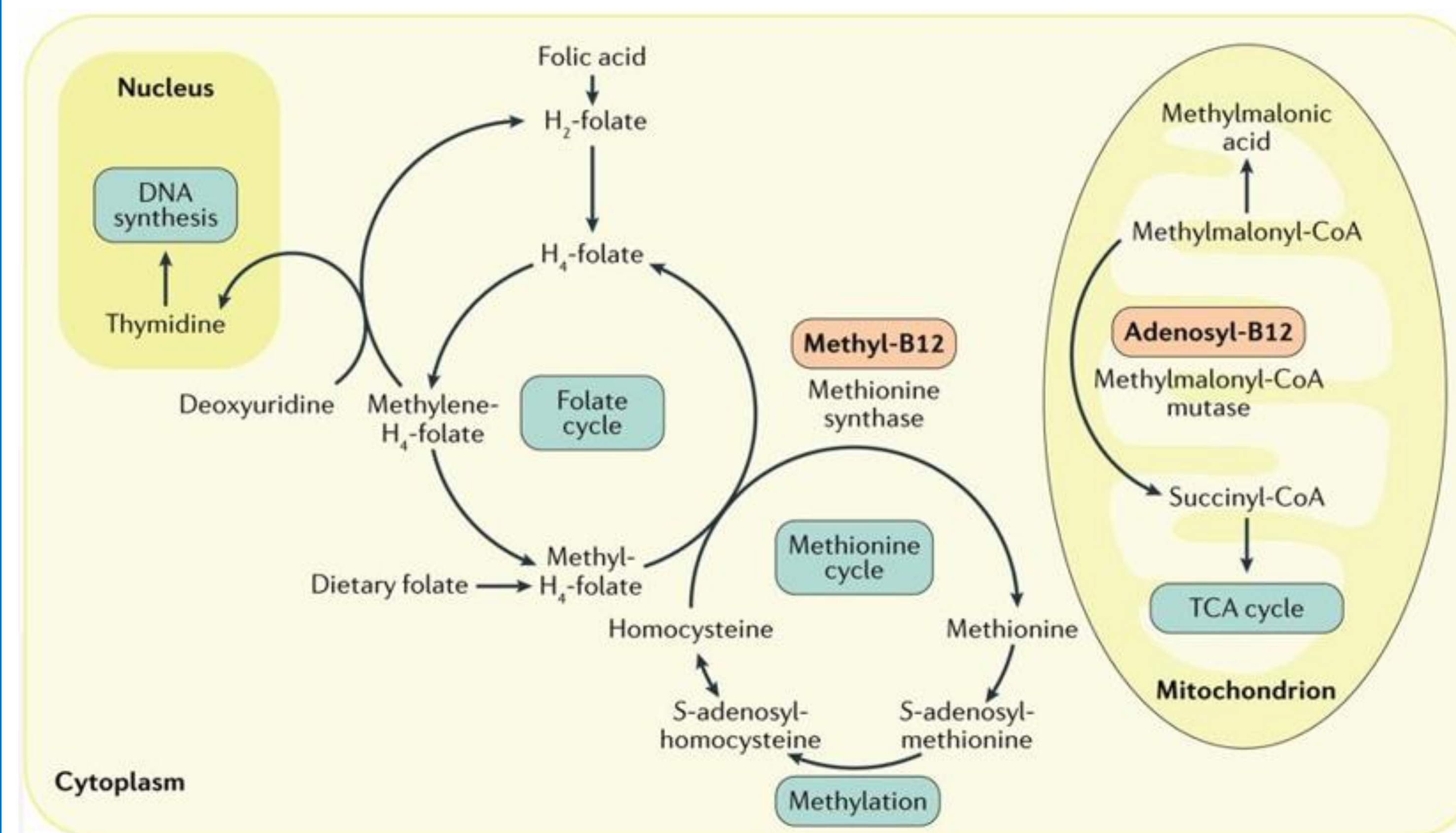
Additional studies:

- Normal ADAMTS13 activity
- Negative Direct Coombs test
- Homocysteine 99.3 (H)
- Methylmalonic acid 13 (H)

Diagnosis of vitamin B12 deficiency made. Patient was treated with high dose B12 injections with stabilization of his anemia and thrombocytopenia and return to baseline mental status. An exhaustive search was unable to determine the cause of his B12 deficiency.



Patient's peripheral blood smear showing target cells, poikilocytosis, 1+ schistocytes with helmet cells



Role of vitamin B12 in DNA synthesis and energy production

Teaching Points

- Morbidity is high with TTP, thus early initiation of definitive therapy is warranted when there is a high index of suspicion
- There are myriad causes of hemolytic anemia and suspicion for a vitamin B12 deficiency should be raised in the right clinical settings or if the patient fails to respond to initial therapy.
- Further studies into the pathophysiology of hemolytic anemia secondary to vitamin B12 deficiency should be conducted.

References

- Stabler SP (2013) Clinical practice. Vitamin B12 deficiency. *N Engl J Med* 368:149-160.
- N Sethi, E Robilotti, Y Sadan. *Neurological Manifestations Of Vitamin B-12 Deficiency*. The Internet Journal of Nutrition and Wellness. 2004 Volume 2 Number 1.
- Andres E, et al. Current hematological findings in cobalamin deficiency. A study of 201 consecutive patients with documented cobalamin deficiency *Clin Lab Hematology*. 2006 Feb;28(1):50-6.
- Alperin JB. Hematology: Basic Principles and Practice, 2nd ed. *Texas Heart Institute Journal*. 1995;22(2):206-207.
- Routh, J, Koenig, S. Severe vitamin B12 deficiency mimicking thrombotic thrombocytopenic purpura. *Blood*. 2014; 124:1844
- Green, R., et al. Vitamin B₁₂ deficiency. *Nature Reviews Disease Primers*, 3. Article 17040. 29 June 2017.

Discussion

B12 serves as a cofactor in the conversion of homocysteine into methionine, a vital amino acid allowing for purine and pyrimidine synthesis, DNA methylation, and myelin production

B12 is also a cofactor for methylmalonyl-CoA mutase, an enzyme that converts methylmalonyl-CoA to succinyl-CoA which then enters the TCA cycle

Deficiency leads to decreased cell division which manifests classically with peripheral blood smear findings of megaloblastic erythrocytes and neutrophils

Clinically, this presents as a macrocytic anemia and neuropsychiatric symptoms such as peripheral neuropathy or cognitive changes.

Deficiency takes up to 5-10 years to develop due to large stores of B12 in the adult liver and is generally caused by decreased gastrointestinal absorption in conditions such as pernicious anemia or prior ileal resections, long term antacid use, or decreased intake.

1.5% of B12 deficiency patients present with findings of a hemolytic anemia. The exact mechanism is not well understood, but has been demonstrated that elevated homocysteine levels cause intramedullary hemolysis, likely due to the pro-oxidative qualities of homocysteine while other in vitro studies demonstrated endothelial damage and thrombosis in association with elevated homocysteine levels, positing an additional intravascular component to the hemolysis.

Other mechanisms of hemolysis in the setting of B12 deficiency include an occult autoimmune hemolytic anemia, a chronic hemolytic condition leading to B12 deficiency, or a hyperproliferative process increasing the consumption of vitamin B12.