

Upcoming Technology for Aortic Arch Aneurysms

Devices on the horizon that will allow near-total endovascular techniques to become a reality.

BY CHERRIE Z. ABRAHAM, MD, AND VICTOR M. RODRIGUEZ, MD

Despite major advances in complex aortic arch reconstruction, these challenging procedures are still fraught with significant problems such as bleeding; cardiac, pulmonary, and renal complications; and stroke. Conventional surgical repair of aortic arch pathology is an invasive procedure often necessitating cardiopulmonary bypass and deep hypothermic circulatory arrest. Although there has been progress made in surgical technique, anesthesia, and intensive care management, total arch replacement still carries a perioperative mortality or stroke rate approaching 10% to 15%, even in major referral centers.¹ The operative risk is even more elevated in elderly patients, patients requiring emergency repair, and in those with major preexisting comorbidities. As a result, many patients are deemed unsuitable for open repair. Recently, repair in these patients with aortic arch aneurysms has been accomplished using both hybrid (endovascular combined with open techniques)² and “near-total” endovascular techniques.^{3,4}

HYBRID REPAIR

In hybrid repair, supra-aortic debranching is performed to provide an appropriate landing zone for the stent graft and to preserve perfusion to the supra-aortic trunks followed by stent graft deployment into zone 0 to 2 of the ascending and transverse aortic arch. Hybrid procedures thus avoid the need for cardiopulmonary bypass or hypothermic circulatory arrest. Modifications in existing technology and new-generation devices, such as the Conformable Gore TAG thoracic endoprosthesis (Gore & Associates), Valiant thoracic stent graft (Medtronic), Relay thoracic device (Bolton Medical), and Zenith Alpha thoracic endovascular graft (Cook Medical), have resulted in more reliable trackability and precise deployment at the distal margin of the innominate, left common carotid, and left subclavian arteries (LSA), or in the ascending aorta.

CHIMNEY OR SNORKEL GRAFTS

Chimney or snorkel grafts continue to be used in the thoracoabdominal aorta for endovascular treatment of complex thoracic and abdominal aortic aneurysms,⁵ despite some reported concerns.⁶ Chimney grafts have even been proposed to extend the proximal fixation zone in the aortic arch during thoracic endovascular aortic repair (TEVAR). They have the advantage of using standard, off-the-shelf materials and being technically less demanding, but their durability and ability to effect exclusion of an aneurysm in the aortic arch remains dubious, despite reported success.⁷ Thoracic stent graft technology is not being developed with chimney and snorkel grafts in mind, and consequently, there is presently no ideal graft for this application. Until more patients and longer follow-up are available, chimney grafts should only be considered in emergency patients who are poor candidates for open repair or in cases of preoperative inadvertent coverage of the supra-aortic trunks.

ANATOMIC CHALLENGES

The aortic arch anatomy presents complex spatial geometry with curvatures and three-dimensional angulations that are quite extreme at times, challenging the apposition and long-term integrity of endovascular devices. Inadequate apposition or conformability of the endograft in the inner curve of the aortic arch may cause difficulty with proximal seal and fixation, resulting in perioperative or postoperative type I endoleaks. After placement, stent grafts in the aortic arch are subject to great dynamic strain, owing to a curved configuration, high blood flow, and pulsatile movement of the aorta, which may cause migration, fractures, or disconnection of the device components.

Exclusion of the aneurysm sac, maintenance of cerebral perfusion, and avoidance of emboli are the primary intraoperative objectives in endovascular aortic arch repair. Important supra-aortic vessels, such as the carotid

and vertebral arteries or coronary bypasses arising from the internal mammary artery, must remain perfused. In addition, excessive manipulation of catheters, wires, and intravascular devices should be avoided within the confines of the aortic arch to avoid cerebral embolization with subsequent stroke or vessel wall injury, which could result in thrombus formation and dissection. These issues are particularly important for the new generation of side branch prostheses.

DEVICES ON THE HORIZON

The following device descriptions are not intended to be an all-inclusive list, and more competition is on the way. In addition to the devices described in the following sections, the Nexus aortic arch system (Endospan), based on a novel approach, has seen successful implants worldwide, and will no doubt be tested in feasibility trials in the near future. We welcome competition in this space in order to drive industry to continue to improve on their current generation of devices. None of the devices described in this article are currently approved for commercialization. Most are currently either in early feasibility trials with the US Food and Drug Administration (FDA) or are available by special access in other regions in the world. Their safety and efficacy have not yet been demonstrated. However, they represent what may soon be available to endovascular specialists throughout the world in the near future.

There appears to be general consensus that every effort should be made to revascularize the LSA when TEVAR necessitates covering the ostium of this vessel.⁸ Novel techniques have been reported to accomplish revascularization without performing extra-anatomic bypass, such as in situ fenestration techniques.^{9,10} However, data demonstrating efficacy are sparse and limited to case reports and series. The Conformable Gore TAG thoracic branch endoprosthesis (Gore & Associates) and the Valiant Mona LSA thoracic stent graft system (Medtronic) have been designed to treat proximal thoracic aneurysm pathology and circumvent the need to revascularize the LSA with a separate extra-anatomic bypass. Carotid-subclavian bypass is often technically demanding, especially in anatomically difficult patients, and therefore, endovascular surgeons will readily welcome this innovative technology. If results prove promising, it is conceivable that this same technology could be used in the future to treat more proximal arch aneurysms.

Conformable Gore TAG Thoracic Endoprostheses

The Conformable Gore TAG thoracic endoprosthesis (Gore & Associates) is the newest-generation thoracic device. It has the same characteristics of the TAG device with some design modifications that allow an increased

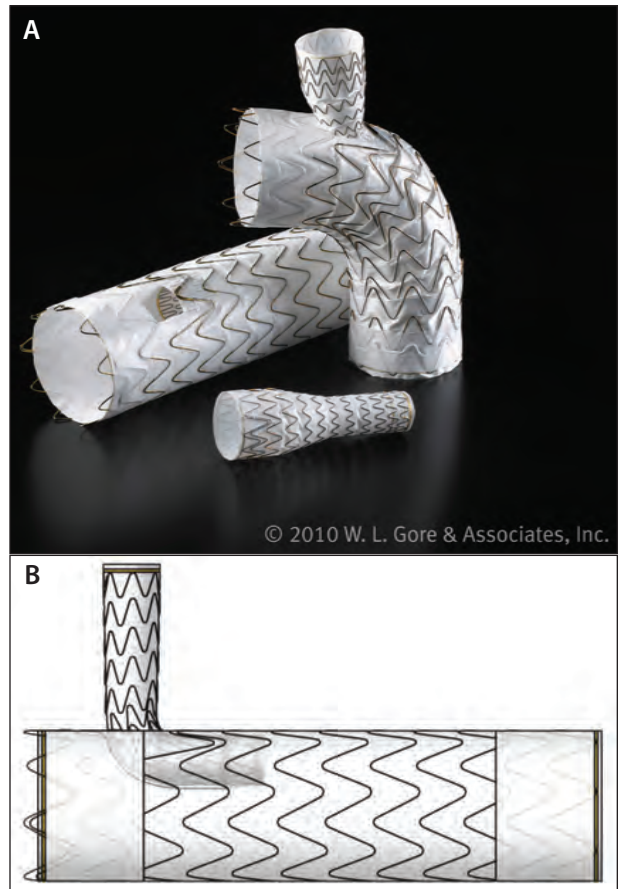


Figure 1. The Gore TAG thoracic branch endoprosthesis aortic component and side branch (A). Schematic of the Gore TAG thoracic branch endoprosthesis (B).

resistance to compression and conformability in an acutely angulated structure, such as the distal aortic arch. The Conformable Gore TAG thoracic endoprosthesis is a flexible, self-expanding endoprosthesis that is constrained on the leading end of a delivery catheter. It is composed of an expanded polytetrafluoroethylene tube that is reinforced with an expanded polytetrafluoroethylene/fluorinated ethylene propylene film and an external self-expanding supporting structure made of nitinol wire.

A new device system called the Gore TAG thoracic branch endoprosthesis has been designed based on the C-TAG platform (Figure 1). This device is composed of three components: the aortic component, side branch component, and aortic extender. The aortic component resembles the Conformable Gore TAG device with the addition of an internal docking portal. The aortic component is delivered over the aortic wire and side branch wire, which is precannulated through the portal. After deployment of the aortic component, the side branch introducer sheath is advanced through the portal into

Courtesy of Gore & Associates, Inc.

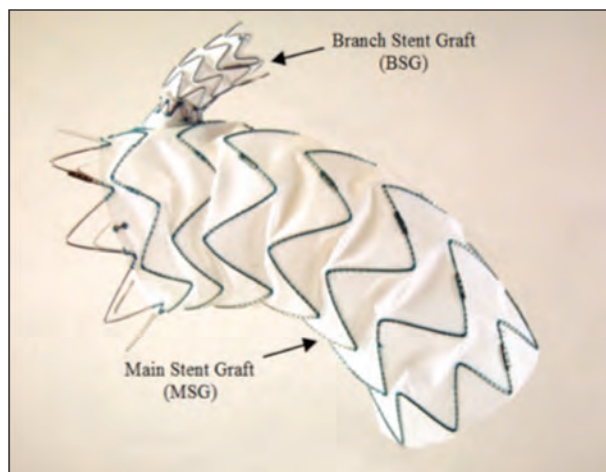
the side branch for delivery of the side branch device. After deployment of the side branch device, ballooning of the aortic component and side branch device can be performed. If additional proximal seal is required, the aortic extender may be used. The entire procedure may be performed through a single access site with retrograde flow into the side branch component. The Gore TAG thoracic branch endoprosthesis is currently not available, and its release is awaiting the results of two clinical trials and FDA approval in the United States.

Valiant Thoracic Stent Grafts

The Valiant Captivia system (Medtronic) is currently approved for all lesions of the descending thoracic aorta. Based on this reliable platform, the Valiant Mona LSA stent graft system (Figure 2) was developed to provide physicians with an endovascular option to revascularize the left subclavian artery, precluding the need for an extra-anatomic left subclavian revascularization during TEVAR of the distal aortic arch. Intended to be an off-the-shelf stent graft, it has an integrated single side branch in the form of a flexible external cuff, sometimes referred to as a “volcano.” The proximal main body of the thoracic stent graft maintains the uncovered, eight-peak stent design, equivalent to the Valiant Captivia system with proximal FreeFlo configuration (Medtronic). However, the two proximal covered stents have been modified to accommodate the flexible external cuff, which will become the lead point of contact and seal for the mating LSA branch stent graft component. Distal to the modified proximal stents, the main body stent graft has construction equivalent to the Valiant thoracic stent graft.

The delivery system for the main stent graft has a dual-wire design with the main stiff wire supporting the main stent graft and a second wire (most often a hydrophilic steerable wire) introduced through the second lumen, with both wires cleverly designed to exit a modified proximal nose cone. The second wire is precannulated through the external cuff. Left brachial access is used to snare the hydrophilic wire exiting the second lumen and a through-and-through wire is achieved, thus providing an accurate frame of reference for main stent graft positioning. The main stent graft is then deployed up to the level of the left common carotid artery, while the cuff engages the ostium of the LSA. After full deployment and release of the tip-capture mechanism, the delivery system is resheathed after recapture of the tip and then removed.

The LSA branch stent graft is advanced in an antegrade fashion over the second wire and deployed with the proximal portion inside of the branch cuff. The cuff is easily visualized on fluoroscopy, enabling precise positioning and guiding appropriate overlap with the mating branch stent



Courtesy of Medtronic

Figure 2. The Valiant Mona LSA thoracic branch stent graft system.

graft. A self-expanding stent at the distal end of the cuff effects seal, as well as fixation, of the bridging stent.

The mating branch stent graft is a new product that consists of a helical wireform nitinol stent design and polyester graft material that integrates well with this system and is delivered from a femoral approach through a modification of the Captivia delivery system. The graft itself is flared proximally to assist with seal. Results of the early feasibility study under the FDA’s Innovation Pathway, which is examining safety and efficacy, are eagerly awaited. In other global regions, this new technology may be available under special access and/or humanitarian use.

These side branch devices, if commercially approved for aneurysm treatment, may well become the preferred technique for dealing with blunt aortic trauma and symptomatic type B aortic dissection, as both pathologies require decision making in terms of what to do with respect to covering the subclavian artery.

Relay Stent Grafts

Bolton Medical has developed thoracic branch technology based on its Relay Plus platform to address the unmet needs in the endovascular treatment of aortic arch aneurysms. This device is meant to be an off-the-shelf device, and its intended use is to safely deliver the arch graft into a proximal landing zone in the ascending aorta (zone 0). Key features of the graft center around its patented proximal capture technology, improved arch conformation, prevention of retroflex deployment, pre-curved nitinol guidewire lumen, and dual-sheath design that facilitates advancement into zone 0.

The Relay NBS Plus technology allows expansion and apposition of the most proximal covered stent to take

place and prevent possible bird-beaking from occurring. The delivery system clasps onto two partially unsewn stent apices that are located on the proximal and superior aspect of the stent graft. This proximal clasping not only provides controlled deployment, but also a unique opportunity to theoretically reposition the graft once it is partially expanded, facilitating precise deployment. Retroflexion or inversion of the medial proximal stent during deployment can occur in some instances, especially in the absence of rapid pacing. These potential catastrophes may be averted with this arch system's use of support wires, which are tethered to the inferior aspect of the stent graft. These support wires guide the inferior aspect of the graft to conform to the inner curvature of the aorta. Consequently, the proximal covered stent is permitted to appose the aorta first while maintaining a controlled deployment. The term *dual sheath* relates to the fact that the delivery system has a coaxial design featuring a primary sheath that provides support during introduction through the access site and an inner secondary sheath that is advanced to the deployment site.

Double Branch Arch System

Branch tunnel position on the desired greater curve is permitted with Bolton's patented self-orienting pre-curved nitinol guidewire lumen, which enables alignment of the arch graft's cannulation window to the primary curve of the arch. The off-the-shelf graft will come in a double-branch design with two parallel tunnels equidistant from the proximal edge of the main stent graft.

The Double Branch Arch system (Bolton Medical; Figure 3) is not currently involved in any United States feasibility studies. However, efforts are underway to initiate investigation under FDA guidance. The graft is available in a few markets outside the United States under special access or custom-made regulations.

Zenith Arch Branched Graft

The Zenith arch branched graft (Cook Medical; Figure 4) is a custom-made device intended for aneurysms and chronic dissections of the aortic arch by providing patients with an option to seal an endovascular repair in the ascending aorta (zone 0). The graft includes two inner branches that preserve blood flow to arch vessels, generally the innominate and left common carotid arteries (Figure 2). The graft is loaded into a large Flexor sheath (20–24 F) (Cook Medical) that has a precurved inner nitinol cannula to ensure orientation of the branches with the arch vessels. Four trigger wires attach the proximal edge of the graft to the central shaft of the delivery system just behind the fusiform tip. The first is a spiral stabilizing




Figure 3. The Double Branch Arch system.

wire, and the second is an inner curve proximal attachment, the release of which ensures medial wall attachment of the proximal stent. The third releases the diameter-reducing ties that give the "proform" effect for first stent deployment, which helps to prevent bird-beak configuration along the medial curve of the ascending aorta, and the fourth secures the distal end of the stent graft to the central shaft of the delivery system. All four trigger wires are attached to a single ring on the outer end of the shaft. Placement of the bridging stents is from a retrograde approach via access to the supra-aortic vessels. The device seals distally in the descending thoracic aorta and may be used with additional thoracic grafts to achieve a seal in a healthy segment of the thoracic aorta. The graft has been used globally in more than 100 patients in clinical studies, under special access, and in compassionate use cases⁴ with acceptable morbidity and mortality. An off-the-shelf version, based on the common designs of their custom device grafts, is more than likely in the near future.

DISCUSSION

Near-total endovascular treatment of aortic arch aneurysms requires collaboration between cardiothoracic surgery, vascular surgery, and, depending on the center of excellence, interventional radiology and/or interventional cardiology to provide patients with the best and most appropriate treatment option. There is clearly a role for near-total minimally invasive aortic arch aneurysm repair,

Courtesy of Bolton Medical.



Courtesy of Cook Medical.

Figure 4. The Zenith arch branched graft in the superior view (A), lateral view (B), and proximal view (C). I = innominate branch; C = left common carotid branch.

especially in patients deemed unfit for open repair because of either anatomic or physiological reasons. Whether results can match traditional open repair in high-volume centers remains to be answered in future trials.

Many questions remain unanswered for this emerging technology. Will we be able to duplicate the results for traditional open arch reconstruction? Will these endovascular repairs be only suitable for patients deemed high risk for complex open repair, or will they become the new standard of care? Will retrograde flow into supra-aortic vessels be sufficient in the mid to long term? Will branch stent grafts withstand the harsh environment of the aortic arch in the mid to long term? Clinical trials will no doubt address some of these questions in the near future.

With this exciting technology within grasp, it is clear that physician-modified grafts, in situ fenestration techniques, and debranching hybrid operations will be performed less frequently as thoracic stent graft technology for the arch becomes more widely available. Near-total endovascular options for patients with challenging aortic arch pathology have finally become a reality. ■

Cherrie Z. Abraham, MD, is the Director of the Knight Cardiovascular Aortic Center, and Associate Professor of Surgery, Oregon Health and Science University, Division of Vascular and Endovascular Surgery in Portland, Oregon. He has disclosed that he is a paid consultant and proctor for Cook Medical. Dr. Abraham may be reached at (503) 494-7593; abrahach@ohsu.edu.

Victor M. Rodriguez, MD, is a cardiothoracic, vascular, and endovascular surgeon with the Knight Cardiovascular Institute, and Associate Professor of Surgery, Oregon Health and Science University, Division of Cardiothoracic and Vascular Surgery in Portland, Oregon. He has stated that he has no financial interests related to this article.

- Lioupis C, Abraham CZ. Results and challenges for the endovascular repair of aortic arch aneurysms. *Perspect Vasc Surg Endovasc Ther.* 2011;23:202-213.
- Bavaria J, Vallabhajosyula P, Moeller P, et al. Hybrid approaches in the treatment of aortic arch aneurysms: postoperative and midterm outcomes. *J Thorac Cardiovasc Surg.* 2013;145(3 suppl):S85-90.
- Lioupis C, Coriveau MM, MacKenzie KS, et al. Treatment of aortic arch aneurysms with a modular transfemoral multibranch stent graft: initial experience. *Eur J Vasc Endovasc Surg.* 2012;43:525-532.
- Haulon S, Greenberg RK, Spear R, et al. Global experience with an inner branched arch endograft. *J Thorac Cardiovasc Surg.* 2014;148:1709-1716.
- Donas KP, Lee JT, Lachat M, et al. Collected world experience about the performance of the snorkel/chimney endovascular technique in the treatment of complex aortic pathologies: the PERICLES registry. *Ann Surg.* 2015;262:546-553.
- Scali ST, Feezor RJ, Chang CK, et al. Critical analysis of results after chimney endovascular aortic aneurysm repair raises cause for concern. *J Vasc Surg.* 2014;60:865-873; discussion 873-875.
- Sugiura K, Sonesson B, Akesson M, et al. The applicability of chimney grafts in the aortic arch. *J Cardiovasc Surg (Torino).* 2009;50:475-481.
- Weigang E, Parker JA, Czerny M, et al. Should intentional endovascular stent-graft coverage of the left subclavian artery be preceded by prophylactic revascularisation? *Eur J Cardiothorac Surg.* 2011;40:858-868.
- Tse LW, Lindsay TF, Roche-Nagle G, et al. Radiofrequency in situ fenestration for aortic arch vessels during thoracic endovascular repair. *J Endovasc Ther.* 2015;22:116-121.
- Ahanchi SS, Almaroof B, Stout CL, et al. In situ laser fenestration for revascularization of the left subclavian artery during emergent thoracic endovascular aortic repair. *J Endovasc Ther.* 2012;19:226-230.