

Pregnancy



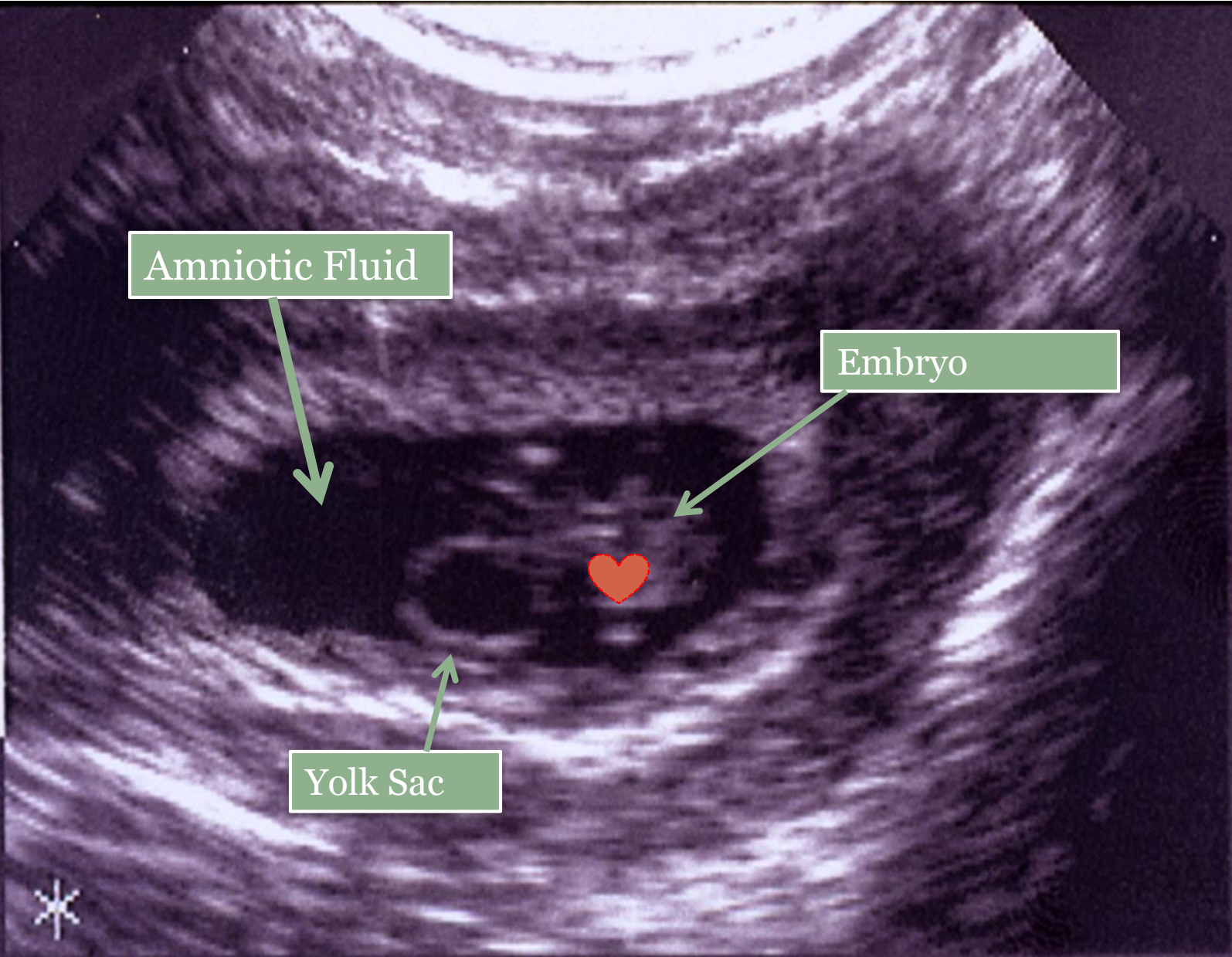
WHAT IS NORMAL,
WHAT CAN GO WRONG, AND HOW
CAN WE ASSIST INFERTILE
COUPLES?

PART 3



THIS WORK IS LICENSED UNDER A [CREATIVE COMMONS ATTRIBUTION-NONCOMMERCIAL-SHAREALIKE 4.0 INTERNATIONAL LICENSE](https://creativecommons.org/licenses/by-nc-sa/4.0/).

NRNG
7 db
7.59
PTH
1 MM
OWER
00%
FPS
44
EJECT
2
EDGE
2
GREY
2
MOOTH
3
LPHA



Amniotic Fluid

Embryo

Yolk Sac

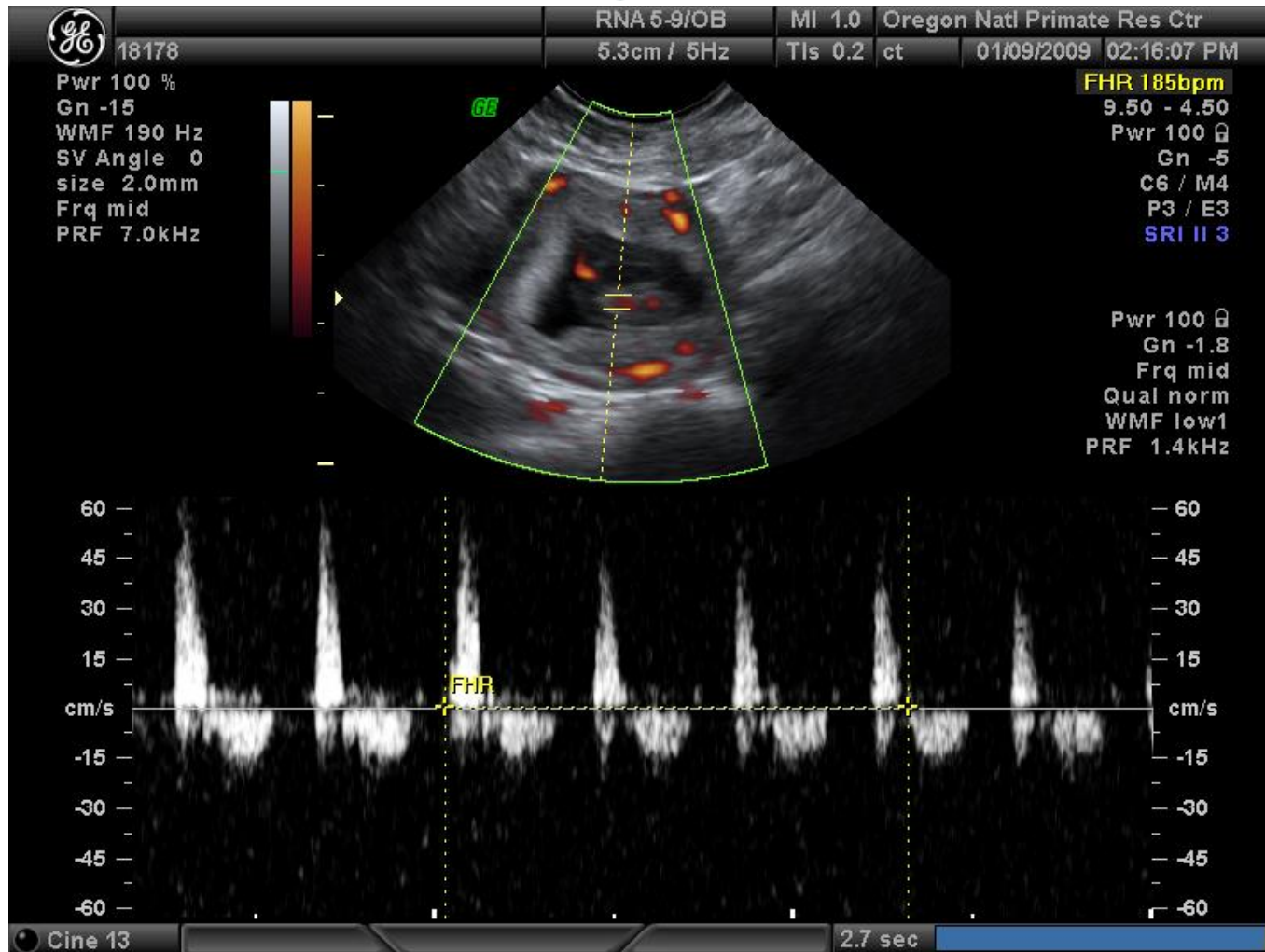
*

NAME Zelinski-Mooten 6/13/95
ID 13950 OVX+E+P Ov ET Day 36

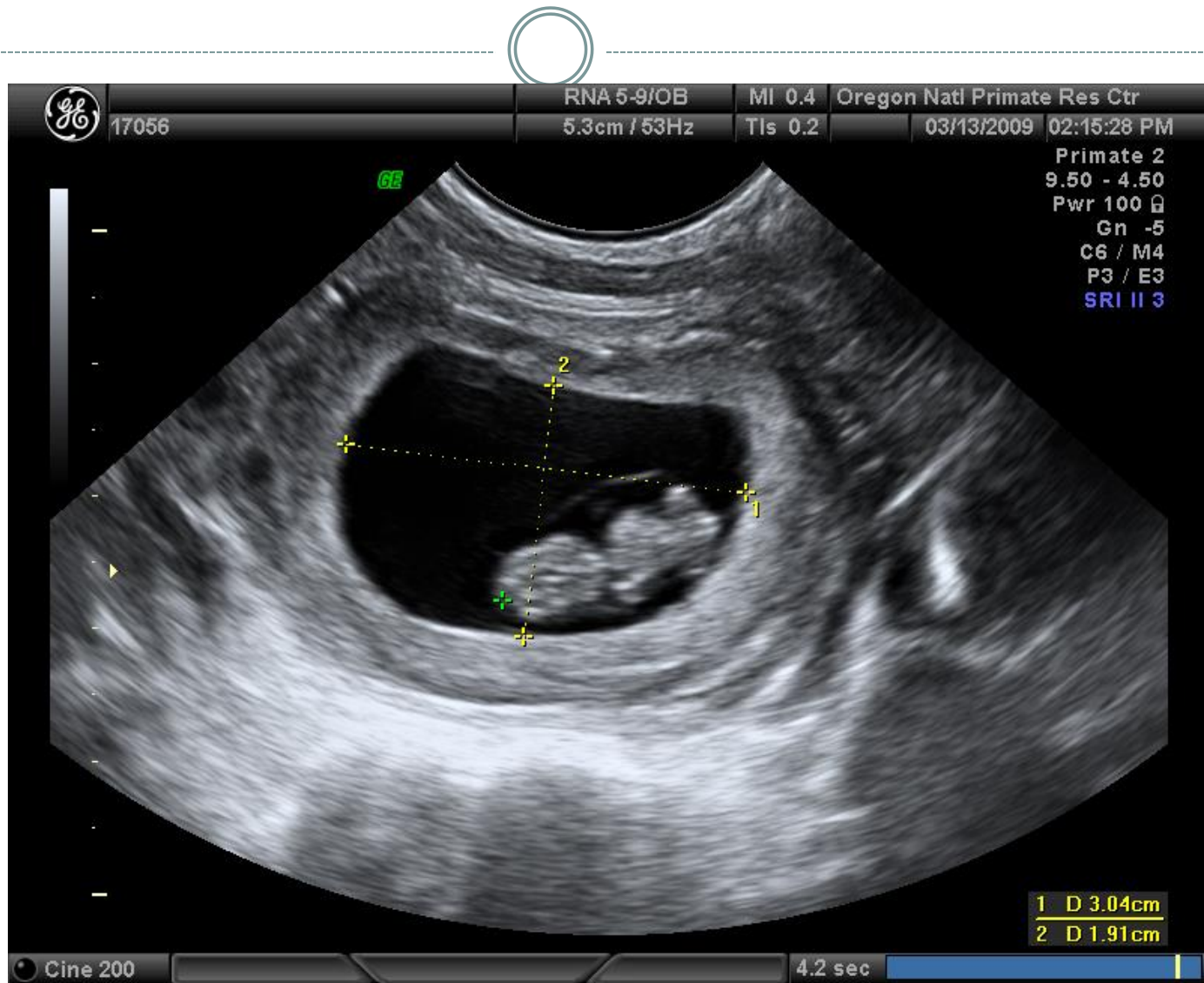


TO
PRE

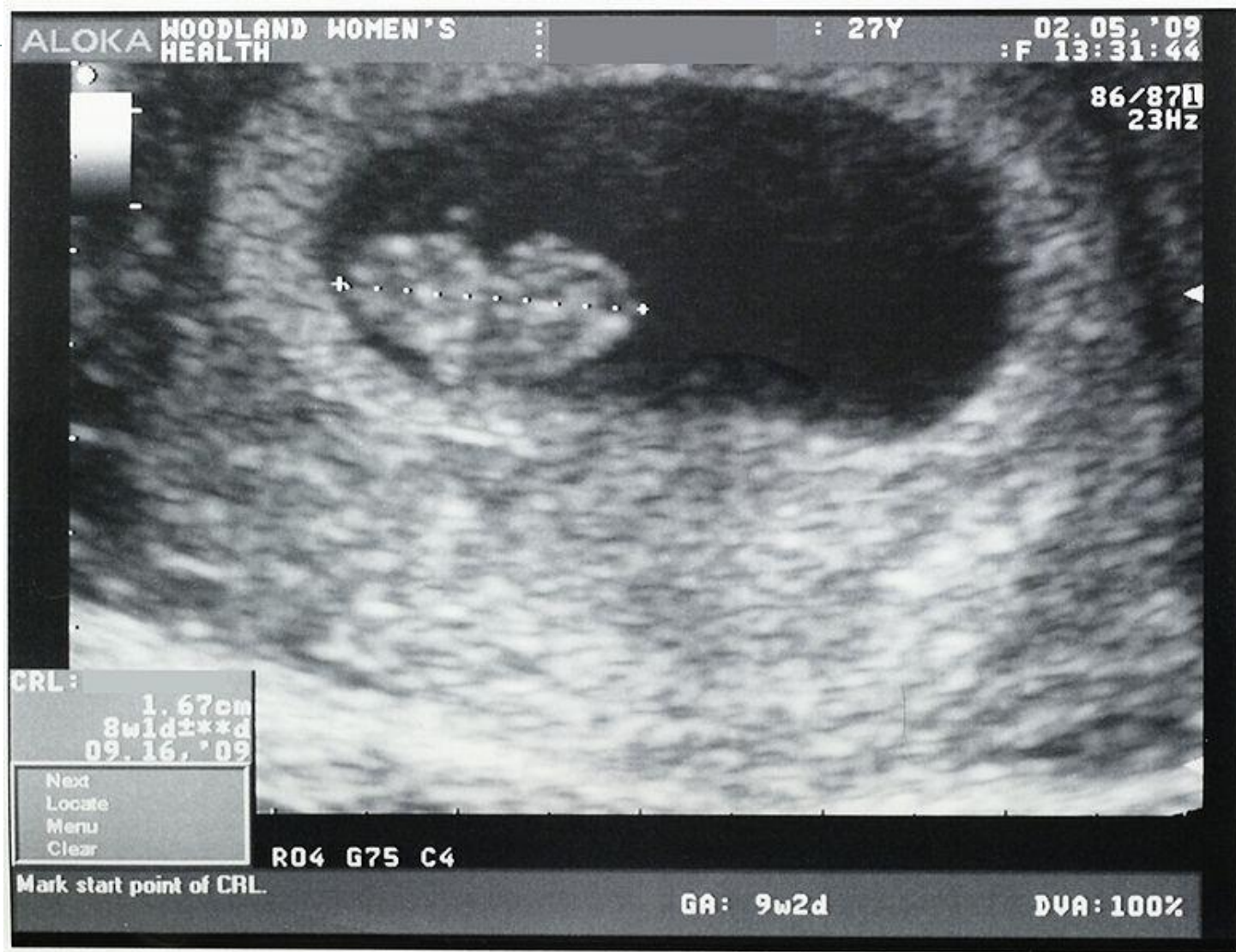Ultrasound of a Fetal Rhesus Macaque – Measuring Fetal Heart Rate



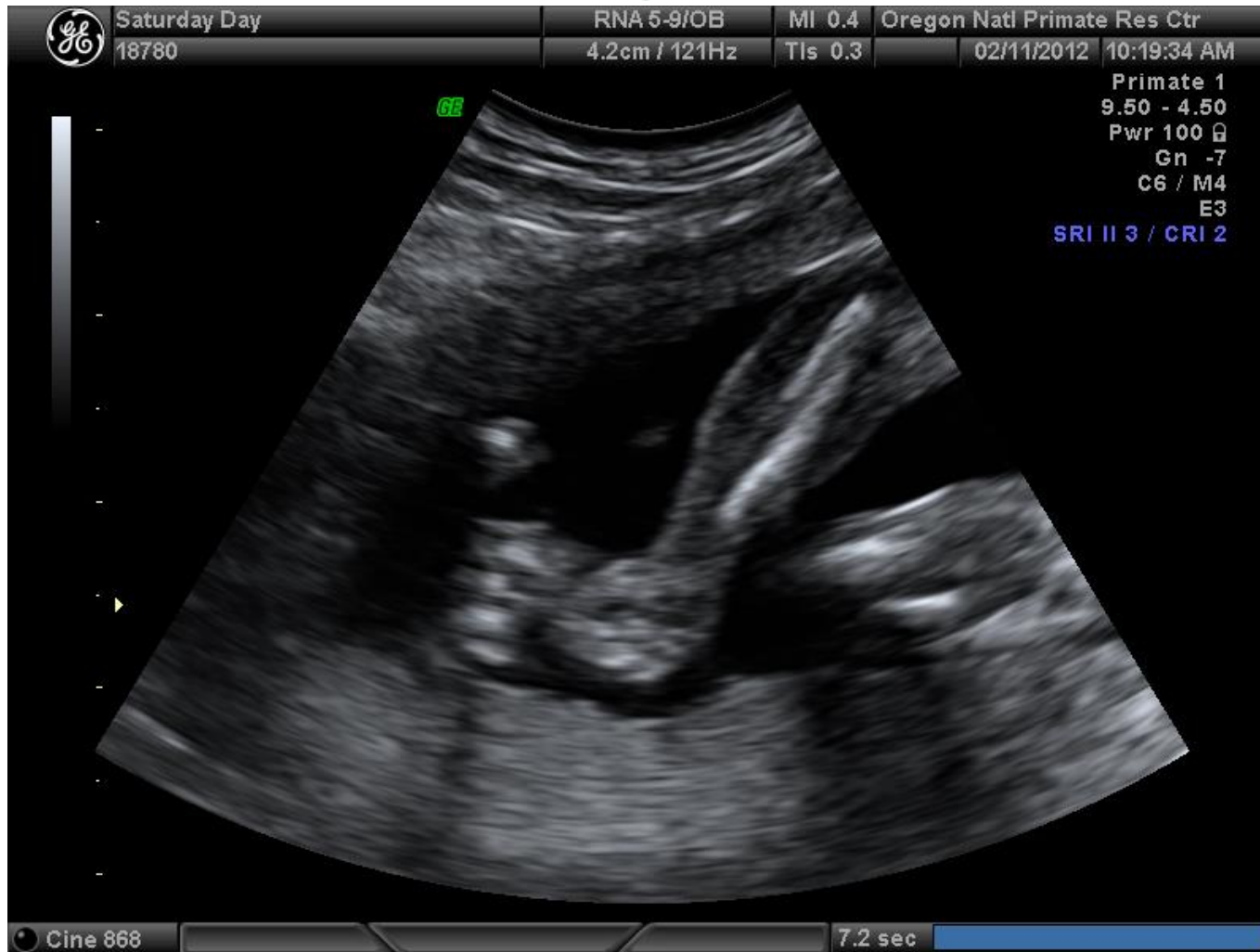Ultrasound in a Fetal Rhesus Macaque – Measuring Crown to Rump Length



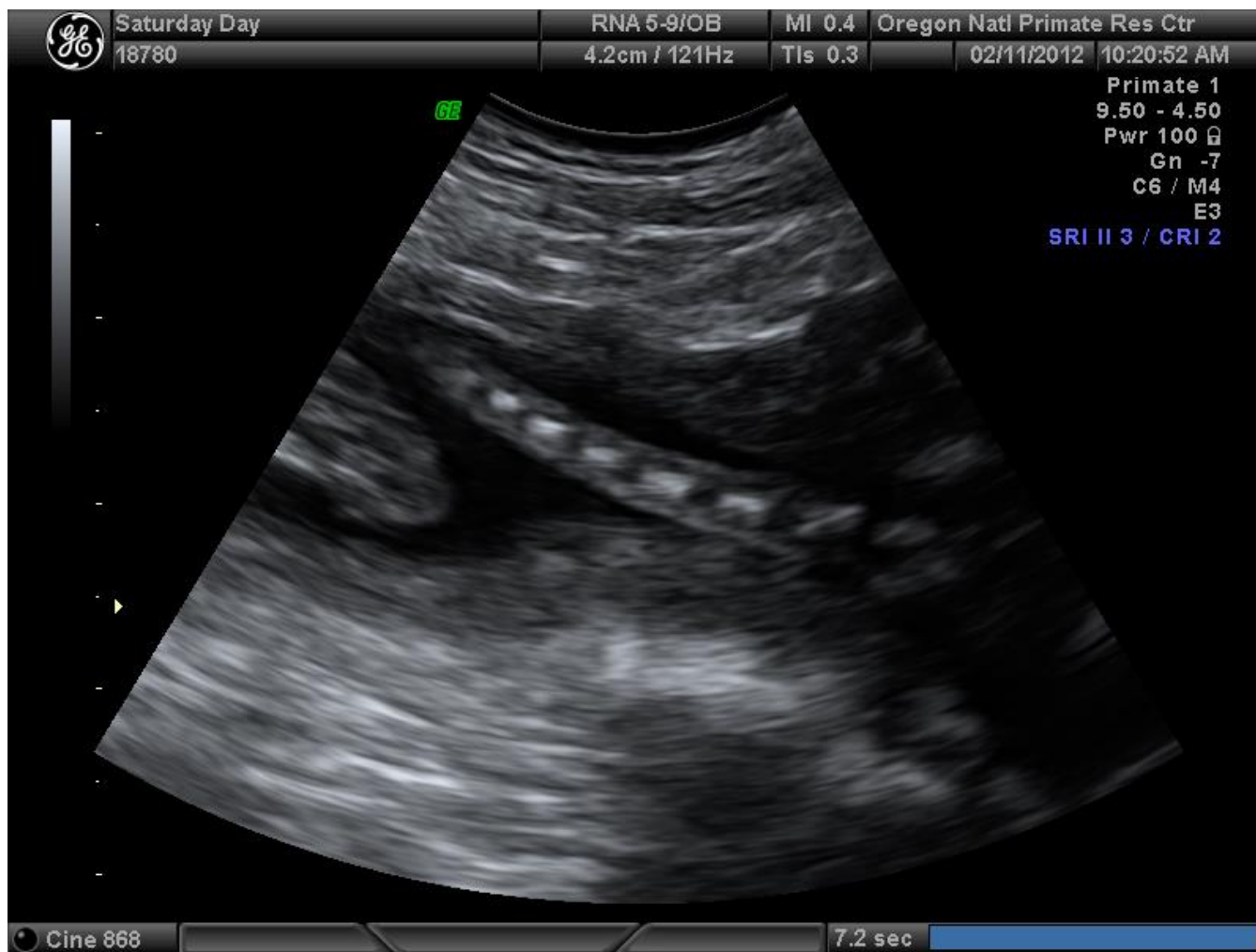
Ultrasound of a Fetal Human - Measuring Crown to Rump Length



Ultrasound of Fetal Rhesus Macaque Arm



Ultrasound of Fetal Rhesus Macaque Tail



Ultrasound of Fetal Rhesus Macaques Head and Ribs- Measuring Cranial Size

