



Surgery for Advanced Colon Cancer

Knight Cancer Network Symposium 3/18/2021

Flavio G. Rocha, MD, FACS, FSSO
Hugh and Georgeina Hedinger Chair of Surgical Oncology
Physician-in-Chief, Knight Cancer Institute
Oregon Health and Science University, Portland, OR, USA

Advanced Colorectal Cancer



- 150,000 new CRC diagnosed each year in US
- >50% will develop liver metastases
- 70% of patients will have a recurrence (50% liver)
- Proven benefit of systemic chemotherapy in mCRC

Hepatic Resection for Metastases From Colorectal Carcinoma Is of Dubious Value

William Silen, MD

Arch Surg—Vol 124, September 1989

Resection of Hepatic Metastases from Colorectal Cancer

Biologic Perspectives

Ann. Surg. • August 1989

GLENN STEELE, JR., M.D., and T.S. RAVIKUMAR, M.D.

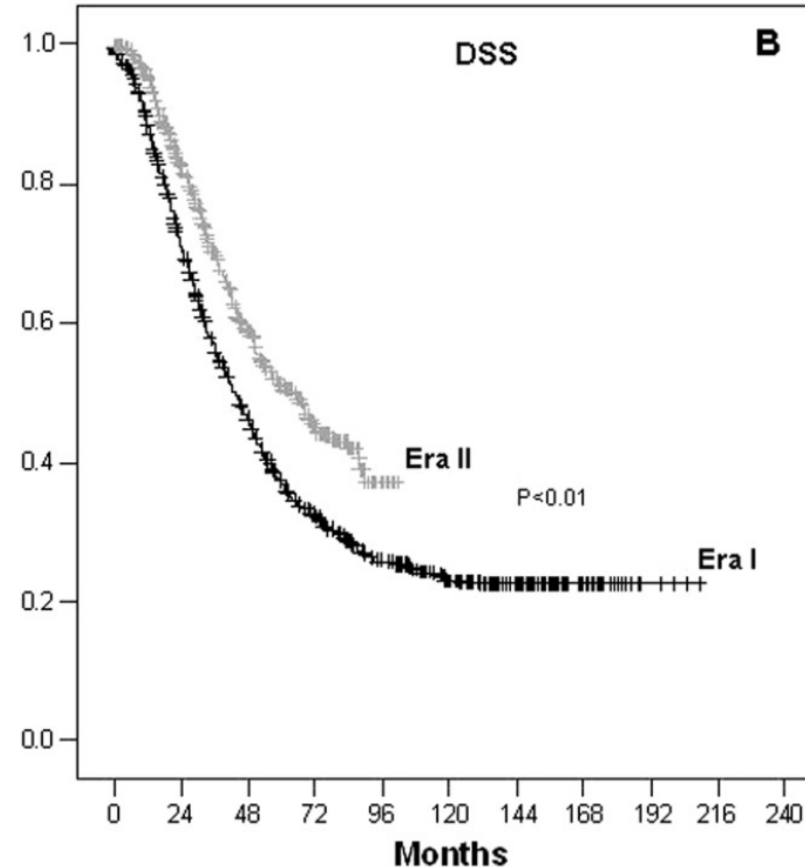
-
1. Resect metastases only from colorectal cancer primary
 2. Resect only when no comorbid disease
 3. Resect only when no extrahepatic recurrence
 4. Resect three or fewer metastases (either uni- or bilobar)
 5. Resect all disease (i.e., obtain tumor-free margins)
-

Survival after Hepatic Resection for Metastatic Colorectal Cancer: Trends in Outcomes for 1,600 Patients during Two Decades at a Single Institution

Michael G House, MD, Hiromichi Ito, MD, Mithat Gönen, PhD, Yuman Fong, MD, FACS, Peter J Allen, MD, FACS, Ronald P DeMatteo, MD, FACS, Murray F Brennan, MD, FACS, Leslie H Blumgart, MD, FACS, William R Jarnagin, MD, FACS, Michael I D'Angelica, MD, FACS

Era I 1984-1998: 1037 patients: 5yr DSS 37%

Era II 1999-2004: 563 patients: 5yr DSS 51%



What have we improved?

- Chemotherapy agents and timing
 - Oxaliplatin, Irinotecan, Biologics
 - Neoadjuvant vs Adjuvant vs Perioperative
- Patient selection
 - Prognostic and predictive factors
 - Management of EHD, response to chemo
- Safe and effective hepatectomy
 - Minimize morbidity (blood loss, preserve liver)
 - Adjuncts to surgery (PVE, ablation, HAI, 2 stage)

Randomized Controlled Trials

- **NONE** on hepatic resection
- Adjuvant systemic chemotherapy following hepatic resection of CLMs has marginal statistical benefit
- The largest level I evidence to date supports neoadjuvant chemotherapy prior to resection

Factors under Surgeon's Control

- Patient Selection
- Margin status
- Morbidity

Patient Selection: Resectability

- Medical fitness for an operation
- Proper onc staging (EHD, response to tx)
- Ability to remove disease with adequate margins and preserve liver function
- Resectable
- Borderline resectable
- Unresectable but downstageable
- Unresectable not downstageable

Patient Selection: Prognostic factors

Primary

- **Node⁺ primary**
- Extent of nodal mets
- LVI of primary
- Differentiation
- T-stage primary
- **Disease-free interval <1yr**
- Colon vs rectum

Liver metastases

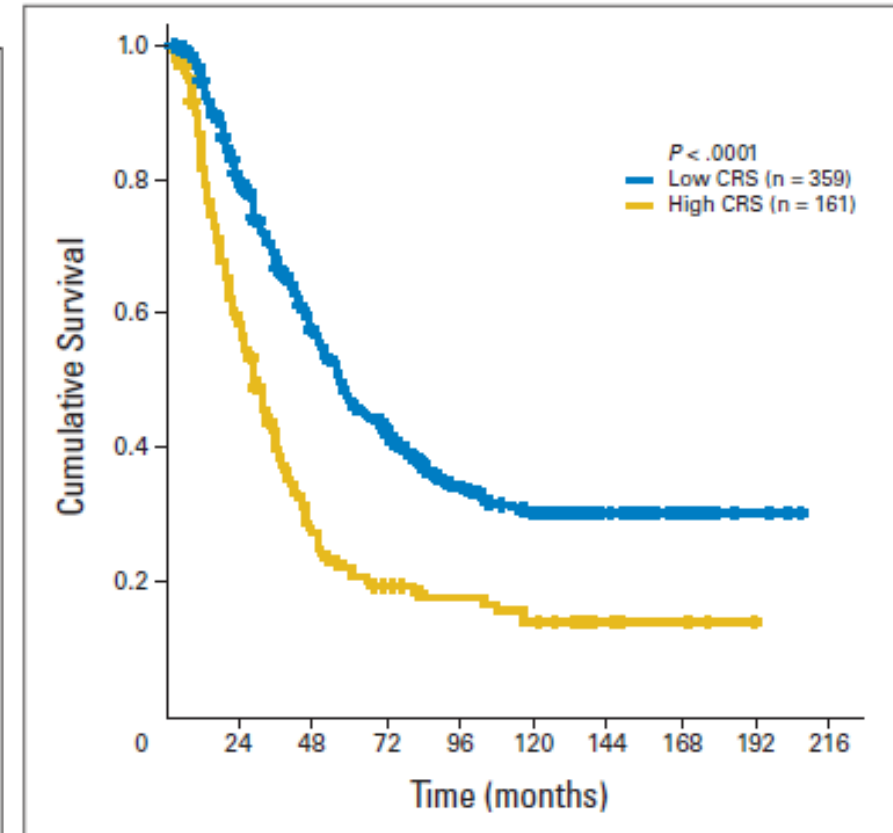
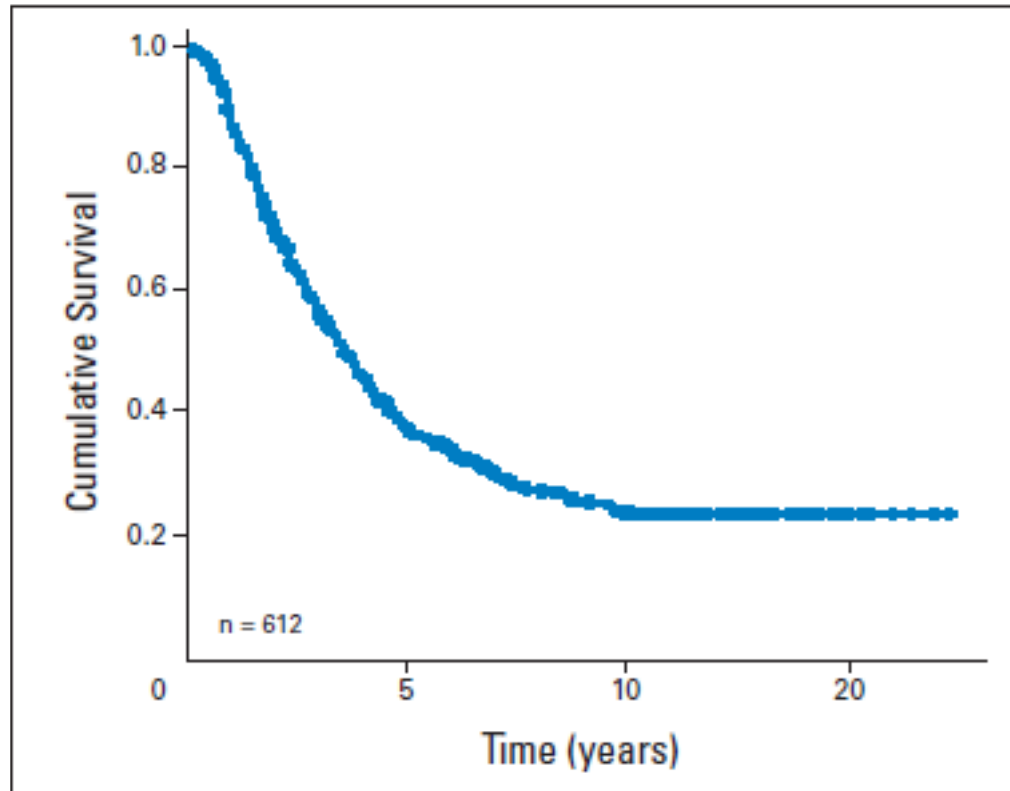
- Margins
- **Size of largest tumor >5 cm**
- **# tumors >1**
- **CEA > 200 ng/ml**
- Extrahepatic disease
- Bilobar disease
- Progression on chemo
- Periop morbidity

Clinical Risk Score (CRS): 1 pt for each

Actual 10-Year Survival After Resection of Colorectal Liver Metastases Defines Cure

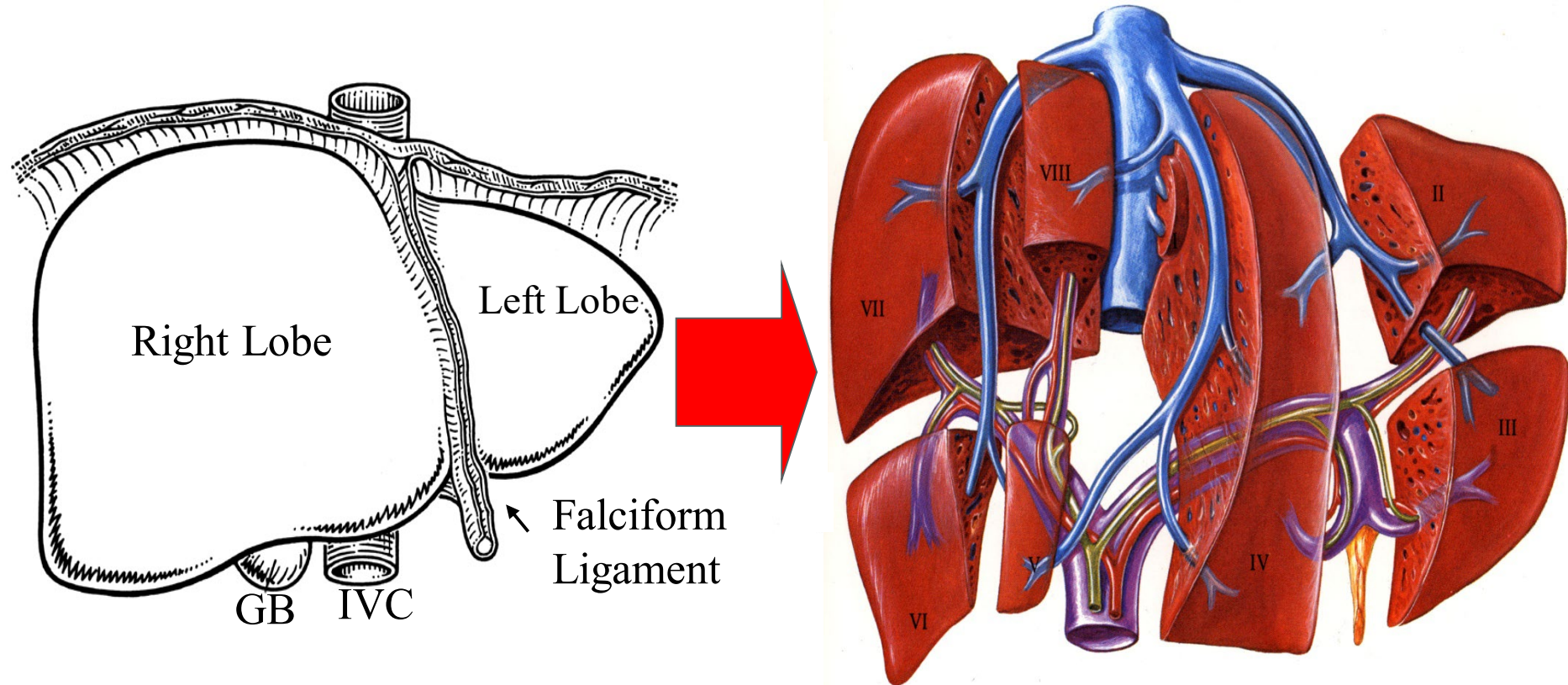
James S. Tomlinson, William R. Jarnagin, Ronald P. DeMatteo, Yuman Fong, Peter Kornprat, Mithat Gonen, Nancy Kemeny, Murray F. Brennan, Leslie H. Blumgart, and Michael D'Angelica

J Clin Oncol 25:4575-4580. © 2007 by American Society of Clinical Oncology



Cure rate varies between 17% and 25% due to censoring of pts lost to follow-up
16 out of 102 10-yr survivors had recurrences and all but one resected

Segmental Anatomy



Margin-negative resection leaving at least 2 contiguous liver segments with adequate perfusion and biliary drainage

What type of resection is best?

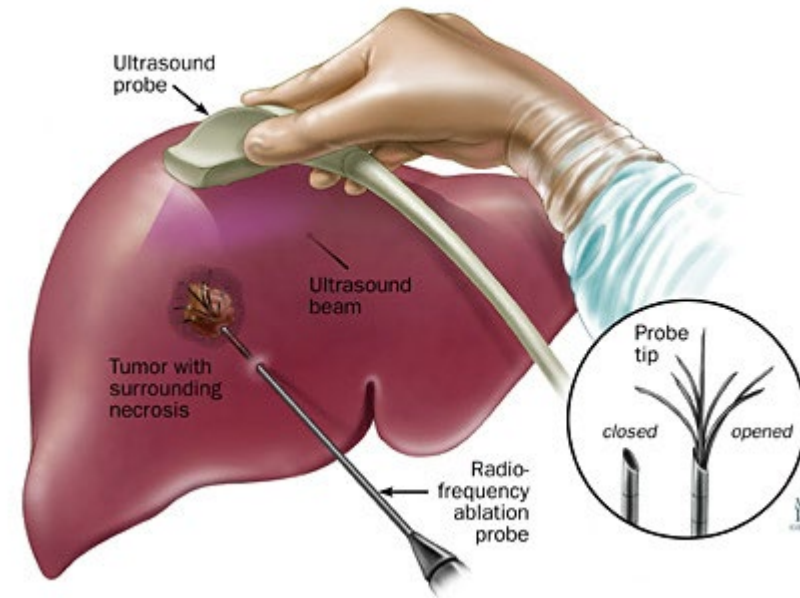
- Extended hepatectomy
- Hemihepatectomy
- Sectionectomy
- Segmentectomy
- Subsegmentectomy (wedge resection)

Elements of Parenchymal-sparing Hepatectomy

- Neoadjuvant Chemotherapy
 - Potential for downstaging surgery
 - New and disappearing lesions
- Knowledge of Biliary and Vascular Anatomy
 - Preservation of inflow and outflow
 - Don't “burn any bridges”
- Incorporation of Ablation

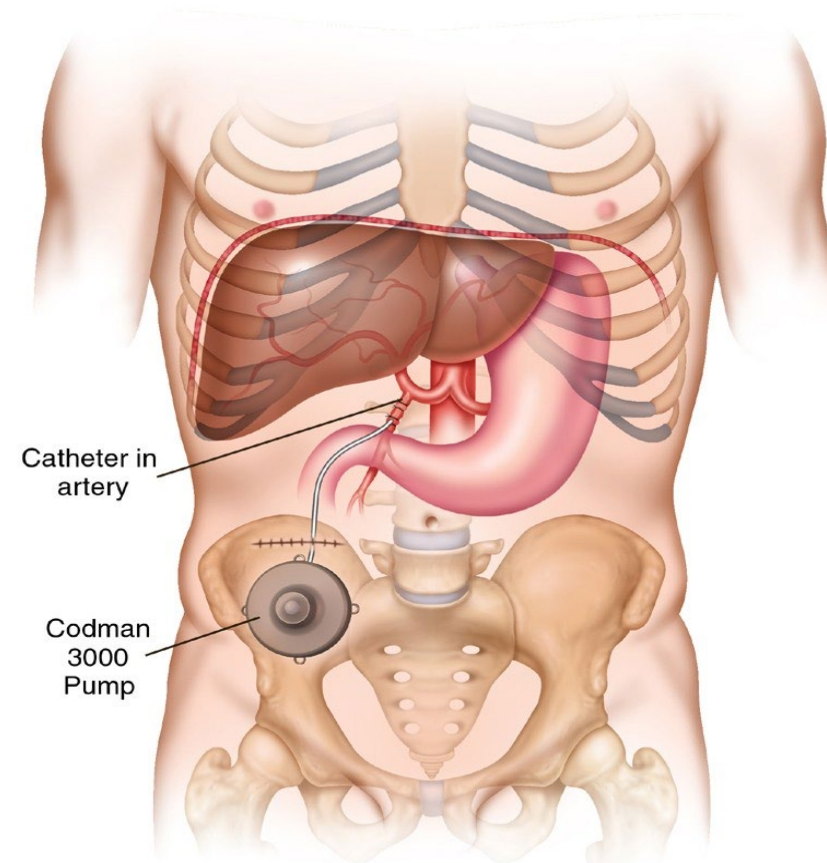
Ablation Techniques

- Ethanol injection
- Cryoablation
- Radiofrequency Ablation
- Microwave Coagulation
- Irreversible Electroporation



Rationale for Hepatic Artery Infusion Pump (HAIP)

- 1) Liver metastases perfused by hepatic artery
- 2) Chemotherapy extracted during first pass in liver decreasing systemic toxicity
- 3) 50% of patients with mCRC will have liver metastases
- 4) Liver may be only site of metastatic disease



Indications for HAIP

- 1) First line therapy for unresectable CLM
- 2) Second line therapy following progression
- 3) Adjuvant therapy following hepatectomy
- 4) Neoadjuvant therapy for downstaging
- 5) Primary liver tumors

Pros and Cons

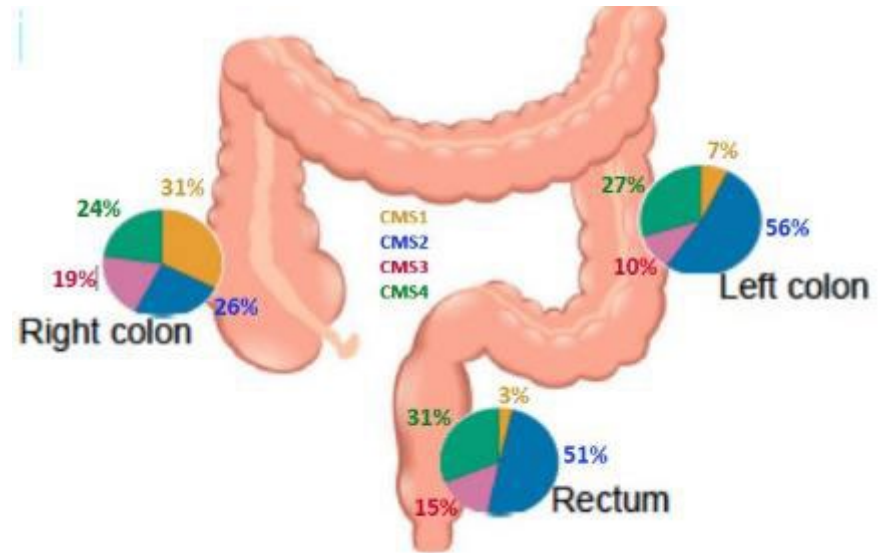
- Advantages
 - 1) Increased response rate
 - 2) Conversion to resectable disease
 - 3) Improved survival
- Disadvantages
 - 1) Need for operation
 - 2) Complications (vascular, biliary)
 - 3) Does not treat extrahepatic dz

The consensus molecular subtypes of colorectal cancer

Justin Guinney^{1,21}, Rodrigo Dienstmann^{1,2,21}, Xin Wang^{3,4,21}, Aurélien de Reyniès^{5,21}, Andreas Schlicker^{6,21}, Charlotte Soneson^{7,21}, Laetitia Marisa^{5,21}, Paul Roepman^{8,21}, Gift Nyamundanda^{9,21}, Paolo Angelino⁷, Brian M Bot¹, Jeffrey S Morris¹⁰, Iris M Simon⁸, Sarah Gerster⁷, Evelyn Fessler³, Felipe De Sousa E Melo³, Edoardo Missiaglia⁷, Hena Ramay⁷, David Barras⁷, Krisztian Homicsko¹¹, Dipen Maru¹⁰, Ganiraju C Manyam¹⁰, Bradley Broom¹⁰, Valerie Boige¹², Beatriz Perez-Villamil¹³, Ted Laderas¹, Ramon Salazar¹⁴, Joe W Gray¹⁵, Douglas Hanahan¹¹, Josep Tabernero², Rene Bernards⁶, Stephen H Friend¹, Pierre Laurent-Puig^{16,17,22}, Jan Paul Medema^{3,22}, Anguraj Sadanandam^{9,22}, Lodewyk Wessels^{6,22}, Mauro Delorenzi^{7,18,19,22}, Scott Kopetz^{10,22}, Louis Vermeulen^{3,22} & Sabine Tejpar^{20,22}

NATURE MEDICINE VOLUME 21 | NUMBER 11 | NOVEMBER 2015

CMS1 MSI immune	CMS2 Canonical	CMS3 Metabolic	CMS4 Mesenchymal
14%	37%	13%	23%
MSI, CIMP high, hypermutation	SCNA high	Mixed MSI status, SCNA low, CIMP low	SCNA high
<i>BRAF</i> mutations		<i>KRAS</i> mutations	
Immune infiltration and activation	WNT and MYC activation	Metabolic deregulation	Stromal infiltration, TGF- β activation, angiogenesis
Worse survival after relapse			Worse relapse-free and overall survival

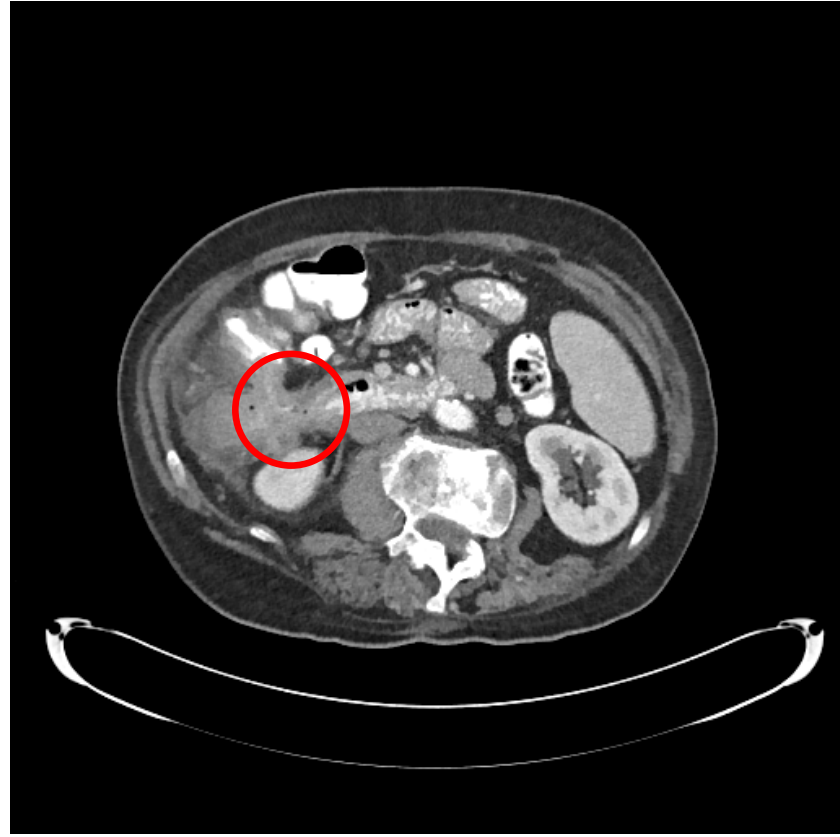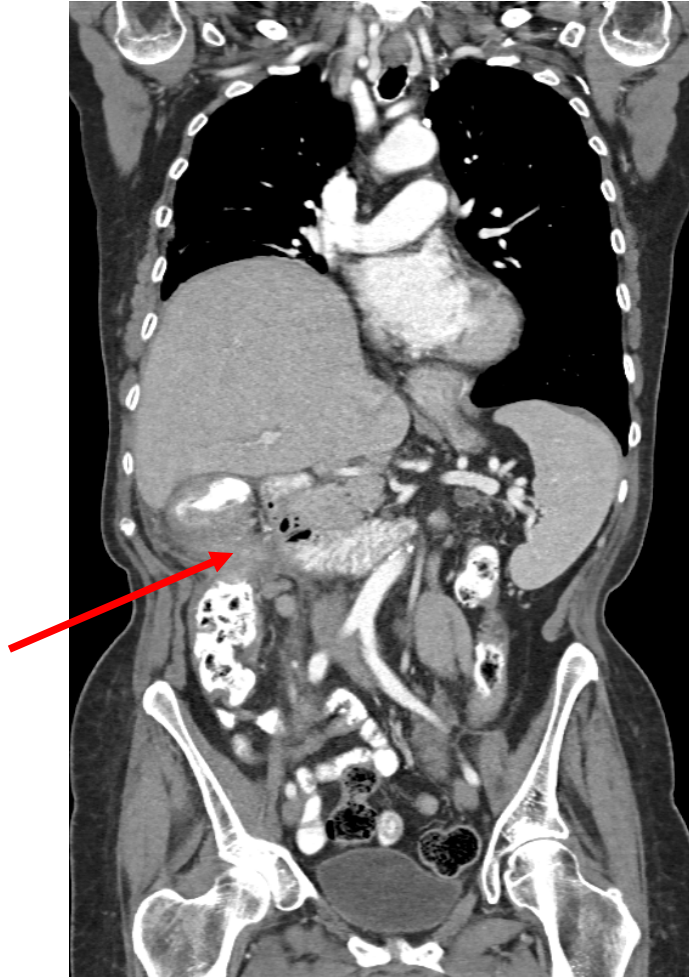


Case Presentation

- HPI: 77yF transferred to our facility with iron-deficiency anemia and a colonic mass on computed tomography
- PMHX: Early stage right breast cancer status post partial mastectomy with sentinel node biopsy, followed by adjuvant radiation 2015, currently on adjuvant anastrozole
- FHx: Sister with breast cancer age 30, brother with prostate cancer, MGM with uterine cancer, uncle with “liver” cancer

Work-up

- Chest, abdomen, pelvis CT:
 - 10 cm mass in ascending colon invading into duodenum
 - Multiple enlarged mesenteric lymph nodes
 - No lung or liver lesions
- Upper and lower endoscopy:
 - Partially obstructing mass at 60 cm invading into the duodenum, biopsy c/w poorly diff adenoca with ulceration
 - Loss of MLH1,PMS2; + for a BRAF V600E (1799T>A)

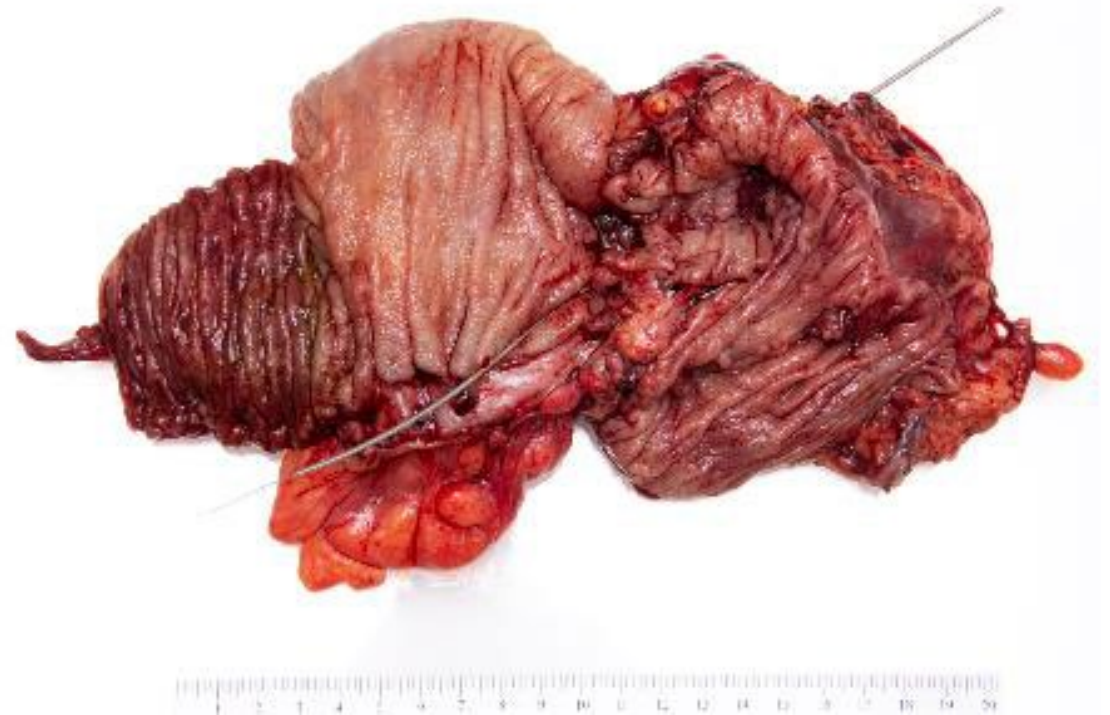

Neoadjuvant therapy

- Given MSI status and frailty, deemed too high risk for surgery and started on pembrolizumab
- 4 months of therapy with resolution of symptoms, minimal toxicity and markedly improved performance status
- Restaged with partial response and no new lesions

Extended right colectomy with en bloc duodenectomy, partial hepatectomy, cholecystectomy

- 8cm area of necrosis, serositis and inflammation without viable tumor in colon, liver and duodenum extending to radial margin
- 6/25 lymph nodes with viable tumor and treatment effect
- ypT0N2a
- Discharged home on POD#7



Summary and Conclusion

- Surgery remains the objective in treating advanced and metastatic colon cancer
- Novel strategies in liver-directed, targeted and immunotherapy are promising
- Optimal sequencing will need investigation
- Future advancements based on genomic data will affect treatments and outcomes



MARCH

**COLORECTAL
CANCER**

Awareness Month

