OHSU Neurotransmitter

Volume 1 – Issue 1 – Winter 2005

Published by the Oregon Health & Science University Department of Neurological Surgery —— www.ohsu.edu/neurosurgery

In This Issue

Introduction

2
OHSU Spine Center

Clinical Features

3
Metastatic Disease and the Spine

4
Minimally Invasive Spinal Surgery

5
Degenerative Lumbar Disease: When to Fuse?

Department News

5
New Faculty

6
Campagna Professorship

7
News, Events and Research

8
Brain Awareness Events

OHSU Neurological Surgery

The OHSU Neurotransmitter-Winter 2005 focuses on some presently available spine services. The articles provided by Department of Neurological Surgery faculty describe some of the clinical interests and services offered as part of the Neurological Surgery Spine Service available at Oregon Health & Science University.

Portland-area residents select OHSU Health System as best.

2005/06 CONSUMER CHOICE #1

NATIONAL RESEARCH Corporation

Department of Neurological Surgery
Kim J. Burchiel, M.D., F.A.C.S.
John Raaf Professor and Chairman

Neurosurgery
Stanley L. Barnwell, M.D., Ph.D.
Kim J. Burchiel, M.D., F.A.C.S.
Reynaldo DeJesus, M.D.
Johnny B. Delashaw, Jr., M.D.
Jorgé L. Eller, M.D.
Dilan Ellegala, M.D.
Edmund H. Frank, M.D., F.A.C.S.
Andrew N. Nemecek, M.D.
Edward A. Neuwelt, M.D.
Nathan R. Selden, M.D., Ph.D.
Eric Sincoff, M.D.
G. Alexander West, M.D., Ph.D.

Neuroendocrinology
William H. Ludlam, M.D., Ph.D.

Neuroradiology
Gary Nesbit, M.D.

Neuropsychology
David Gostnell, Ph.D.
Richard Kolbell, Ph.D., A.B.P.P.

Otolaryngology
Sean O. McMenomey, M.D.

Pain Management
Kim J. Burchiel, M.D., F.A.C.S.

Physician Assistants
Margaret Dancan, P.A.-C.
Stephen Giles, M.S., P.A.-C.

Nurse Practitioners
Wendy O. Domreis, M.S., R.N., C.P.N.P.
Susan Ferson, M.S.N., C.P.N.P.
Jane Olsen, R.N., C.R.N.P.
Chris G. Yedinak, M.N., C.F.N.P.

Research
Valerie C. Anderson, Ph.D.
Thomas K. Baumann, Ph.D.
Mary M. Heinricher, Ph.D.

Emeritus Faculty
Harold D. Paxton, M.D.

Administration
Shirley McCartney, Ph.D.
Andy Rekito, M.S.
Sally Rodgers, M.H.A.

OHSU Spine Center

The OHSU Department of Neurological Surgery is proud to be involved in the development of the OHSU Spine Center. The center will be at the forefront of a new era of spine care for the citizens of Oregon and Southwest Washington. OHSU's departments of Neurological Surgery, Orthopaedics and Rehabilitation Medicine, the OHSU Pain Management Center, and OHSU Physical Therapy have joined forces to offer patients truly coordinated, one-stop shopping for spine care. The center will offer a full spectrum of comprehensive spine care, from surgical treatment of complex degenerative spine disease to noninvasive holistic pain management for all spine health needs.

The goal of the comprehensive OHSU Spine Center is to set the standard for state-of-the-art care for patients with spinal disorders. The multidisciplinary approach of the OHSU Spine Center will involve physiatrists, psychologists, pain specialists, and surgeons in the management of patients who have spinal problems, including back pain, as well as those patients who are potential candidates for spinal surgery. Physicians and staff involved are already actively collaborating and patient referrals can de directed to **800 245-6478**.

Fall 2006, the center will move to the OHSU Center for Health and Healing, under construction in Portland's new South Waterfront District. Plans for the waterfront campus include: offering convenient access to onsite radiology, rehabilitation therapy, and pain management services. Spine Center staff will focus on the continuity of spine care and will help coordinate each patient's treatment plan, including both outpatient services and hospital stays. "This is an important step in fulfilling our commitment to our patients with spine problems" said **Kim Burchiel**, M.D., chairman of neurological surgery at OHSU. "OHSU is a large and complex health system. **Jung Yoo**, M.D., chairman of orthopaedics and rehabilitation, and I agree that helping patients navigate the various services that comprise high quality, cost-effective, comprehensive spine care is in the very best interests of our patients, and their health insurance providers."

Kim J. Burchiel, M.D., F.A.C.S.
Professor and Chairman

G. Alexander West, M.D., Ph.D.
Associate Professor
Chief, Division of Spine Surgery

Neurological Surgery at the OHSU Spine Center

Patient Referrals
800 245-6478

G. Alexander West, M.D., Ph.D., Neurosurgeon
Edmund H. Frank, M.D., Neurosurgeon
Andrew N. Nemecek, M.D., Neurosurgeon
Stephen Giles, M.S., P.A.-C., Physician Assistant

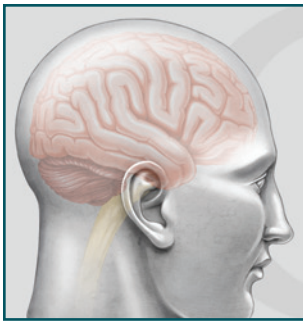

OHSU Neurotransmitter is published semi-annually by the Department of Neurological Surgery, OHSU School of Medicine, for colleagues, allumni and friends of the department.

For inquiries, submissions or suggestions, please contact Shirley McCartney, Ph.D., 503 494-7469 (mccartns@ohsu.edu)

Learn more about our department on the web at www.ohsu.edu/neurosurgery

Editor: Shirley McCartney, Ph.D.
Illustrator: Andy Rekito, M.S.
Contributors: Kim J. Burchiel, M.D., F.A.C.S., G. Alexander West, M.D., Ph.D., Edmund H. Frank, M.D., F.A.C.S., Matthew A. Hunt, M.D., Andrew N. Nemecek, M.D., Michael MacRae, Jonathan Modie and Shirley McCartney, Ph.D.

Metastatic Disease and the Spine

by G. Alexander West, M.D., Ph.D.

Spinal metastatic disease commonly affects and can occur in up to 40 percent of cancer patients. In many patients with spinal metastatic disease, neurological symptoms can arise as a result of tumor cells causing compression of the spinal cord or nerve roots, such as from tumors of the breast, lung or prostate, (some tumors can be from the bone itself, such as multiple myeloma). Tumor cells can also invade bone causing bone loss and spinal instability, and neurological symptoms as a result can be serious, potentially leading to paralysis. Pain is a commonly reported symptom in patients with spinal metastasis and it is thought that tumor cells in bone may be the cause of such pain. Recent technical developments and the recognition of effective surgical intervention have lead to significant progress in the management of metastatic spinal disease. Furthermore, recent studies have shown that surgical treatment can offer patients major benefits in preserving neurologic function, decreasing pain and narcotic use, and even prolong life expectancy.

Historically, treatment options for cancer patients with spinal metastasis have included steroid use and radiation treatments. Surgical series from the 1980s reported no surgical benefit over radiation alone and often the surgical treatment included a posterior decompression. Today's surgical procedures coupled with a greater knowledge of the underlying metastatic disease have made surgical treatment safer and more effective.

Indications for treatment of spinal metastatic disease vary. Patients with neurological deficits due to tumor or deformity of the spine should be promptly evaluated. If there are acute neurological deficits, evaluation may require emergent evaluation and treatment. Patients with primary tumors known to be resistant to radiotherapy (renal cell, colon, sarcomas and melanoma) and have spinal disease should be evaluated for potential surgical treatment. Patients with obvious spinal instability and metastatic disease should also be considered for spinal surgery. Other potential indications for surgery include patients with unknown primary and no tissue diagnosis, recurrence of spinal disease after maximal chemotherapy or radiation, and patients with intractable pain unresponsive to medical management.

Conversely, patients who may not be good candidates for surgery are those with tumors that are highly sensitive to radiation, such as lymphoma. Additionally, patients with total paralysis of greater than 24 hours or for several days may not benefit from surgery. If a patient's projected survival is less than three months, or the patient has significant medical co-morbidities or significantly advanced disease, surgical treatment may not be a recommended option. Surgical treatment is palliative and will usually not impact the underlying primary cancer.

The goal of spinal metastasis treatment is to decompress the spinal cord and nerve roots, and stabilize the spine. Improved neurological status, functional status and mobility, and decreased pain can be anticipated as surgical results. The surgery of choice is based on the individual patient's disease and anatomy, and a variety of surgical approaches exist, including minimally invasive and major spine reconstruction.

Minimally invasive surgical techniques have evolved over the last decade and offer a significant change in options for patients with spine disease. Many of these techniques can be applied to treating cancer patients with spinal disease.

For example, balloon kyphoplasty has been safely used to treat several thousand patients with osteoporotic vertebral body fractures. In spinal metastatic disease, often a "pathologic fracture" can occur, resulting in debilitating pain and possibly spinal instability. In pathologic compression fractures, where there is no significant compression or mass effect on the neurologic structures (spinal cord, cauda equina), kyphoplasty can be very effective in treating debilitating back pain. The procedure can be performed as an outpatient procedure, even when multiple levels of the spine are treated.

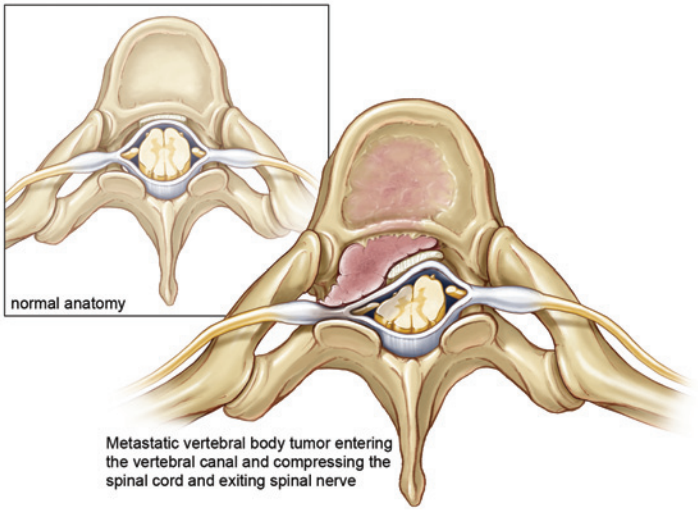

Other evolving, minimally invasive spine procedures include the use of endoscopy-assisted decompression and fusion techniques. The goal is to decrease surgical associated morbidity and shorten hospital-day stay. However, often with metastatic disease, extensive surgery to effectively treat the disease is required and each surgical treatment has to be tailored to the individual patient.

Recently, a large randomized trial of surgery plus radiation versus radiation alone was published. This was the first study of its kind to address the role of surgery in spinal metastatic disease. In this study, the surgical patient group significantly retained the ability to walk and control sphincter function for longer than the radiation group alone. In patients who were unable to walk prior to surgery, the surgical group exhibited a dramatic result, with 62 percent regaining the ability to walk after surgery. In contrast, only 19 percent of the radiation group regained walking ability after treatment. An additional benefit seen in the surgical group included a decrease in steroid and narcotic use. Other studies have shown that in surgical patients, pain can be reduced in up to 95 percent of patients.

However, aggressive surgical management can be associated with significant morbidity. Because of the patient's underlying disease, wound healing can be a significant issue and reports have shown that radiation within seven days is associated with wound problems and other issues. There are also known risks associated with any surgical procedure, which can include neurologic deficits and failure of the fusion or hardware used to stabilize the spine. The risks of aggressive surgical management must be weighed for each patient preoperatively with the aim of providing optimum care for each individual patient.

A wide array of surgical treatment options can be considered for patients with metastatic spinal disease. Recent results have provided compelling evidence that surgical treatment of this disease is effective and relatively safe. The surgical approach should be uniquely tailored for the exact location and overall best treatment of each individual patient's disease. Treatment options and surgical development continue to evolve and include developments of minimally invasive techniques, radiation treatment options and medical management. Ultimately, the treatment of patients should result from multidisciplinary strategic planning, individualized for each patient. The overriding goal is to provide the best possible treatment for maintaining meaningful quality of life given a challenging underlying disease.

Minimally Invasive Spinal Surgery

by Edmund H. Frank, M.D. and Matthew A. Hunt, M.D.

In the last decade, a great deal of interest has focused on the development of minimally invasive surgery. The concept behind minimally invasive surgery is to accomplish complete operative goals with minimum disruption of the important anatomic structures adjacent to the surgical site.

Minimally invasive surgery involving the spine has two forms.

First, true endoscopic surgery is a surgical procedure performed using an endoscope. Research in the 1980s transcended endoscope use as solely an observational/diagnostic tool to an operative tool and led to the development of sophisticated endoscopes and newer techniques. Endoscopic foramenotomy is an example of this form of minimally invasive surgery.

Second, minimally invasive surgery is a surgery that involves an expansion, or rather a contraction of traditional surgical approaches to the spine. In this case, narrower classic approaches to the spine are performed using specially designed surgical retractors to minimally disrupt tissues and structures adjacent to the spine. An example of this approach is the minimally invasive anterior lumbar interbody fusion (mini-ALIF) pioneered by Meyer, or the Metrix retractor system utilized with an operative microscope.

Why endoscopic spine surgery?

The major concept of endoscopic spinal surgery is “less is less”. Smaller incisions with less disruption of the important structures surrounding the spine should lead to less stress on the patient, shortened hospitalizations and shorter recovery times. Additionally, clinical outcomes of endoscopic spine surgery are equivalent to that of traditional procedures. It would be counter-productive to perform a less-invasive surgery that did not allow the necessary space to adequately accomplish the surgical goals. Therefore, as endoscopic spine surgery has developed, a battle between trying to make the approach smaller and making sure that the surgical goals are accomplished has ensued. In many cases, “potential spaces” adjacent to the surgical pathology are expanded so that a surgery can be completely performed.

What conditions are suitable for minimally invasive spinal surgery?

There are a variety of endoscopic approaches to the spine, including anterior and posterior. Each of these approaches allows access to specific parts of the spinal anatomy, for example, the anterior disc space or the neural foramen. Approach can therefore be used to address pathology in each location. Depending upon the anatomy to be traversed to access the spine, access could be through a body cavity (*i.e.*, the thorax) or through a potential space (*i.e.*, the posterior-lateral working triangle).

Many types of minimally invasive surgery are performed at OHSU, including:

- Posterior cervical and lumbar foramenotomy
- Posterior discectomy
- Endoscopic assisted laminotomy/ foramenotomy

Posterior foramenotomy or opening the holes on the sides of the spine, to free up any compression of the spinal cord or nerve roots may be performed at any level of the spine, cervical, thoracic, or lumbar, using an endoscopic approach.

Posterior discectomy or removal of the inner portion of a herniated disk, in the lumbar spine, may be performed in a manner very similar to posterior foramenotomy. In addition to discectomy, a posterior lumbar interbody fusion may also be accomplished with this approach, and may be augmented with percutaneously placed pedicle screw instrumentation.

Endoscopic assisted laminotomy/foramenotomy is a treatment

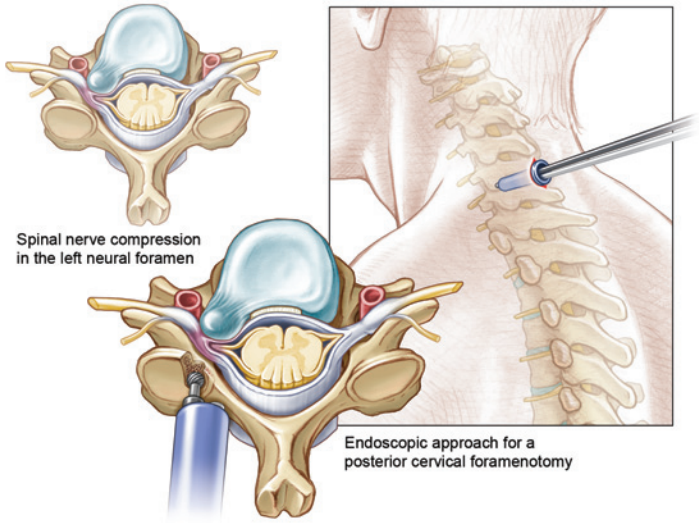

option for patients who are candidates for the surgical treatment of lumbar spinal stenosis. With part (laminotomy) or all (laminectomy) of the lamina (the thin bony layer covering the spinal canal) removed, the surgeon has a better view of the disc and gains greater access to the spinal canal and other parts of the spinal anatomy.

With any surgical procedure, including minimally invasive spinal surgery, there are general risks and procedure specific risks. In experienced hands, the endoscopic procedures carry risks almost identical to the open procedure. For the surgeon who is already comfortable with the anatomy of the open procedure, the learning curve is minimal, but for an inexperienced operator, the unfamiliar viewpoint, coupled with unfamiliar territory, could lead to unfavorable outcomes.

The main question for all of endoscopic procedures is, does the patient benefit? For an endoscopic procedure to be considered a success, the operative goals must be accomplished and the patient must show improvement in at least one of several areas: postoperative pain, ICU and hospital length of stay, or blood loss. If there is no benefit to the patient, then the increased risks, such as from decreased visualization, increased operative time and cost of specialized equipment, may discourage surgeons from performing these procedures. Outcome data has been published for many of these procedures, although there is no randomized data to support procedure use. There are multiple reports with results, but few prospective randomized studies comparing open and endoscopic procedures.

By comparing similar groups with posterior procedures of the cervical and lumbar spine, hospital stays have been shown to be decreased over traditional techniques. Blood loss is reduced, as is postoperative pain medication use, hence less postoperative pain.

In general, spinal endoscopy seems to benefit patients by the ability to approach the spine with less tissue trauma, resulting in less pain, blood loss and dysfunction of nearby organs. In procedures where the patient would be expected to have a short postoperative stay, these techniques seem to reduce postoperative pain, as measured by a decreased need for postoperative pain medication, such that the patient may be discharged earlier.

At this point, the long-term outcomes from spinal endoscopy appear similar to traditional techniques in terms of successful completion of the goals of the particular procedure. However, it is still unclear whether there is a functional benefit from the decreased tissue trauma from these procedures. Minimally invasive spinal surgery has undergone rapid technological advancement and long-term outcome studies, generally rare in spinal surgery, are essential to evaluate the possible benefits. Researchers at the OHSU Spine Center will continue to investigate new treatment approaches for managing the spine using minimally invasive surgery.

Surgery for Degenerative Lumbar Disease: When to Fuse?

by Andrew N. Nemecek, M.D.

Low back pain represents the second most common symptomatic condition for which patients seek medical care in the United States. The annual prevalence of low back pain in the U.S. is estimated at 15–20 percent, with reports that more than 60 percent of Americans will experience severe low back pain at least once in their lifetime. While most cases are resolved within a month, many patients experience recurrent episodes. Degenerative disease of the lumbar spine represents the most common cause of recurrent or progressive symptoms. Surgical treatment has been shown to be effective for certain subsets of patients with degenerative disease. Spinal fusion is a procedure increasingly performed for the treatment of patients with degenerative spinal conditions. However, specific indications for fusion are controversial. At OHSU, we take an evidence-based approach regarding indications for spinal fusion in patients with low back pain and a degenerative lumbar spine.

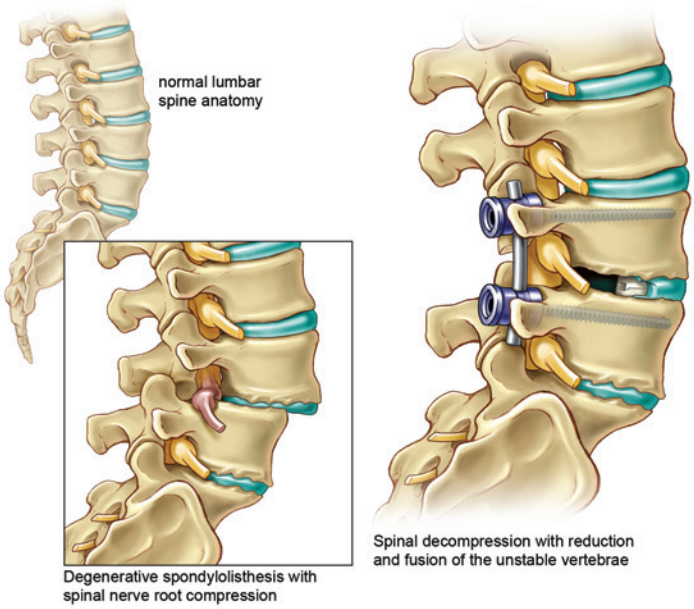

Indications and contraindications for surgery

Spondylolisthesis, anterior displacement or forward slippage of a lumbar vertebral body on the vertebra below it, often develops in the course of degenerative spinal disease. This "slippage" can lead to spinal stenosis and symptoms of low back pain, often with pain radiating into the lower extremities. Decompression of the spinal canal in these patients may create further instability and lead to progression of the spondylolisthesis and worsening pain. Therefore, we often perform lumbar fusion after decompression of the neural elements. A randomized study in patients with lumbar stenosis and associated spondylolisthesis demonstrated better outcomes with decompression and fusion compared with decompression alone. Another randomized study showed improved outcomes with fusion when compared to nonsurgical care. The primary goal of fusion in these cases is the prevention of further symptoms. Whether the alignment of the vertebrae needs to be restored, *i.e.*, "reduced", is debatable. Reduction has become technically easier to perform with modern instrumentation. Biomechanical studies in cadaveric spines suggest that restoration of alignment leads to decreased stress on adjacent vertebral levels. This theoretical advantage of reduction has not been well tested in clinical trials. Therefore, we usually limit the amount of reduction to that which can be achieved without placing the neural elements at undue risk of stretch or injury.

Discogenic low back pain without sciatica in patients with degenerative lumbar discs is a relatively controversial indication for lumbar fusion surgery. This diagnosis is often made on the basis of provocative discography, in which contrast material is injected into a degenerative disc the clinician suspects to be the "pain generator". A non suspect disc is also usually injected as a control. Patients are then asked to report if injection of the contrast reproduces the symptoms of their pain. Such patients are said to have a "concordant" discogram if injection of the suspect, but not the control disc, reproduces their pain. The positive predictive value of this test is difficult to assess because there is no clear "gold standard". While retrospective studies have shown that discography may be useful as predictor of good outcome following surgery, prospective trials have suggested the test lacks specificity. Two major studies provide somewhat contradictory evidence regarding the efficacy of lumbar fusion for discogenic pain. A randomized trial in Sweden compared fusion with nonsurgical treatments. Primary outcome measures of pain, depression, and return-to-work rates were all significantly improved in the surgical group compared to the non surgical group. A subsequent study in Norway compared fusion with a more-aggressive, nonoperative approach in which patients were sent to a formal "back school"; this study showed no difference in pain or function between groups. In addition, a number of studies have found that psychosocial factors are high outcome predictors and may confound the analysis of various treatment modalities for low back pain.

Identification of potential psychosocial confounders is an important part of patient selection for lumbar spinal fusion. Multiple studies have shown that major depressive disorder is a negative prognostic sign for improved functional outcomes regardless of treatment modality. Family and job stress, and other social factors, also play a role in the etiology of low back pain. Although a patient may have seemingly clear-cut indications to undergo lumbar fusion, patients with significant psychosocial stressors seem to be less likely to benefit from the surgery. A comprehensive psychosocial evaluation may be helpful to identify patients who may be better candidates for surgery. For this reason, we believe a multidisciplinary approach like that in place for the OHSU Spine Center, which involves physiatrists, psychologists, pain specialists and surgeons, is necessary to guide the management of patients with degenerative lumbar spinal disease.

New Faculty

Andrew N. Nemecek, M.D., joined the Department of Neurological Surgery in the OHSU School of Medicine Sept 1. Dr. Nemecek recently completed a combined orthopaedic surgery/neurosurgery spine fellowship at the University of Washington.

Dr. Nemecek specializes in spinal surgery and will be an integral member of Oregon's first state-of-the-art, multidisciplinary Spine Center in the OHSU Center for Health and Healing, which is under construction at Portland's new South Waterfront District and scheduled to open in fall 2006.

Dr. Nemecek will continue clinical research into cerebrospinal trauma and outcomes of degenerative spine disease.

The Mario and Edith Campagna Professorship in Pediatric Neurological Surgery

The OHSU School of Medicine announced Nov. 7, the establishment of the Mario and Edith Campagna Professorship in Pediatric Neurological Surgery — a new academic post that will benefit OHSU Doernbecher Children's Hospital. **Nathan Selden**, M.D., Ph.D., chief of the Division of Pediatric Neurological Surgery at Doernbecher, has been named OHSU's first Campagna Professor.

Selden has led Doernbecher's pediatric neurosurgery division since 2000. He also serves as residency program director and vice chairman for education in the OHSU Department of Neurological Surgery. Selden earned a medical degree at Harvard Medical School and a doctorate in neuroscience at Cambridge University. He is an accomplished researcher who has been honored by the American Academy of Neurological Surgery.

"Dr. Selden is one of this country's outstanding pediatric neuroscientists," said **Joseph Robertson**, M.D., M.B.A., dean of the OHSU School of Medicine. "It is fitting that an endowed professorship made possible by the family of one of Oregon's most accomplished neurosurgeons will be held by another standout in the field."

The professorship has been made possible through a generous $1 million gift from Mario Campagna, M.D., and his wife, Edith, of Medford, Ore. Campagna has been a leader in Oregon neurosurgery for more than 40 years, having founded the largest neurosurgical practice between Portland and San Francisco. He and his wife have long been recognized as civic leaders in the Rogue Valley and throughout the state.

"This professorship represents the first endowed position in pediatric neurosurgery in the state of Oregon," said Robertson. "We are grateful to the Campagnas for their exceptional commitment. This gift will advance patient care, research and education in pediatric neurosurgery into perpetuity." The professorship represents a "significant programmatic development" at the area's premier children's hospital, Robertson said.

Robertson was joined by OHSU President **Peter Kohler,** M.D., and other OHSU officials at an Oct. 17 ceremony acknowledging the Campagna family's gift and formally appointing Selden to his new position.

Reported by Michael MacRae

Dr. Selden is seated in the ceremonial Campagna Professorial Chair.
With him (L to R) are: Mr. Wakefield Mack, president, Doernbecher Foundation; Stacy Nicholson, M.D., chairman of pediatrics at OHSU Doernbecher Children's Hospital; Peter Kohler, M.D., OHSU president; Mrs. Edith Campagna; Mario Campagna, M.D.; Joseph Robertson, M.D., M.B.A., dean, OHSU School of Medicine; and Kim Burchiel, M.D., chairman of neurological surgery at OHSU.

You can help the Department of Neurological Surgery meet its mission

The Department of Neurological Surgery has a variety of programs that support research and resident/instructor education. Listed below are brief descriptions of the different activities supported by these funds:

- **Raaf Chair**: This endowed chair supports research in neurological surgery and neurosciences.
- **Paxton Fellowship**: This endowed professorship will support the development and implementation of the most advanced and innovative methods in neurological surgery education. This special professorship will be filled by an academic neurological surgeon with a national reputation for education, innovation and state-of-the-art approaches to neurosurgical teaching techniques.
- **Neurosurgical Educational Gifts**: These gifts provide support for numerous endeavours in keeping with the Department of Neurological Surgery's mission statement: emphasizing innovation and the dissemination of new knowledge; development of curricula and an environment that stimulates the spirit of inquiry; and research into the prevention and cure of neurological disease and disability.
- **Campagna Professorship**: This professorship provides support for a pediatric neurosurgical professorship and promotion of research in pediatric neurosurgery, and maintenance of the highest level of care for children with neurosurgical problems.

If you would like to make a tax-deductible contribution to any of these funds, please make your check payable to "OHSU-Dept. of Neurological Surgery" and submit it to **Sally Rodgers** at the address on the back of this issue, along with an indication of the fund(s) you wish to contribute to. You will receive a letter stating that you have made a tax-deductible donation as proof of your charitable giving.

Thank-you!

Device, which expands on own opens blocked artery

A stent device, known as the Wingspan Stent System with Gateway PTA Balloon Catheter, which expands on its own to open blocked arteries is being used at OHSU. **Stanley Barnwell**, M.D., Ph.D., associate professor of neurological surgery, OHSU School of Medicine and the Dotter Institute, and a member of the Oregon Stroke Center, is one of four interventional radiologists at OHSU trained to install the Wingspan stent.

OHSU is one of only 10 medical centers in the country trained to use the Wingspan device and is one of the first five to deploy it.

The procedure involves threading a catheter through an artery to the brain from a small incision in the hip. The catheter is inserted through the blockage, and a balloon is inflated with low pressure to slowly open the clog. The balloon and catheter are removed, and the Wingspan stent is deployed in the "pre-dilated" blockage using a second catheter. The stent has a self-expanding design, which allows it to keep the artery walls open even in curved areas of the vessel.

Until now, the only treatments available have been blood-thinning drugs such as Coumadin, Plavix and aspirin. But they failed to open intracranial atherosclerotic disease (ICAD) blockages in 30 percent of cases. A major NIH study recently found that as many as 22.5 percent of ICAD patients on medical therapy, such as blood-thinning drugs, will go on to have another stroke in the next year.

An estimated 60,000 patients each year suffer a stroke caused by ICAD, and the disease accounts for 8–10 percent of all ischemic strokes in the United States.

According to the American Stroke Association, about 700,000 people will suffer a stroke this year. It is the nation's No. 3 killer and a leading cause of severe, long-term disability.

Reported by Jonathan Modie

News & Events

Staff

Bryce Helgerson, M.H.A., department director has joined Legacy Health System as vice president of clinical operations and site administrator of the 115-bed Legacy Mount Hood Medical Center in Gresham, Ore. Neurological surgery wishes him well.

Sally Rodgers, M.H.A. will join neurological surgery as department director in February 2006. Rodgers comes to OHSU from University of Iowa, where she serves as department administrator for surgery. Please join us in welcoming Rodgers to OHSU and the department.

Nursing Conference

Debra Reeves, R.N., neurosurgery service coordinator and perioperative nurse in OHSU Hospital, has recently returned from a trip to Bejing. Reeves spoke at a perioperative break-out session and discussed the team model approach used for pituitary surgery with the intraoperative magnetic resonance imaging (intra-op MRI) process, currently in use at OHSU.

Neurological Surgery Visiting Lecture Series

March 19 — David McLone, M.D.
April 8 — Richard Fessler, M.D.
April 10 — John Loeser, M.D.
May 13 — Howard Riina, M.D.
June 10 — Robert Martuza, M.D.

Transforming Patient Care

In the interest of delivering more efficient, patient-centric care, OHSU has decided to move to an integrated suite of electronic health care delivery applications. These applications are products of a Madison, Wis.-based company called Epic, the national leader in this field. Some of the core applications that OHSU will be using are: Prelude (Registration), Cadence (Scheduling), Resolute (Professional Billing), EpicCare (Electronic Health Record), and Clarity (Reports). These applications will replace existing registration, scheduling, and billing systems in the ambulatory setting. Prelude, Cadence, and Resolute have already been implemented. EpicCare, the ambulatory electronic health record, is scheduled to be rolled out to neurological surgery in June 2006.

Research

Current Basic Science Awards

Mary Heinricher, Ph.D.
- Interleukin-1beta in Central Pain Modulating Circuits (NIH:NINDS)
- Medullary Circuitry in Opioid Analgesia (NIH:NIDA)
- Supraspinal prostaglandins and descending control (NIH:NINDS)

Nathan R. Selden, M.D., Ph.D
- Purinergic Control of Medullary Pain Modulation (NIH:NINDS)
- Cerebral Ventricular Resorbable Stent (OHSU BioScience Innovation Fund)

G. Alexander West, M.D., Ph.D.
- Adenosine Receptor and Ion Channels in Cerebral Vessels (NIH:NINDS)

Thomas Baumann, Ph.D.
- Modulation of Sensory Neuron Excitability by C-Peptide of Pro-Insulin (American Diabetes Association)
- Ion Channels in Spontaneously Active DRG Neurons from Patients with Intractable Pain (Medical Research Foundation of Oregon)

Kim J. Burchiel, M.D. and Jorge Eller, M.D.
- MRI Imaging of Intrathecal Catheters (Medtronic, Inc.)

Current Clinical Trials

Johnny B. Delashaw, M.D.
- A Prospective, Randomized, Controlled Clinical Trial of an Artificial Cervical Disc versus Anterior Cervical Fusion at a Single Level for Symptomatic Cervical Disc Disease (Medtronic Sofamor Danek)
- Phase III Randomized Evaluation of Convection Enhanced Delivery of IL13-PE38QQR Compared to Gliadel Wafer with Survival Endpoint in Glioblastoma Multiforme Patients at First Recurrence (NeoPharm, Inc.)
- A Prospective, Multi-Center, Randomized Controlled Study to Compare the Spinal Sealant System as an Adjunct to Sutured Dural Repair with Standard of Care Methods during Spinal Surgery (Confluent Surgical, Inc.)
- Duraseal Sealant Post Market Study (Confluent Surgical, Inc.)

Edmund Frank, M.D.
- Randomized, third-party blinded, multicenter clinical trial to determine the safety and effectiveness of Oxiplex/SP gel for the reduction of pain and symptoms following Lumbar Disc Surgery (FzioMed Inc.)

William H. Ludlum, M.D.
- A Multicenter, Open Label Study to Assess the Safety and Efficacy of 600 µg SOM230, Administered Subcutaneously, b.i.d. in patients with Cushing's disease (Novartis, Inc.)

For more information on clinical trials contact the neurological surgery clinical trials coordinator at 503 494-9546 or nsg@ohsu.edu.

Trigeminal Neuralgia Association Sixth National Conference

September 14-16, Portland, Ore.

Medical Management of Facial Pain
Brett R. Stacey, M.D.
OHSU

When Do I Refer to a Neurosurgeon?
Mark E. Linskey, M.D.
University of California-Irvine

An Evidence-based Approach to Facial Pain
Joanna Zakrzewska, MB BChir, M.D.
Barts and The London, Queen Mary's School of Medicine and Dentistry

The Dental Connection
David A. Sirois, D.M.D., Ph.D.
New York University College of Dentistry

How to Diagnose Facial Pain
Kim J. Burchiel, M.D.
OHSU

Microvascular Decompression
Nicholas M. Barbaro, M.D.
University of California San Francisco

Radiosurgery
John F. Alksane, M.D.
University of California-San Diego

Radiofrequency Rhizotomy
John M. Tew, Jr., M.D.
University of Cincinnati

Glycerol Rhizotomy
Richard S. Zimmerman, M.D.
Mayo Clinic

Balloon Compression
Jeffrey A. Brown, M.D.
Wayne State University

Neurostimulation
Louis Whitworth, M.D.
University of Texas SW Medical Center

www.tna-support.org

Neurotransmitter

Department of Neurological Surgery
Mail Code L-472
Oregon Health & Science University
3181 S.W. Sam Jackson Park Road
Portland, OR 97239–3098

OHSU is an equal opportunity, affirmative action institution.

Nonprofit Org.
U.S. Postage
PAID
Portland, OR
Permit No. 722

Upcoming Brain Awareness Events (February and March 2006)

please visit www.oregonbrains.org for more information

Lecture: **Creativity and the Brain**
Nancy Andreasen, M.D., Ph.D., University of Iowa
Dana author: *The Creating Brain: The Neuroscience of Genius*
Tuesday, February 7, 7:00 p.m.

Teacher Workshop: **The Brain in the Classroom: Attention and Learning**
Bruce McCandliss, Ph.D., Cornell University
Saturday, February 11, 9:00 a.m. - noon

Lecture: **The Power of Stem Cells and the Brain**
Fred Gage, Ph.D., Salk Institute
Visiting Jungers Lecturer
Tuesday, February 14, 7:00 p.m.

Lecture: **Nature and Nurture and the Developing Brain**
Helen Neville, Ph.D., University of Oregon
Judy Cameron, Ph.D., Oregon Health & Science University
Tuesday, February 21, 7:00 p.m.

Lecture: **Behavior and Addiction and the Brain**
Bob Hitzemann, Ph.D., Oregon Health & Science University
John Crabbe, Ph.D., Oregon Health & Science University
Tuesday, February 28, 7:00 p.m.

Lecture: **Healthy Aging and the Brain**
Guy McKhann, M.D., Johns Hopkins University
Marilyn Albert, Ph.D., Johns Hopkins University
Tuesday, March 7, 7:00 p.m.

OHSU Brain & Body Fair
Friday, March 10
Saturday, March 11
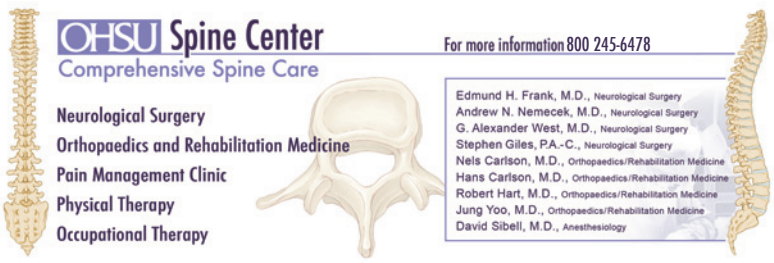
Marquam Hill Society Lecture:
Parkinson's Disease: Stem Cells, Gene Therapy, and Kitchen Table Wisdom
John 'Jay' Nutt, M.D., Oregon Health & Science University
Tuesday, March 14, 7:00 p.m.