

# A Quantitative Evaluation of Deformable Image Registration as a Surrogate for Target Definition for Adaptive Radiotherapy in Head and Neck Cancers

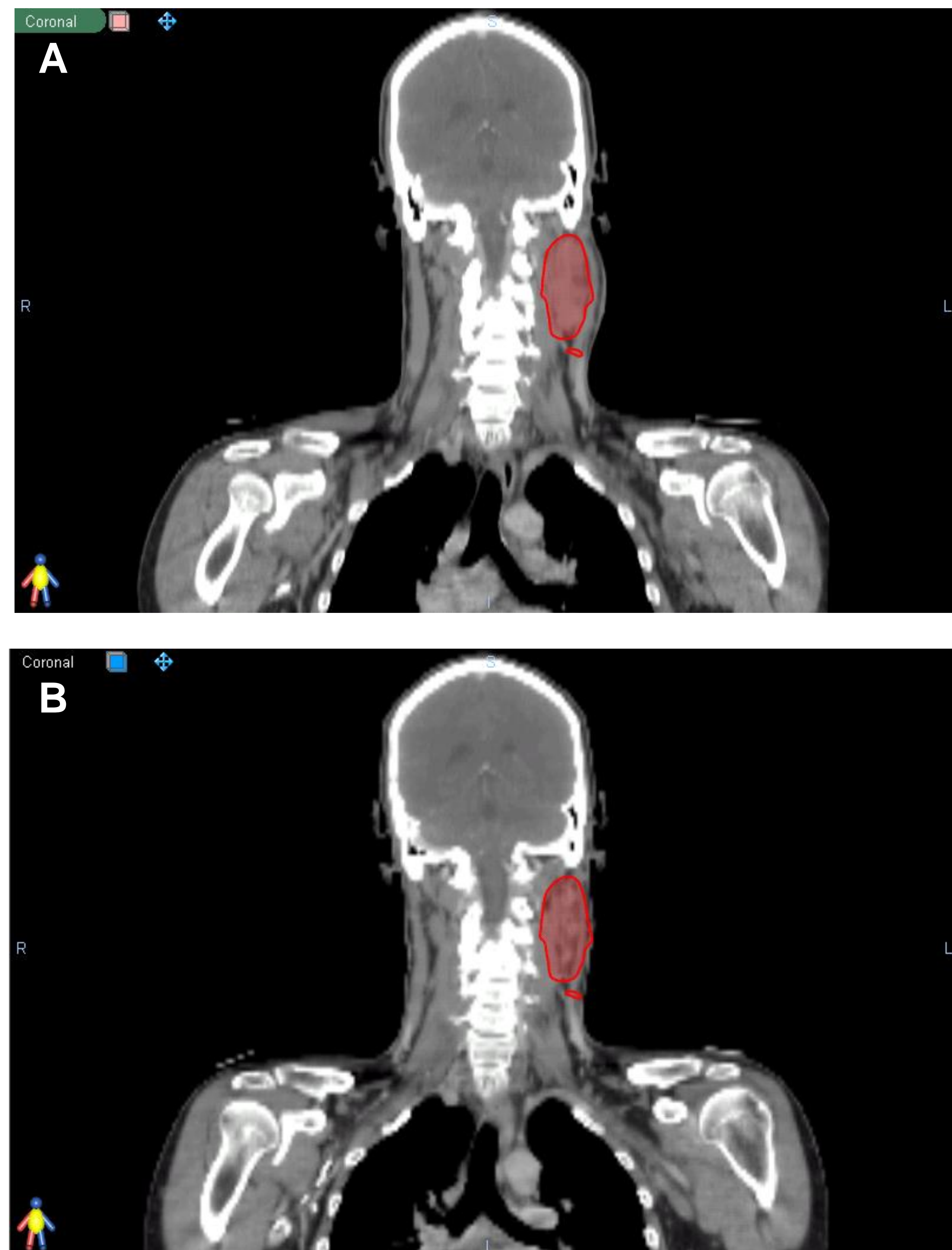
Shreya Sekaran<sup>2</sup>, William A. Gray<sup>1</sup>, James A. Tanyi<sup>2</sup>, John M. Holland<sup>2</sup>

Departments of <sup>1</sup>Oral & Maxillofacial Surgery and <sup>2</sup>Radiation Medicine  
Oregon Health & Science University, Portland, Oregon

## Purpose

To quantitatively evaluate the feasibility of a deformable image registration (DR) algorithm as a surrogate for manual target and organs-at-risk treatment planning contours for adaptive radiotherapy (ART), and to compare with rigid scale (RC) and rigid-only methods of structure propagation in head and neck cancer.

Figure 1: Structure propagation from the moving CT (A) to the fixed CT (B) based on rigid registration. Note the overlay of the structure on the skin in (B)



## Materials and Methods

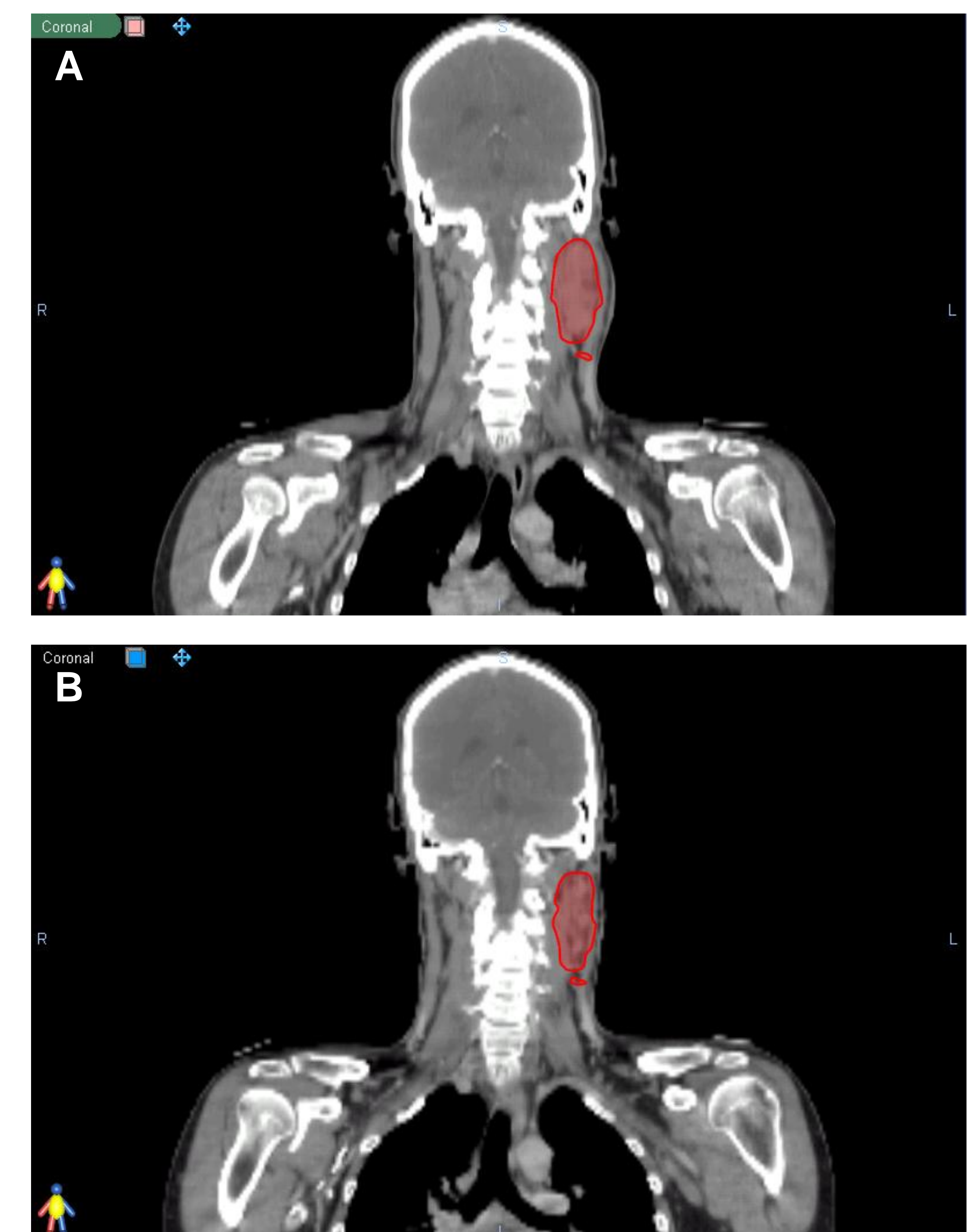
Two head and neck cancer patients underwent an initial planning CT and adaptive re-planning CT approximately 5 weeks into treatment due to tumor shrinkage and weight loss. The planning CT images (moving images) of these patients were registered to adaptive CT images (fixed images) via three image registration methodologies in the following sequential order: rigid-only; rigid plus scale (RC), and deformable image registration (DR). Region-of-interest (ROI) contours drawn on the planning CT were propagated onto their corresponding adaptive CT images. The Dice coefficient was used as a measure of similarity between the

registered contours and manually delineated contours.

## Results

For target volumes, up to 40% (mean Dice coefficient of 0.88) improvement in the agreement between DR contours and manual contours were observed over rigid-only and RC image registrations techniques. Similarly, up to 27% (mean Dice coefficient of 0.85) improvement in the agreement between DR contours and manual contours were observed for organs-at-risk.

Figure 2: Structure propagation from the moving CT (A) to the fixed CT (B) based on deformable registration. Unlike Figure 1B, deformable alignment matches anatomical changes through voxel tracking, allowing for the identification of location-dependent displacements.



## Conclusion

Deformable image registration provides better agreement with manually delineated contours than rigid-only or rigid plus scale image registration techniques.

The DR technique is a promising tool for automatic target delineation, and, hence, may be useful in adaptive radiation therapy, saving physician contouring time and allowing potential online ART.