

Purpose

- ❖ Interfraction motion of the prostate can lead to dosimetric inaccuracies and poor clinical outcomes during the course of prostate cancer radiation therapy.
- ❖ The purpose of this study was to investigate the changes in rectal and bladder dimensions in the absence of preparation instructions during daily fractionated prostate IMRT and to correlate the motion when interfraction prostate motion is corrected.

Methods

- ❖ Three patients were treated with radiation therapy for prostate adenocarcinoma over the course of 39 fractions. A simulation CT was performed (after an enema) prior to starting therapy. Daily cone-beam CT imaging (CBCT) and implanted gold seeds were used for localization. Prior to each treatment, daily CBCTs were co-registered with the planning CT for each patient using the location of the most inferior, apical, gold seed.
- ❖ Daily rectal and bladder volumes were contoured on each CBCT scan and compared to the original volumes and positions seen in the simulation CT. Daily changes in the anterior-posterior position of the rectal wall and daily changes in the rectal volume were measured. Daily changes in the bladder centroid and daily changes in the bladder volume were measured. All changes were analyzed for trends.
- ❖ The recorded daily positional variation based on daily pre-treatment alignment was correlated to the actual daily organ (prostate gland) shifts determined from the CBCTs.

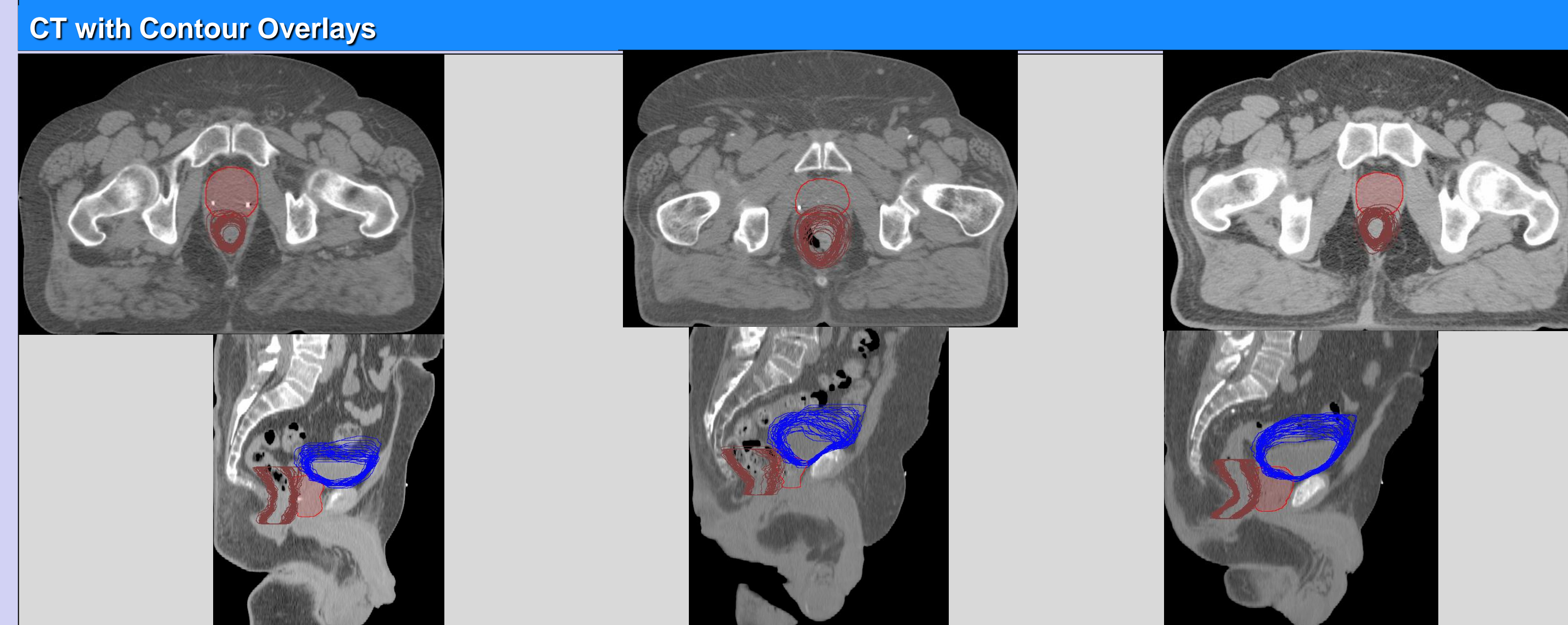
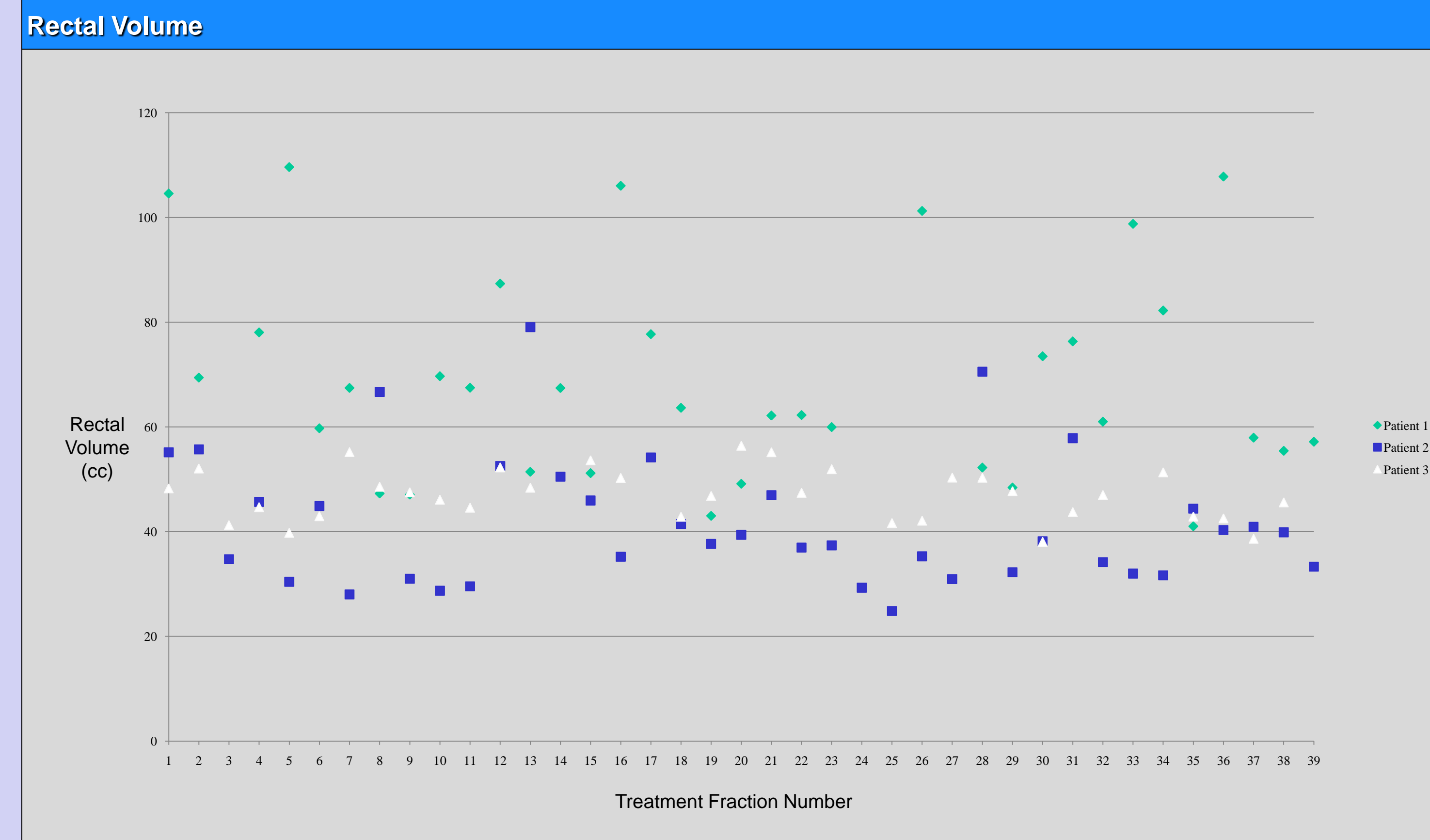


Figure 1: Sagittal and transverse CT views of a patient with prostate, bladder, and rectum contours overlaid. All 39 bladder and rectum contours have been overlaid on this image to depict the nature of the changes in position of each structure over the course of radiotherapy.



Results

- ❖ Daily measured rectal volume also varied widely; corresponding volumes were 33cc (38-56), 38cc (30-102), and 32cc (26-72). Observed bladder centroid displacement corresponded with bladder volume changes.
- ❖ Observed rectal wall position changes paralleled rectal volume changes; largest movements occurred superiorly in two cases and inferiorly in one case.
- ❖ At the superior CTV border, the rectal wall position differed from the planning CT for each patient by a median (range) of: -0.1 cm (-0.6–2.5), -0.1 cm (-2.4–1.3), 0.2 cm (-0.8–2.0).
- ❖ At the CTV isocenter, the median (range) differences were: -0.1 cm (-0.6–2.5), 0.4 cm (-0.3–0.9), -0.5 cm (-0.8–0.8).
- ❖ At the inferior CTV border, the median (range) differences were: -0.1 cm (-0.6–2.5), 0.8 cm (-0.1–1.5), 0.8 cm (0.1–2.1).
- ❖ Neither rectal wall movement nor bladder centroid displacement displayed any statistically significant trends over the course of treatment.
- ❖ While rectal filling appeared to correlate with daily positional corrections, no such trend was observed for bladder filling.

Conclusions

- ❖ The interfraction motion of the rectum and bladder in prostate cancer patients with unknown bladder and rectum “fullness” status was investigated.
- ❖ The results support the notion that the rectum and bladder have a significant interfraction motion despite correcting for interfraction prostate motion.
- ❖ Further investigations must be completed to assess appropriate techniques or specific patient instructions to avoid under treatment of the target and overtreatment of the surrounding structures.